

## LETTER - CLINICAL

### A novel *ATP2C1* mutation (c.1840-1G>A) in a sporadic case of isolated perianal Hailey-Hailey disease with human papillomavirus type 58 infection<sup>☆</sup>

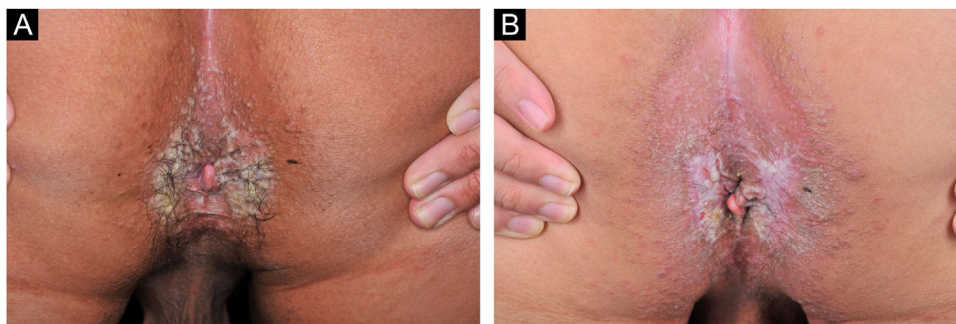


Dear Editor,

Hailey-Hailey Disease (HHD), or familial benign chronic pemphigus (OMIM:169600), is a rare autosomal-dominant blistering disease characterized by recurrent blisters, erosions, and macerated plaques mainly involving the intertriginous regions. It is caused by *ATP2C1* mutation, encoding secretory pathway  $\text{Ca}^{2+}/\text{Mn}^{2+}$ -ATPase 1 (SPCA1).<sup>1,2</sup> Updated on May 16, 2022, 264 public variants have been documented in *ATP2C1* LOVD database (<https://databases.lovd.nl/shared/genes/ATP2C1>). We report a sporadic case of isolated perianal Hailey-Hailey disease caused by a novel splicing mutation of *ATP2C1* with Human Papillomavirus (HPV) 58 infection.

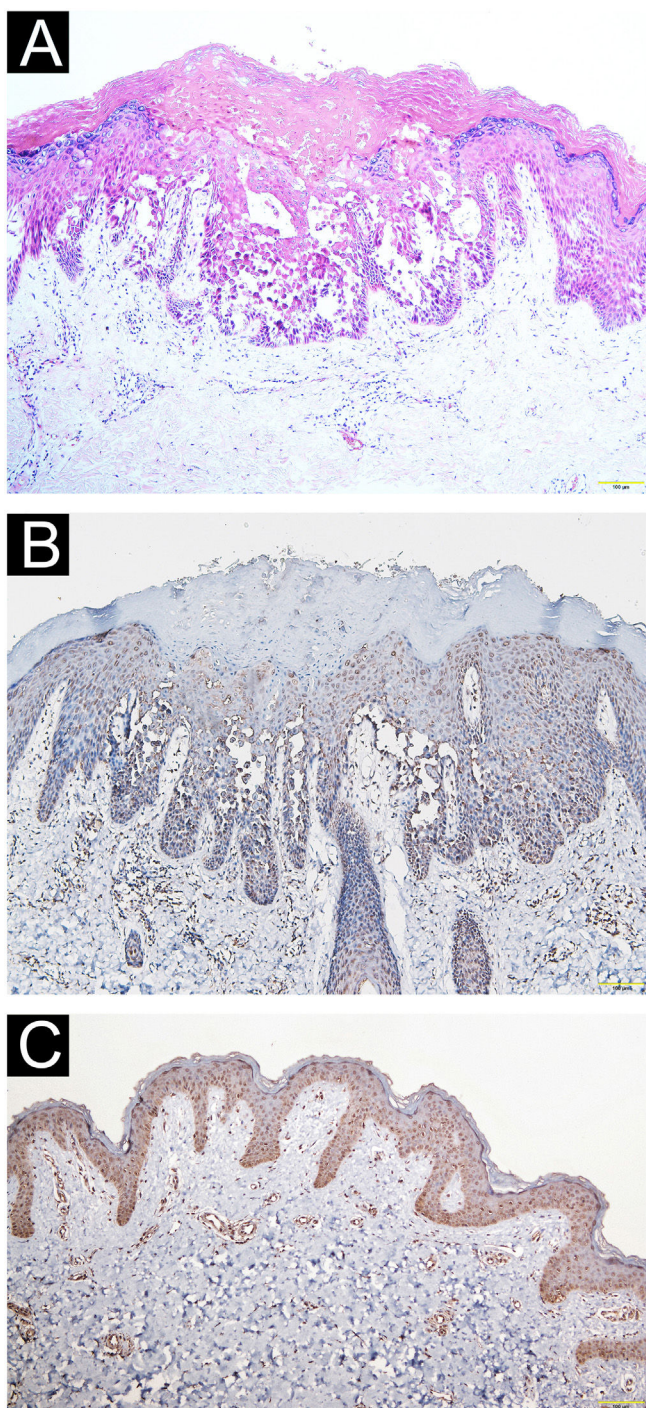
A 21-year-old Chinese man presented with a three-year history of perianal itching, erythema, and macerated papuloplaques (Fig. 1A) in September 2021. He had a ten-year history of chronic diarrhea, no family history of similar dermatosis, and no history of sexual activity. Serologies

for syphilis, HIV and herpes simplex virus were negative. Colonoscopy findings were unremarkable. Based on positive dot blot hybridization of HPV58 which was performed by using a smear from the lesion and a suspiciously positive acetic acid white test, he was tentatively diagnosed with genital warts and treated with electrofulguration and three sessions of 5-aminolevulinic acid Photodynamic Therapy (PDT). The lesions were alleviated but relapsed one month post-treatment and HPV reexamination (using smear from the lesion) was negative. Lesional biopsy showed epidermal hyperkeratosis; focal parakeratosis and dyskeratosis without koilocytosis; suprabasal acantholysis with “dilapidated brick-wall” appearance; and mild perivascular lymphohistiocytic infiltrate in the upper dermis (Fig. 2A). No comparable lesions were observed on other body regions. A final diagnosis of HHD with HPV58 infection was made. The lesions responded poorly to oral methylprednisolone, cyclosporine, methotrexate, topical corticosteroids, antibiotics, and tacrolimus for three months. Sanger sequencing of the patient’s peripheral blood revealed a novel heterozygous splicing mutation c.1840-1G>A (p.?) in intron 19 of *ATP2C1* (NM\_014382.4), and a wild-type sequence in his parents (Fig. 3). Immunohistochemical staining of SPCA1 polyclonal antibody (PA5-109430; Invitrogen, Carlsbad, CA, USA) revealed that epidermal expression was lower in the HHD lesion than in normal perianal skin of the other normal patient (Fig. 2B–C). The patient underwent ultra pulsed nonablative CO<sub>2</sub> laser therapy, achieving



**Figure 1** Clinical observation. (A) Perianal erythema and macerated papuloplaques. (B) Mild lesional improvement 6-months following CO<sub>2</sub> laser.

<sup>☆</sup> Study conducted at the Department of Dermatology, Affiliated Hospital of Guangdong Medical University, Zhanjiang, Guangdong, China.



**Figure 2** Pathological and immunohistochemical observation. (A) Epidermal hyperkeratosis, focal parakeratosis and dyskeratosis without koilocytosis, suprabasal acantholysis with “dilapidated brick-wall” appearance, and mild perivascular lymphohistiocytic infiltrate in the upper dermis (Hematoxylin & eosin,  $\times 100$ ). (B–C) Immunohistochemical staining revealing reduced epidermal hSPCA1 expression in the Hailey-Hailey disease lesion (B) compared with normal control skin (C) ( $\times 100$ ).

mild lesional improvement with markedly improved pruritus (Fig. 1B).

This patient harbored a novel heterozygous *ATP2C1* mutation c.1840-1G>A at the acceptor splice site of intron 19. Mutation Taster analysis predicted that this variant may be a pathogenic splicing mutation and cause SPCA1 dysfunction by affecting magnesium binding sites.<sup>1,3</sup> Consistent with a previous report,<sup>2</sup> SPCA1 immunoreactivity was reduced in the HHD lesion compared to control skin. *ATP2C1* mutations lead to defective calcium homeostasis and absent interkeratinocyte adhesion.<sup>4</sup>

Patients with HHD are susceptible to infections owing to skin barrier damage, but few reports exist of HHD concomitant with HPV6, 16 and 39 infections.<sup>4</sup> Since typical cauliflower-like papules and genital involvement were absent, and PDT resulted in negative HPV58 and koilocytosis, it is unclear whether the HPV58 positivity represented transient colonization or subclinical infection in this case. Nevertheless, HPV infection could complicate the course and prognosis of HHD.<sup>4</sup>

While there are no treatment guidelines for HHD, ablative surgery including dermabrasion, CO<sub>2</sub> and Er:YAG laser therapy, and argon plasma coagulation may be effective.<sup>5</sup> However, the clinical efficacy of nonablative CO<sub>2</sub> laser therapy and PDT was unsatisfactory in this case.

### Financial support

None declared.

### Authors' contributions

Yao Zhu: Final approval of the final version of the manuscript; drafting and editing of the manuscript.

Yi-Ming Fan: Final approval of the final version of the manuscript; writing of the manuscript or critical review of important intellectual content; the study concept and design.

Yan-Xia Cai: Final approval of the final version of the manuscript; effective participation in the research guidance; intellectual participation in the propaedeutic and/or therapeutic conduct of the studied cases.

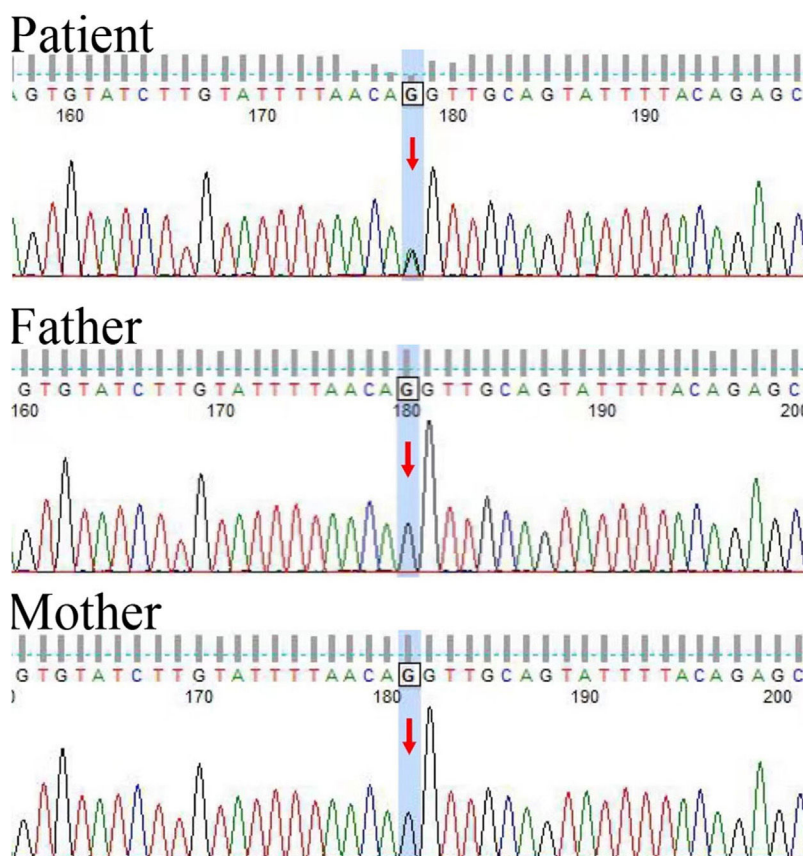
Yong-Hua Chen: Final approval of the final version of the manuscript; effective participation in the research guidance.

Fang Qiu: Final approval of the final version of the manuscript; critical review of the literature.

### Conflicts of interest

None declared.





**Figure 3** Genetic detection. Sanger sequencing of peripheral blood revealing a novel heterozygous splicing mutation c.1840-1G>A in intron 19 of *ATP2C1* in the patient, and a wild-type sequence in his parents.

## References

1. Yang L, Zhang Q, Zhang S, Liu Y, Liu Y, Wang T. Generalized Hailey-Hailey disease: novel splice-site mutations of *ATP2C1* gene in Chinese population and a literature review. *Mol Genet Genomic Med.* 2021;9:e1580.
2. Li X, Zhang D, Ding J, Li L, Wang Z. Identification of *ATP2C1* mutations in the patients of Hailey-Hailey disease. *BMC Med Genet.* 2020;21:120.
3. Deng H, Xiao H. The role of the *ATP2C1* gene in Hailey-Hailey disease. *Cell Mol Life Sci.* 2017;74:3687–96.
4. Li F, Zhang Y, Li Q, Li H, Zhu X, Wang M. Condylomata acuminata in a case of Hailey-Hailey disease with a novel mutation. *J Dtsch Dermatol Ges.* 2021;19:454–5.
5. Rogner DF, Lammer J, Zink A, Hamm H. Darier and Hailey-Hailey disease: update 2021. *J Dtsch Dermatol Ges.* 2021;19:1478–501.

Yao Zhu , Yi-Ming Fan , Yan-Xia Cai \*, Yong-Hua Chen , Fang Qiu

*Department of Dermatology, Affiliated Hospital of Guangdong Medical University, Zhanjiang, Guangdong, China*

\* Corresponding author.

E-mail: 15816098248@163.com (Y. Cai).

Received 8 November 2022; accepted 16 December 2022

<https://doi.org/10.1016/j.abd.2022.12.011>

0365-0596/ © 2024 Published by Elsevier España, S.L.U. on behalf of Sociedade Brasileira de Dermatologia. This is an open access article under the CC BY license (<http://creativecommons.org/licenses/by/4.0/>).

## Amelanotic melanoma with neural lesion simulating leprosy\*

Dear Editor,

Amelanotic/hypomelanotic melanoma (AHM) is a subtype of cutaneous melanoma with little or no pigment on macro-



scopic inspection and dermoscopic evaluation, or absence of melanin on histopathology. It is a rare entity, with variable frequency, between 0.4% and 27.9%, but possibly underestimated.<sup>1</sup>

The absence of pigmentation and clinical criteria for suspected melanoma, and the morphological variability of AHM possibly lead to erroneous and late diagnosis.<sup>1,2</sup> AHM can mimic a variety of benign and malignant diseases of different etiologies, whether inflammatory or infectious, in addition to neoplasias.<sup>1,2</sup>

An 81-year-old woman was referred with suspected leprosy due to loss of strength and dropping of her left hand two months before and asymptomatic lesions on her left

\* Study conducted at the Division of Dermatology, Hospital das Clínicas, Faculty of Medicine, Universidade de São Paulo, Ribeirão Preto, SP, Brazil.