

## LETTER - THERAPY

### Erythrodermic psoriasis treatment with Guselkumab: report of two cases and literature review<sup>☆</sup>



Dear Editor,

Erythrodermic psoriasis (EP) is an uncommon and possibly fatal psoriasis presentation involving more than 80% of the body surface area (BSA).<sup>1</sup> Controlled clinical trials and current treatment choices for EP are limited and, compared to plaque-type psoriasis, EP patients seem to have a worse clinical response to standard therapies.<sup>1</sup> Guselkumab is a human monoclonal antibody against Interleukin-23 (IL-23), that joins the p19 subunit of IL-23 and has exhibited excellent and sustained treatment effects in moderate-to-severe plaque-type psoriasis.<sup>1</sup> However, reports of guselkumab efficacy in EP are scarce. This study aims to report two cases of EP treated with guselkumab with sustained efficacy and perform a literature review of guselkumab in the treatment of EP.

We present a 65-year-old woman with a 4-year history of psoriasis previously treated with topical steroids. Her disease flared involving >90% of her BSA. Skin examination demonstrated symmetrical erythematous scaly plaques (Fig. 1A). A punch biopsy was compatible with psoriasis. Guselkumab (100 mg via subcutaneous injection at week

0 and week 4, followed by a dose every 8 weeks), topical steroids, and emollients were started. The patient achieved a complete response (PASI100) by week 12 (Fig. 1B) and has maintained it for over 32 months. The second case is a 51-year-old man with a 1-year history of plaque-type psoriasis treated with topical steroids. He presented with erythematous plaques on his extremities and trunk that spread to a PASI 40. Histopathological analysis was compatible with psoriasis. Treatment with guselkumab as mentioned previously resulted in complete resolution by week 12 which has persisted for 2-years.

We performed a literature review of EP treated with guselkumab on August 15, 2022, through MEDLINE (PubMed) with keywords erythroderm\* AND guselkumab. Of the 10 results, we excluded 3 as they were about other conditions (non-erythrodermic psoriasis, pustulotic arthroosteitis, palmoplantar pustulosis, palmoplantar psoriasis, psoriatic arthritis, erythrodermic ichthyosis) and 3 that were reviews.

We included 4 articles with 26 patients combined with EP in treatment with guselkumab. Most patients were men (n = 24), and the mean age was 49.9 years.<sup>1-4</sup> All patients showed a good response during treatment, except one with concomitant Castleman's disease and one that withdrew consent from the study.<sup>1-4</sup> Sano et al.<sup>3</sup> reported 10 (90.9%) patients with "treatment success" at week 16. Ten (90.9%) patients reported a mean PASI of 3.9 (SD = 4.27) with a median improvement of 94.1% by week 52. Chiang et al.<sup>1</sup>

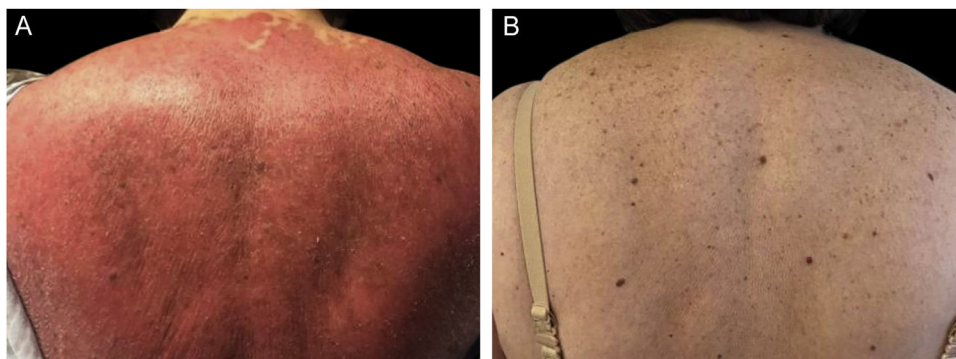


Figure 1 (A) Erythrodermic psoriasis; (B) Remission after guselkumab therapy.

<sup>☆</sup> Study conducted at Welsh Dermatology & Associates, Monterrey, NL, Mexico.

reported 13 patients in follow-up for 28 weeks, where 8 (61.5%) reached PASI 50 response by week 12. Megna et al.<sup>2</sup> reported one patient with PASI 100 at 20 weeks and sustained effect by week 48. Zanelli et al.<sup>4</sup> reported a patient with multicentric Castleman's disease and EP that did not respond to guselkumab therapy.

The two patients reported herein had a PASI 100 response by week 12 with sustained effect at the last follow-up at 24 and 32 months and no adverse events. IL-23 inhibitors have shown higher PASI90 and PASI100 response rates compared to anti-TNF alpha inhibitors in moderate and severe psoriasis with a similar adverse event profile.<sup>5</sup> Our review found few cases and case series of EP treated with guselkumab but a high response rate. Reported adverse events were infrequent and mild. Several factors influence treatment decisions, including infections (e.g., tuberculosis or hepatitis B/C), affordability, comorbidities, and accessibility. Our study suggests that guselkumab is an efficient treatment for EP, given the results, safety, and long-term effectiveness it has shown. Comparative studies, that include other biologics like risankizumab and tildrakizumab, are needed to define the best treatment for patients with EP.

### Financial support

None declared.

### Authors' contributions

Esperanza Welsh: Collected the clinical data and reviewed the draft of the manuscript. Approval of the final version of the manuscript.

Jesus Alberto Cardenas-de la Garza: Collected the clinical data, adapted the clinical image, and wrote a draft of the manuscript. Approval of the final version of the manuscript.

José Alberto García-Lozano: Collected the clinical data and obtained the figure. Approval of the final version of the manuscript.

Diana Paola Flores-Gutierrez: Collected the clinical data and wrote a draft of the manuscript. Approval of the final version of the manuscript.

### Conflicts of interest

Esperanza Welsh has been a consultant and/or speaker for Merz, Leo Pharma, and Janssen.

Jesus Alberto Cardenas-de la Garza has been a consultant for Leo Pharma.

José Alberto García-Lozano and Diana Paola Flores-Gutierrez have nothing to disclose.


### Acknowledgments

No acknowledgments.


### References

- Chiang CY, Tsai TF. Treatment response of patients with erythrodermic psoriasis after switching to Guselkumab. *Dermatol Ther (Heidelb)*. 2021;11:301–6.
- Megna M, Ruggiero A, Camela E, Fabbrocini G, Marasca C. A case of erythrodermic psoriasis successfully treated with guselkumab. *Dermatol Ther*. 2020;33:e13238.
- Sano S, Kubo H, Morishima H, Goto R, Zheng R, Nakagawa H. Guselkumab, a human interleukin-23 monoclonal antibody in Japanese patients with generalized pustular psoriasis and erythrodermic psoriasis: efficacy and safety analyses of a 52-week, phase 3, multicenter, open-label study. *J Dermatol*. 2018;45:529–39.
- Zanelli M, Stingeni L, Zizzo M, Martino G, Sanguedolce F, Marra A, et al. HHV8-Positive castleman disease and in situ mantle cell neoplasia within dermatopathic lymphadenitis, in longstanding psoriasis. *Diagnostics (Basel)*. 2021;11:1150.
- Ataseven A, Temiz SA, Eren G, Özer İ, Dursun R. Comparison of anti-TNF and IL-inhibitors treatments in patients with psoriasis in terms of response to routine laboratory parameter dynamics. *J Dermatolog Treat*. 2022;33:1091–6.

Esperanza Welsh  <sup>a</sup>,

Jesus Alberto Cardenas-de la Garza  <sup>b,\*</sup>,

José Alberto García-Lozano  <sup>c</sup>,

Diana Paola Flores-Gutierrez  <sup>b</sup>

<sup>a</sup> *Welsh Dermatology and Associates, Monterrey Nuevo Leon, Mexico*

<sup>b</sup> *Rheumatology Department, Universidad Autónoma de Nuevo León, Hospital Universitario 'Dr José Eleuterio González', Monterrey NL, México*

<sup>c</sup> *Department of Clinical Introduction, Faculty of Medicine and University Hospital 'Dr. José E. González', Autonomous University of Nuevo León, Monterrey, Nuevo León, Mexico*

\* Corresponding author.

E-mail: [cardenasdelagarza@gmail.com](mailto:cardenasdelagarza@gmail.com)

(J.A. Cardenas-de la Garza).

Received 23 February 2023; accepted 20 May 2023

Available online 7 December 2023

<https://doi.org/10.1016/j.abd.2023.05.007>

0365-0596/ © 2023 Sociedade Brasileira de Dermatologia.

Published by Elsevier España, S.L.U. This is an open access article under the CC BY license

(<http://creativecommons.org/licenses/by/4.0/>).