

5. Tokura Y. New Etiology of Cholinergic Urticaria. *Curr Probl Dermatol.* 2016;51:94–100.

Máisa Aparecida Matico Utsumi Okada  ^{a,*},
Leticia Santos Dexheimer  ^a, Renan Rangel
Bonamigo  ^{a,b},
Renata Heck  ^a

^a Ambulatory of Sanitary Dermatology, Secretaria Estadual de Saúde do Rio Grande do Sul, Porto Alegre, RS, Brazil

^b Faculdade de Medicina, Universidade Federal do Rio Grande do Sul, Porto Alegre, RS, Brazil

* Corresponding author.

E-mail: okada.maisa@gmail.com (M.A. Okada).

Received 11 August 2020; accepted 15 October 2020

Available online 1 June 2022

<https://doi.org/10.1016/j.abd.2020.10.025>

0365-0596/ © 2022 Sociedade Brasileira de Dermatologia.

Published by Elsevier España, S.L.U. This is an open access article under the CC BY license (<http://creativecommons.org/licenses/by/4.0/>).

Ecthyma gangrenosum in neutropenic patients and the importance of an early skin biopsy for direct examination[☆]



Dear Editor,

Ecthyma Gangrenosum (EG) was once considered pathognomonic for sepsis caused by *Pseudomonas aeruginosa*.¹ However, other agents have been described in oncohaematological patients.² Skin biopsies are often not performed, and treatment is usually empirical. This report describes three cases of neutropenic patients with EG who underwent skin biopsy with direct examination.

Patient 1: Male, 36 years old, with acute lymphoblastic leukemia, presented with febrile neutropenia (FN) during chemotherapy, and treatment with cefepime was started. After ten days, he once again had a fever, with the appearance of erythematous lesions with a necrotic center on the face and chest. He had neutropenia (10/mm³) and thrombocytopenia (24,000/mm³). Blood cultures and a skin biopsy were collected, and liposomal amphotericin B and voriconazole were started. Direct examination identified septate hyaline hyphae (Fig. 1), which were later also detected in the histopathological examination. *Fusarium spp.* was identified in blood and skin cultures. The patient did not survive depicting of the treatment.

Patient 2: Male, 47 years old, had FN during chemotherapy for acute myeloid leukemia, and treatment with cefepime was started. After fourteen days, he once again had a fever, with the appearance of a single erythematous lesion with a necrotic center, on the chest (Fig. 2). He had neutropenia (40/mm³) and thrombocytopenia (44,000/mm³). Blood cultures and a skin biopsy were collected. Direct examination revealed non-septate hyaline hyphae (Fig. 3), which were later seen in the histopathological examination. Antifungal treatment with liposomal amphotericin B was started. Subsequently, *Syncephalastrum spp.* was identified in the skin culture. The patient remained afebrile, with neutrophilic recovery.

Patient 3: Male, 36 years old, had FN during chemotherapy for acute myeloid leukemia, and treatment with

cefepime was started. After four days, he had a fever, and arterial hypotension, with the appearance of an erythematous lesion with a necrotic center on the back region. Antibiotic therapy was expanded to include polymyxin B, amikacin, and meropenem. He had neutropenia (170/mm³) and thrombocytopenia (2,000/mm³). A skin biopsy was collected, and a direct examination identified the presence of gram-negative rods. No specimen was sent for histopathological examination. Subsequently, multidrug-resistant *Pseudomonas aeruginosa* was identified in the skin and blood cultures. The antimicrobial regimen was maintained until a clinical resolution was attained.

The present report describes three cases of neutropenic patients who developed EG. All had a similar clinical presentation, with fever recurrence and the appearance of lesions during antibiotic therapy. In the first patient, direct

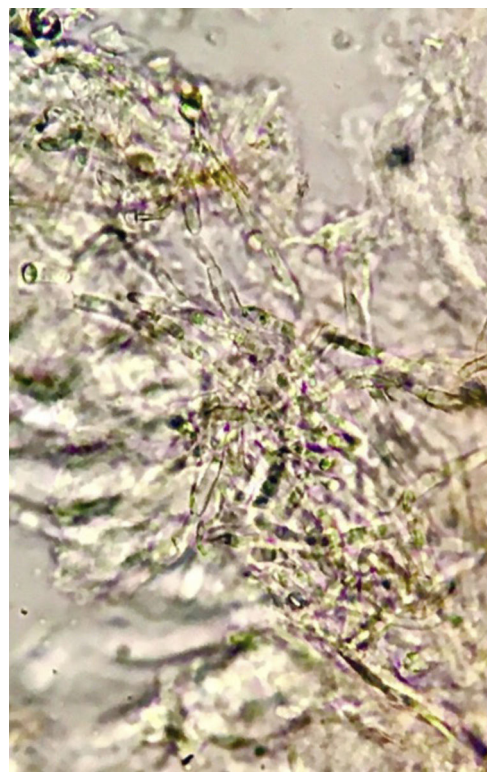


Figure 1 Septate hyaline hyphae with branching at an acute angle. Direct examination, KOH 20%, ×40.

[☆] Study conducted at the Instituto Nacional de Câncer, Rio de Janeiro, RJ, Brazil.

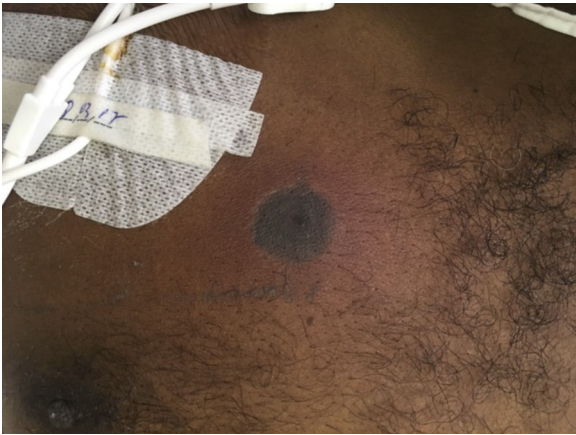

Figure 2 Single erythematous lesion with necrotic center in the anterior thoracic region, close to the Hickman catheter.

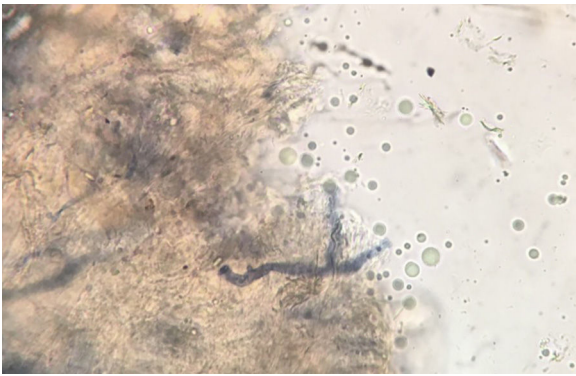


Figure 3 Thick, non-septate hyaline hyphae, branching at a right angle. Direct examination. KOH 20% and Parker's ink.

examination suggested the diagnosis of fusariosis, directing the combined antifungal treatment. The cause of death was attributed to the absence of immune reconstitution. In the second patient, the direct examination suggested the diagnosis of mucormycosis, directing the change of the antifungal agent for liposomal amphotericin B. In the third patient, the direct examination suggested the diagnosis of bacterial sepsis, directing the expansion of the antibiotic regimen without the association of antifungal agents.

Typically, the EG agent is identified in blood and skin cultures. However, as these results are not promptly available, the treatment is usually the empirical expansion of the anti-infective regimen. The disadvantages of this approach are exposure to toxic drugs and increased costs. The skin biopsy is a safe procedure in thrombocytopenic patients.³ Direct examination helped to identify the agent before the results of cultures were obtained, which later confirmed what had already been detected. In summary, we suggest performing an early skin biopsy with direct examination in neutropenic patients with EG.

Financial support

None declared.

Authors' contributions

Yung Gonzaga: Approval of the final version of the manuscript; critical review of the literature; collection, analysis, and interpretation of data; effective participation in research orientation; intellectual participation in the propaedeutic and/or therapeutic conduct of the studied cases; critical review of the manuscript; drafting and editing of the manuscript; statistical analysis; design and planning of the study.

Thiago Jeunon: Approval of the final version of the manuscript; critical review of the literature; collection, analysis, and interpretation of data; effective participation in research orientation; intellectual participation in the propaedeutic and/or therapeutic conduct of the studied cases; critical review of the manuscript; drafting and editing of the manuscript; statistical analysis; design and planning of the study.

Jorge Machado: Approval of the final version of the manuscript; critical review of the literature; collection, analysis, and interpretation of data; effective participation in research orientation; intellectual participation in the propaedeutic and/or therapeutic conduct of the studied cases; critical review of the manuscript; drafting and editing of the manuscript; statistical analysis; design and planning of the study.

Marcio Nucci: Approval of the final version of the manuscript; critical review of the literature; collection, analysis, and interpretation of data; effective participation in research orientation; intellectual participation in the propaedeutic and/or therapeutic conduct of the studied cases; critical review of the manuscript; drafting and editing of the manuscript; statistical analysis; design and planning of the study.

Conflicts of interest

None declared.

References

1. Pickarrd R, Llamas R. Ecthyma gangrenosum complicating *Pseudomonas* bacteremia. Rare survival. *J Fla Med Assoc.* 1970;57:34-5.
2. Vaiman M, Lazarovitch T, Heller L, Lotan G. Ecthyma gangrenosum and ecthyma-like lesions: review article. *Eur J Clin Microbiol Infect Dis.* 2015;34:633-9.
3. Xia FD, Khosravi H, Waul MA, Butler D, Joyce C, Mostaghimi A. Low risk of hemorrhagic complications after obtaining diagnostic skin biopsy specimens in a cohort of thrombocytopenic inpatients. *J Am Acad Dermatol.* 2017;76:1004-5.

Yung Gonzaga ^{a,*}, Thiago Jeunon ^b,
Jorge Machado ^a, Marcio Nucci ^c

^a Instituto Nacional de Câncer, Rio de Janeiro, RJ, Brazil

^b Private clinic, Rio de Janeiro, RJ, Brazil

^c Universidade Federal do Rio de Janeiro, Rio de Janeiro, RJ, Brazil

* Corresponding author.

E-mail: yungbmg@hotmail.com (Y. Gonzaga).

Received 14 July 2020; accepted 11 November 2020

Available online 30 May 2022

<https://doi.org/10.1016/j.abd.2020.11.018>

0365-0596/ © 2022 Sociedade Brasileira de Dermatologia.

Published by Elsevier España, S.L.U. This is an open access article under the CC BY license (<http://creativecommons.org/licenses/by/4.0/>).

Exophytic botryomycosis: An unusual clinical presentation[☆]



Dear Editor,

Botryomycosis is a chronic infectious disease of bacterial origin, granulomatous and suppurative with a worldwide distribution. The incidence and prevalence are unknown, although it is considered an infrequent entity, with approximately 200 cases reported around the world.¹⁻³

A 42-year-old male patient, a farmer, arrives at the dermatology service with a slow-growing lesion that had appeared 2-years earlier in the great toe finger of the right foot. The patient reported pain of moderate intensity that was enhanced with daily walking, as well as self-limited bleeding. Physical exam reveals in the dorsal aspect of the great toe finger an exophytic ulcerated tumor, erythematous, with hematic crust on the surface and some areas of bleeding, measuring 5×5 centimeters (Fig. 1).

A biopsy was taken for the clinical hypothesis of squamous cell carcinoma vs. amelanotic melanoma; the result of the histopathological study showed pseudoepitheliomatous hyperplasia with basophilic granular bodies (grains) with numerous neutrophils (Figs. 2 and 3). Microbiological cultures were negative. The diagnosis of the exophytic botryomycosis was made, surgical resection was indicated by the plastic surgery service, and antibiotic management with trimethoprim-sulfamethoxazole was started.

Botryomycosis derives from the Greek “botrys” (bunch of grapes) and “myces” (fungus) because initially, a fungal etiology was suspected. Two types of the presentation can be described, cutaneous and visceral.^{1,4}

The cutaneous presentation represents 75% of the reported cases, the remaining 25% correspond to the visceral type. Botryomycosis can occur at any age, although it rarely occurs in ‘children’s and adults over 70-years old, it mainly involves areas with greater susceptibility to trauma such as hands, feet, head and neck.^{1,3,4}

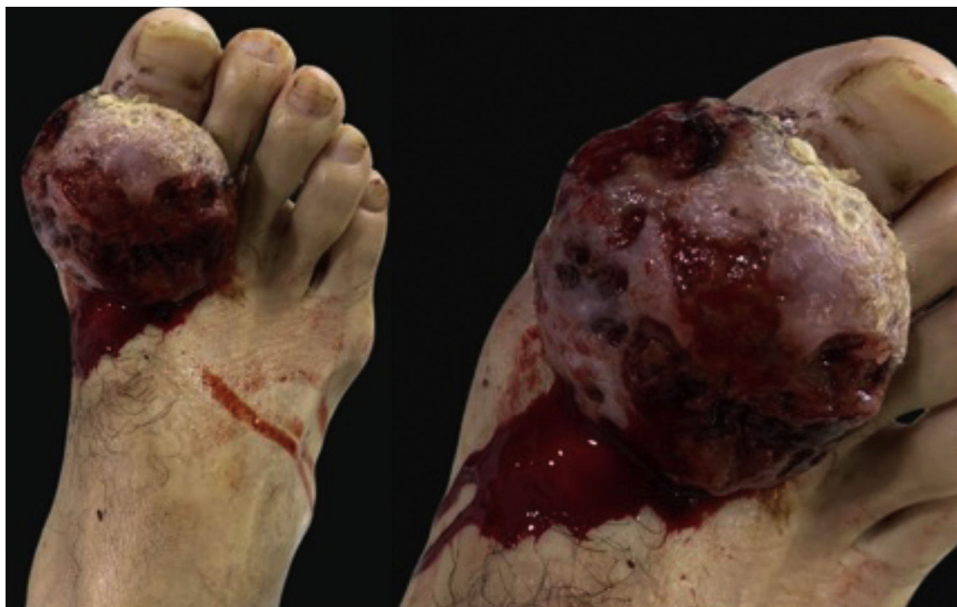

Figure 1 On the right great toe finger exophytic, ulcerated tumor.

[☆] Study conducted at the Hospital Universitario La Samaritana, Bogotá, Colombia.