

matrix metalloproteinase-9 and -12 derived from tumor cells, fibroblasts, and macrophages may be relevant to the partial elimination of the tumor, by degradation of collagen and elastic fibers.⁴ When superficially located, the elimination of pilomatricoma is accelerated by virtue of epidermal catharsis mechanisms.

Financial support

None declared.

Authors' contributions

Mai Endo: Designed the study; performed the research and contributed to analysis and interpretation of data; wrote the initial draft of the manuscript; read and approved the final version of the manuscript.



Toshiyuki Yamamoto: Designed the study; performed the research and contributed to analysis and interpretation of data; assisted in the preparation of the manuscript; read and approved the final version of the manuscript.

Conflicts of interest

None declared.

References

1. Miura T, Yamamoto T. Perforating pilomatricoma with anetodermic epidermis in an adolescent with lymphoma. *Pediatr Dermatol.* 2013;30:68–9.
2. Alli N, Güngör E, Artüz F. Perforating pilomatricoma. *J Am Acad Dermatol.* 1996;35:116–8.
3. Bayle P, Bazex J, Lamant L, Lauque D, Durieu C, Albes B. Multiple perforating and non-perforating pilomatricomas in a patient with Churg-Strauss syndrome and Rubinstein-Taybi syndrome. *J Eur Acad Dermatol Venereol.* 2004;18:607–10.
4. Richet C, Maza A, Dreyfus I, Bourrat E, Mazereeuw-Hautier J. Childhood pilomatricomas: Associated anomalies. *Pediatr Dermatol.* 2018;35:548–51.
5. Watabe D, Mori S, Akasaka T, Motegi SI, Ishiwaka O, Amano. Six cases of perforating pilomatricoma: Anetodermic changes with expression of matrix metalloproteinases. *J Dermatol.* 2020;47:82–5.

Mai Endo *, Toshiyuki Yamamoto 

Department of Dermatology, Fukushima Medical University, Fukushima, Japan

*Corresponding author.

E-mail: enmai04@fmu.ac.jp (M. Endo).

Received 7 July 2020; accepted 21 September 2020
available online 10 February 2022

<https://doi.org/10.1016/j.abd.2020.09.015>

0365-0596/ © 2021 Sociedade Brasileira de Dermatologia.

Published by Elsevier España, S.L.U. This is an open access article under the CC BY license (<http://creativecommons.org/licenses/by/4.0/>).

Acyclovir-resistant chronic mucocutaneous herpes with good response to the association with imiquimod in an AIDS patient: case report*



Dear Editor,

Genital ulcers are often caused by herpes simplex virus (HSV), with type 2 being most frequently implicated.¹ When immunodeficiency is present, the herpetic infection can progress with atypical presentations and greater refractoriness to antiviral treatment.²

In patients who are co-infected with human immunodeficiency virus (HIV), deeper ulcerations, hypertrophic lesions, and, in some cases, lesions with pseudotumor characteristics may be seen.¹

This case report describes a patient with acquired immunodeficiency with anogenital lesions, initially resistant to treatment with systemic acyclovir, who showed significant improvement after its association with the topical use of 5% imiquimod cream.

A case of a 38-year-old female patient with acquired human immunodeficiency syndrome (AIDS) diagnosed approximately five years ago, but who showed loss of adherence to antiretroviral treatment (ART) for a few months during 2017, restarting treatment in December of that same year is presented. Among the laboratory alterations, she had a CD4 T-cell count of 4 cells/ μ L. She reported the presence of ulcerated anogenital lesions for approximately one year. She had been medicated at another service with oral acyclovir for four months, without any improvement.

At the time of the examination, she had extensive, intensely painful, ulcerated lesions with crusts in the vulva and perianal region (Fig. 1a). Intravenous acyclovir was the drug of choice, at a dose of 10 mg/kg/dose 3 times a day, associated with 5% imiquimod cream (3 times/week), with excellent tolerability. She showed a good therapeutic response three weeks after beginning the proposed treatment (Fig. 1b), but it could not be concluded as the patient died due to complications from the underlying disease. The histopathological examination was carried out at the beginning of the clinical picture in order to document the case, showing the typical findings of HSV infection (Fig. 2).

It is believed that unusual clinical presentations due to HSV infections in AIDS patients could be explained as a reflection of the slow evolution of the disease and not nec-

* Study conducted at the Hospital Federal Bonsucesso, Rio de Janeiro, RJ, Brazil.

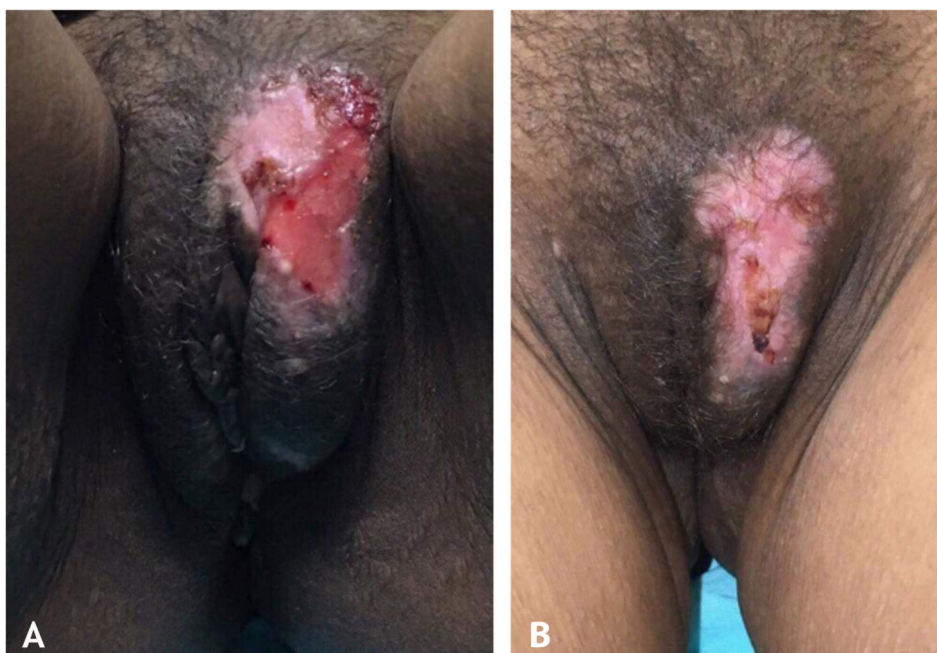

Figure 1 (A), Extensive ulcer with crusts in the vulva. (B), Cicatricial aspect of the lesion after association with 5% imiquimod cream.

essarily due to the specific characteristics of the involved strains.

Imiquimod is an immunomodulator with a formal indication for the topical treatment of conditions such as external anogenital warts, superficial basal cell carcinoma, and actinic keratoses.³ Its action is due to its antiviral and antitumor effects.⁴ Although not considered a formal indication of this medication, the antiproliferative action of imiquimod has shown significant importance in the adjuvant treatment of genital ulcers caused by HSV, particularly those refractory to conventional treatment, such as in our patient, who had already been treated with long-term oral acyclovir.

There is a report in the literature, as early as 2002, indicating the successful use of topical imiquimod for the treatment of genital ulcers in an HIV-positive patient.⁵ More recently, two other cases have been reported, both presenting clinical resistance to conventional antiviral treatment, which had excellent results with the association of topical imiquimod.⁶ There are descriptions in the literature of significant improvement of the lesions after the sixth day of use of the association of imiquimod with the traditional treatment.⁷

Foscarnet sodium, in cases of ulcers that are resistant to acyclovir, has been the drug of choice for the associated treatment. However, it is known that there are drug-resistant strains that replicate even during its use.⁸ Despite not having undergone a viral resistance test to acyclovir, the patient in the present case report had been submitted to monotherapy with this medication for months without any improvement. Studies of resistance patterns of HSV to different antiviral agents used in daily practice and the characterization of mutant strains of HSV have shown that resistance is due to loss or modification of the viral enzyme thymidine kinase or changes in viral DNA polymerase.⁹ Based on the promising results of the asso-

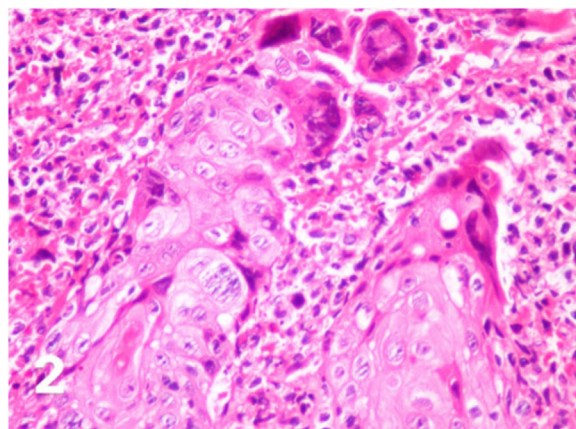


Figure 2 Cytopathic effects of herpes simplex such as ballooning degeneration of keratinocytes, marginalized chromatin, multinucleated giant cells (Hematoxylin & eosin, $\times 400$).

ciation of topical imiquimod with the established antiviral therapy, including cases that were not submitted to drug susceptibility testing, the combination therapy was chosen. It is believed that the improvement in local immunity provided by imiquimod would explain the clinical improvement of the lesions, as the increase in interferon alpha plays an important role in controlling viral infections.⁷ Considering the relatively rapid response to the proposed treatment, the hypothesis that this would not be a case of drug resistance, but refractoriness to the treatment due to deficient local immunity in a patient with AIDS is supported.

There have been reported cases of occlusion therapy with this topical drug, a technique that is usually not well accepted by patients due to local side effects. However, a study was published in which the patient showed an excel-

lent result and no side effects, with complete regression of the lesion after 10 weeks of imiquimod use.¹⁰

Finally, it is important to emphasize that lesions with unusual presentations can make the diagnosis of HSV difficult. The main therapeutic regimen remains the use of acyclovir, but in patients with immunodeficiency, the association of the antiviral and the topical use of imiquimod has shown good results. Although further studies are still required, the case reported herein may help to support the use of imiquimod as a promising drug in the treatment of genital infections caused by HSV refractory to the traditional therapy.

Financial support

None declared.

Authors' contributions

Suellen Ramos de Oliveira: Concepts; design; definition of intellectual content; literature search; clinical studies; data acquisition; data analysis; manuscript preparation; manuscript editing; manuscript review; guarantor.

Ariane Sponchiado Assoni: Concepts; design; definition of intellectual content; literature search; clinical studies; data acquisition; manuscript preparation; manuscript editing; guarantor.

Thiago Jeunon de Sousa Vargas: Concepts; design; definition of intellectual content; clinical studies; data analysis; manuscript review; guarantor.

Egon Daxbacher: Concepts; design; definition of intellectual content; clinical studies; data analysis; manuscript review; guarantor.





Conflicts of interest

None declared.

References

1. Tandon S, Singh J, Sinha S, Sharma DP. Recalcitrant hypertrophic herpes genitalis in HIV-infected patient successfully treated with topical imiquimod. *Dermatol Ther*. 2017;30.

2. Perkins N, Nisbet M, Thomas M. Topical imiquimod treatment of aciclovir-resistant herpes simplex disease: case series and literature review. *Sex Transm Infect*. 2011;87:292–5.
3. Wagstaff AJ, Perry CM. Topical imiquimod: a review of its use in the management of anogenital warts, actinic keratoses, basal cell carcinoma and other skin lesions. *Drugs*. 2007;67:2187–210.
4. Deza G, Martin-Ezquerro G, Curto-Barredo L, García JV, Pujol RM. Successful treatment of hypertrophic herpes simplex genitalis in HIV-infected patient with topical imiquimod. *J Dermatol*. 2015;42:1176–8.
5. Danielsen AG, Petersen CS, Iversen J. Chronic erosive herpes simplex virus infection of the penis in a human immunodeficiency virus-positive man, treated with imiquimod and famciclovir. *Br J Dermatol*. 2002;147:1034–6.
6. Barbosa LN, Souto R, Furtado AL, Gripp AC, Daxbacher E. Association of oral acyclovir and imiquimod for the treatment of hypertrophic genital herpes simplex in HIV positive patients: report of two cases. *An Bras Dermatol*. 2011;86:1043–5.
7. Abbo L, Vincek V, Dickinson G, Shrestha N, Doblecki S, Haslett PAJ. Selective defect in plasmacytoid dendritic cell function in a patient with AIDS-associated atypical genital herpes simplex vegetans treated with imiquimod. *Clin Infect Dis*. 2007;44:25–7.
8. Camasmie HR, Barbosa C, Lupi O, Lima RB, Serra M, D'Acri AM, et al. Extensive and refractory genital herpes in human immunodeficiency virus-infected patient successfully treated with imiquimod: case report and literature review. *Indian J Dermatol Venereol Leprol*. 2017;83:256–9.
9. Scieux C, Bianchi A. Resistance of herpes simplex viruses to antiviral drugs. *Pathol Biol*. 1993;4:172–7.
10. Lestre SIA, João A, Carvalho C, Serrão VV. Hypertrophic perianal herpes successfully treated with imiquimod. *An Bras Dermatol*. 2011;86:1185–8.

Suellen Ramos de Oliveira *,
Ariane Sponchiado Assoni ,
Thiago Jeunon de Sousa Vargas , Egon Daxbacher 

Hospital Federal de Bonsucesso, Rio de Janeiro, RJ, Brazil

* Corresponding author.

E-mail: suellenramospa.sr91@gmail.com (S.R. Oliveira).

Received 18 August 2020; accepted 13 October 2020
available online 14 January 2022

<https://doi.org/10.1016/j.abd.2020.10.019>
0365-0596/ © 2021 Sociedade Brasileira de Dermatologia.
Published by Elsevier España, S.L.U. This is an open access article under the CC BY license (<http://creativecommons.org/licenses/by/4.0/>).

Bullous Sweet syndrome with a unique photodistributed pattern[☆]



Dear Editor,

A 54-year-old female was admitted to our department, complaining of a 4-day history of up to 40.3 °C fever and cutaneous eruptions on the neck. The patient had been

suffering from myelodysplastic syndrome (MDS), for which no drugs, including granulocyte-colony stimulating factor (G-CSF), were administered. Physical examination showed numerous condescences of blisters clearly localized in the V-neck area (Fig. 1a, b). Painful erythematous nodules were scattered on the cheeks, but the tip of the nose was spared. Furthermore, there was one blister on the right forearm as well as painful erythematous nodules on the upper and lower extremities. She did not have any mucosal lesions or a prior history of recurrent oral aphthae. Laboratory examination showed a white blood cell count of 8,100/μL with 3% Band, 21% Seg, 9% Lym, 7% Mono, and 57% Blast, decreased levels

[☆] Study conducted at the Department of Dermatology, Fukushima Medical University School of Medicine.