

Gianfranco Barabino: Conception and planning of the study; elaboration and writing of the manuscript; approval of the final version of the manuscript; effective participation in research orientation; intellectual participation in propaedeutic and/or therapeutic conduct of the cases studied; critical review of the literature; critical review of the manuscript.

Aurora Parodi: Conception and planning of the study; elaboration and writing of the manuscript; approval of the final version of the manuscript; obtaining, analyzing, and interpreting the data; effective participation in research orientation; intellectual participation in propaedeutic and/or therapeutic conduct of the cases studied; critical review of the literature; critical review of the manuscript.

## Conflicts of interest

None declared.

## References

- de Freitas MR, Said G. Leprous neuropathy. *Handb Clin Neurol*. 2013;115:499–514.
- Girdhar BK. Neuritic leprosy. *Indian J Lepr*. 1996;68:35–42.
- Jardim MR, Antunes SL, Santos AR, Nascimento OJ, Nery JA, Sales AM, et al. Criteria for diagnosis of pure neural leprosy. *J Neurol*. 2003;250:806–9.
- Reja AH, De A, Biswas S, Chattopadhyay A, Chatterjee G, Bhattacharya B, et al. Use of fine needle aspirate from peripheral nerves of pure-neural leprosy for cytology and PCR to confirm the diagnosis: a pilot study. *Indian J Dermatol Venereol Leprol*. 2013;79:789–94.
- De A, Hasanooor Reja AH, Aggarwal I, Sen S, Sil A, Bhattacharya B, et al. Use of Fine Needle Aspirate from Peripheral Nerves of Pure-neural Leprosy for Cytology and Polymerase Chain Reaction to Confirm the Diagnosis: A Follow-up Study of 4 Years. *Indian J Dermatol*. 2017;62:635–43.

Ilaria Trave <sup>a,\*</sup>, Alberto Cavalchini <sup>b</sup>, Gianfranco Barabino <sup>b</sup>, Aurora Parodi <sup>a</sup>

<sup>a</sup> Section of Dermatology - Department of Health Sciences, University of Genoa, IRCCS - Ospedale Policlinico San Martino, Genoa, Italy

<sup>b</sup> Section of Dermatology- Ospedale Policlinico San Martino, Genoa, Italy

\*Corresponding author.

E-mail address: [ilaria.trave@gmail.com](mailto:ilaria.trave@gmail.com) (I. Trave).

Received 24 April 2020; accepted 31 May 2020  
Available online 20 March 2021

<https://doi.org/10.1016/j.abd.2020.05.017>  
0365-0596/ © 2021 Sociedade Brasileira de Dermatologia.  
Published by Elsevier España, S.L.U. This is an open access article under the CC BY license (<http://creativecommons.org/licenses/by/4.0/>).

## Axillary papules: an uncommon location of lichen nitidus<sup>☆,☆☆</sup>



Dear Editor,

Lichen nitidus is a relatively rare, chronic, papulosquamous cutaneous disease that is characterized by multiple flesh-coloured shiny, dome-shaped papules, with sizes from 1 to 2 mm, often referred as pinhead-like papules.<sup>1</sup> The crop of the lesions often is asymptomatic; moreover, it sometimes may associate with pruritus.<sup>1</sup> This uncommon condition was described for the first time by Pinkus in 1901.<sup>2</sup> The skin is the primary site involved but the mucous membranes and nails also might be affected.<sup>3</sup>

No racial or sex predilection is reported, although the majority of cases appear to arise in children and young adults.<sup>1,4</sup> There are located and generalized forms of lichen nitidus, sometimes described under clinical variants: familiar, actinic, confluent, vesicular, hemorrhagic, palmo-plantaris, mucous, spinulosus and follicularis, keratodermic, perforating or linear.<sup>2,5</sup> The lesions are located preferentially on the flexor surface of the arms, wrists,

on the abdomen and genitalia, though they can become disseminated.<sup>5</sup> We are adding to the indexed literature the second case of lichen nitidus exclusively located on both axillae.

The patient is a 26-year-old Caucasian man who was seen for evaluation of asymptomatic lesions on the both axillae; the lesions had been present more than 4-years and showed insidious emergence. He denied previous treatment on the lesions or any medication intake preceding the crop of the lesions. On his dermatological exam, discrete or grouped skin-colored, shiny, firm, monomorphic round, and dome-topped papules of 1-to 3-mm in diameter were observed on both axillae (Fig. 1).

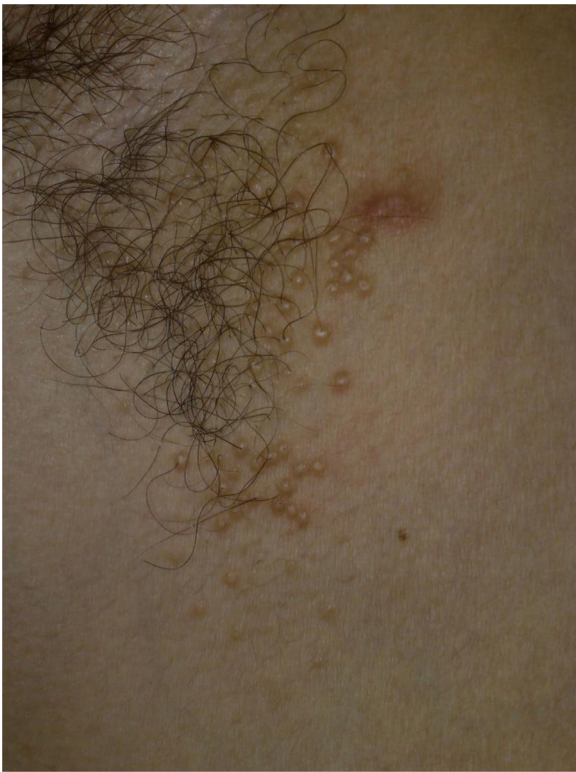A skin biopsy was performed from these lesions, and that displayed a lymphohistiocytic infiltrate in a broadened dermal papilla, with a descending growth of the rete ridges surrounding the dermal inflammatory infiltrate in a “ball-and-claw” manner (Figs. 2 and 3). The overlying epidermis was noted to be unremarkable, and there was no evidence of spongiosis or exocytosis.

The patient was treated with the combination of dexchlorpheniramine 2 mg and betamethasone 0.25 mg t.i.d per os for 10-days, and after that he was virtually clear of lesions.

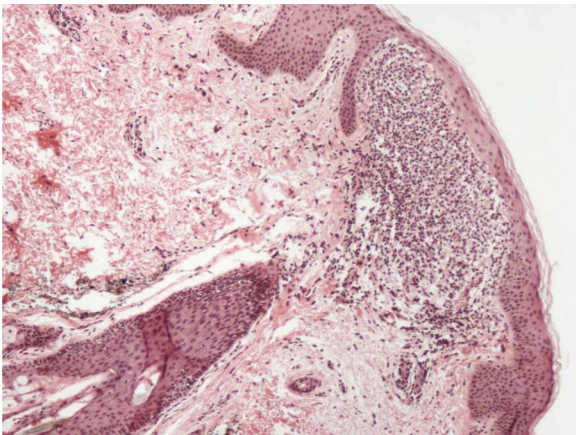
There is only one report of lichen nitidus on axillae.<sup>3</sup> Our patient displayed lesions only in this area, emphasizing the peculiar aspect of our report. Once considered as a tuberculoid reaction, lichen nitidus is currently regarded as a disorder of unknown origin. The differential diagnosis includes lichen planus, psoriasis, verruca plana and

<sup>☆</sup> How to cite this article: Belda Jr W, Criado PR, Di Chiacchio NG. Axillary papules: an uncommon location of lichen nitidus. *An Bras Dermatol*. 2021;96:381–3.

<sup>☆☆</sup> Study conducted at the Faculdade de Medicina do ABC, São Paulo, SP, Brasil.



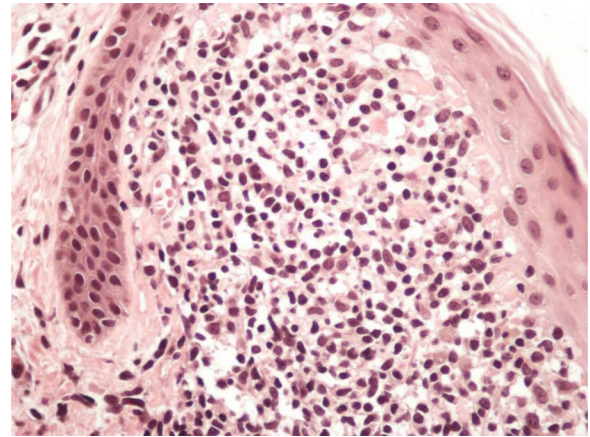
**Figure 1** Right axilla presenting discrete and grouped skin-colored, shiny, firm, monomorphic round, and dome-topped papules of 1-to 3-mm.



**Figure 2** Infiltrate in a broadened dermal papilla, with a descending growth of the rete ridges surrounding the dermal inflammatory infiltrate in a "ball-and-claw" manner, (Hematoxylin & eosin,  $\times 40$ ).

keratosis pilaris.<sup>1,4</sup> Rare cases of lichen nitidus associated with atopic dermatitis, Crohn disease, Down's syndrome and juvenile chronic arthritis have been reported.<sup>1,3</sup> The first clinical hypothesis in this case was Fox-Fordyce disease due the presence of popular lesions on the axillae. The final diagnosis was established on histopathological basis.

Due to the rare clinical presentation of lichen nitidus exclusively located on the both axillae, the clinicians must alert to the necessity of performing cutaneous biopsy to



**Figure 3** Higher magnification showing the lymphohistiocytic infiltrate in a broadened dermal papilla, (Hematoxylin & eosin,  $\times 200$ ).

confirm this diagnosis. The histological study of the biopsy showed characteristic findings of lichen nitidus, including lymphohistiocytic infiltrate in an expanded dermal papilla with thinning of overlying epidermis and downward extension of the rete ridges at the lateral margin of the infiltrate, producing a typical "claw clutching a ball" picture.<sup>1,5</sup>

In two-thirds of patients the lesions resolve spontaneously after months to 1 year. Topical glucocorticoids can be useful in localized forms.<sup>1</sup>

In this case, the patient was successfully treated with the combination of dexchlorpheniramine 2 mg and betamethasone 0.25 mg t.i.d per os for 10-days.

The authors would like to highlight the rarity of the presentation of this case and the importance of considering the lichen nitidus as a differential diagnosis of papular lesions in the axillae, itchy or not.

### Financial support

None declared.

### Authors' contributions

Walter Belda Junior: Statistical analysis; approval of the final version of the manuscript; design and planning of the study; drafting and editing of the manuscript; collection, analysis, and interpretation of data; effective participation in research orientation; intellectual participation in the propaedeutic and/or therapeutic conduct of the studied cases; critical review of the literature; critical review of the manuscript.

Paulo Ricardo Criado: Statistical analysis; approval of the final version of the manuscript; design and planning of the study; drafting and editing of the manuscript; collection, analysis, and interpretation of data; effective participation in research orientation; intellectual participation in the propaedeutic and/or therapeutic conduct of the studied cases; critical review of the literature; critical review of the manuscript.

Nilton Gioia Di Chiacchio: Statistical analysis; approval of the final version of the manuscript; design and planning of the study; drafting and editing of the manuscript; collection, analysis, and interpretation of data; effective participation in research orientation; intellectual participation in the propaedeutic and/or therapeutic conduct of the studied cases; critical review of the literature; critical review of the manuscript.

## Conflicts of interest

None declared.

## References

1. Arizaga AT, Guadhan MD, Bang RH. Generalized lichen nitidus. *Clin Exp Dermatol*. 2002;27:115–7.
2. Rodriguez-Martin M, Rodriguez-Garcia F, Sáez M, Cabera R, Pérez-Robayna N, Sidro M, et al. [Pruritic papules in the axillae]. *Actas Dermosifiliogr*. 2006;97:281–3.
3. Bettoli V, De Padova MP, Corazza M, Virgili A. Generalized lichen nitidus with oral and nail involvement in a child. *Dermatology*. 1997;194:367–9.
4. Francouer C, Frost M, Treadwell P. Generalized pinhead-sized papules in a child. *Arch Dermatol*. 1988;124:935–8.
5. Arrue I, Arregui MA, Saracibar N, Soloeta R. Perforating lichen nitidus on an atypical site. *Actas Dermosifiliogr*. 2009;100:429–31.

Walter Belda Junior <sup>a</sup>, Paulo Ricardo Criado <sup>b</sup>,  
Nilton Gioia Di Chiacchio <sup>b,c,\*</sup>

<sup>a</sup> Faculdade de Medicina, Universidade de São Paulo, São Paulo, SP, Brasil

<sup>b</sup> Faculdade de Medicina do ABC, São Paulo, SP, Brazil

<sup>c</sup> Hospital do Servidor Público Municipal de São Paulo, São Paulo, SP, Brazil

\* Corresponding author.

E-mail address: [dichiacchiong@gmail.com](mailto:dichiacchiong@gmail.com) (N.G. Di Chiacchio).

Received 14 January 2020; accepted 11 April 2020  
Available online 16 March 2021

<https://doi.org/10.1016/j.abd.2020.04.015>  
0365-0596/ © 2021 Published by Elsevier España, S.L.U. on behalf of Sociedade Brasileira de Dermatologia. This is an open access article under the CC BY license (<http://creativecommons.org/licenses/by/4.0/>).

## Beefy red asymptomatic penile lesion: unusual presentation of squamous cell carcinoma<sup>☆,☆☆</sup>



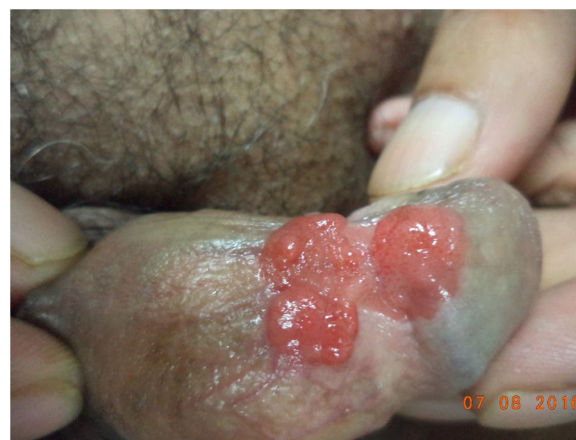Dear Editor,

A 65-year-old male was presented with a lobulated beefy red plaque on his penile shaft with a two-month duration. During the physical examination there was a well-defined non-tender erythematous, lobulated, sessile with a growth of size of approximately 5 × 3 cm involving glans, coronal sulcus and the penis shaft (Fig. 1). There was no lymphadenopathy. Initially, the patient had mild pruritus and with subsequent interval of time noticed tiny penile growth which gradually progressed to an increased present size in a two-month duration, along with some difficulty to retract the prepuce. No history of dysuria was present. He was otherwise in good health. His family, medical and social history was non-contributory. He had history of smoking for 20 to 25 years, and quit smoking for the last 5-year period.

Even though the patient denied any sexual contact, a differential diagnosis of condyloma acuminata, condyloma lata and granuloma inguinale were kept with other remote differentials, which were verruciform xanthoma and squamous cell carcinoma. All biochemical and haematological investigations including lipid profile, liver function test, kidney function test, serum electrolytes, routine and a microscopic

examination of urine and complete blood count were within normal limit. Dark ground microscopy for *Treponema pallidum* and tissue-smear for Donovan bodies were negative. A serological test for syphilis and Elisa for HIV Type 1 and 2 were negative. The initial biopsy specimen reported condyloma acuminata with squamous cell showing loss of polarity without any cytological atypia. Repeat biopsy was sent, which was consistent with squamous cell carcinoma with papillary features (Fig. 2). An ultrasound of the abdomen and pelvis was done, which were normal. A surgical excision was done and this re-confirmed the diagnosis of squamous cell carcinoma in situ.

The asymptomatic beefy red lobulated plaque on the penile region has various differentials. As the patient had a negative tissue smear, the possibility of Condyloma



**Figure 1** Well defined, erythematous, fleshy, lobulated, sessile growth involving glans, coronal sulcus and shaft of penis.

<sup>☆</sup> How to cite this article: Rani S, Sardana K, Ahuja A. Beefy red asymptomatic penile lesion: unusual presentation of squamous cell carcinoma. *An Bras Dermatol*. 2021;96:383–4.

<sup>☆☆</sup> Study conducted at the Department of Dermatology, Dr Ram Manohar Lohia Hospital, New Delhi, India.