

3. Ryu WC, Lee YH, Koh IC, Sohn JS, Jang SM, Jang SM. Hidradenocarcinoma of the Dorsum of the Hand. *Chin Med J (Engl)*. 2017;130:1755–6.
4. Miller DH, Peterson JL, Buskirk SJ, Vallow LA, Ta R, Joseph R, et al. Management of metastatic apocrine hidradenocarcinoma with chemotherapy and radiation. *Rare Tumors*. 2015; 7:6082.
5. Hoang MP. Role of immunohistochemistry in diagnosing tumors of cutaneous appendages. *Am J Dermatopathol*. 2011;33: 765–71.

Andrey Amorim de Lima <sup>a,\*</sup>, Monica Santos <sup>a</sup>,  
 Patricia Motta de Moraes <sup>b</sup>,  
 Carlos Alberto Chirano Rodrigues <sup>c</sup>

<sup>a</sup> Teaching and Research Department, Fundação de Dermatologia Tropical e Venereologia Alfredo da Matta, Manaus, AM, Brazil

<sup>b</sup> Department of Dermatopathology, Fundação de Dermatologia Tropical e Venereologia Alfredo da Matta, Manaus, AM, Brazil

<sup>c</sup> Department of Dermatological Surgery, Fundação de Dermatologia Tropical e Venereologia Alfredo da Matta, Manaus, AM, Brazil

\* Corresponding author.

E-mail: [amorim\\_andrey@hotmail.com](mailto:amorim_andrey@hotmail.com) (A.A. de Lima).

Received 21 December 2019; accepted 5 March 2020

Available online 5 February 2021

<https://doi.org/10.1016/j.abd.2020.03.023>

0365-0596/ © 2021 Sociedade Brasileira de Dermatologia.

Published by Elsevier España, S.L.U. This is an open access article under the CC BY license (<http://creativecommons.org/licenses/by/4.0/>).

## A late diagnosis of hyperhomocysteinemia with probable evolution to verrucous elephantiasis nostra and leg ulcers<sup>☆☆</sup>



Dear editor,

Homocysteine is an intermediate amino acid derived from the metabolism of methionine into cysteine, with a demonstrated association with oxidative stress and endothelial damage.<sup>1</sup>

Hyperhomocysteinemia can be caused by genetic disorders in metabolic pathways, nutritional deficiency, renal failure, hypothyroidism, diabetes, and smoking.<sup>1–3</sup> It is an important risk factor for cardiovascular mortality in patients with a history of myocardial infarction, stroke, angina, diabetes, or hypertension.<sup>2</sup>

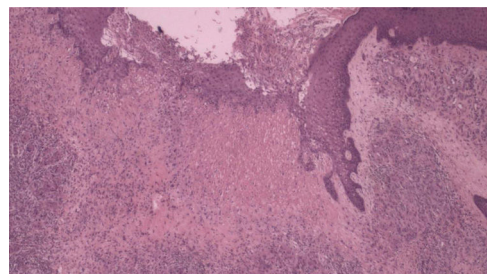
A black male patient, 60 years old, started follow-up with the dermatology service in 2011 due to symptoms of xerosis and lower limb edema in the last eight years. At the time, a biopsy was performed and revealed thickening of the epidermis, acanthosis, lengthening of the grooves, and deposits of dermal mucin. Colloidal iron staining was positive and Congo red staining was negative, the clinical and pathological diagnosis was pre-tibial myxedema.

The patient developed thrombophlebitis in the left lower limb, with no deep venous thrombosis. The authors decided to initiate antibiotic therapy for erysipela and, subsequently, prophylactic intramuscular benzathine benzylpenicillin was prescribed every 21 days. Topical care was

performed with the use of dressings containing collagenase and chloramphenicol.

During evolution, periods of healing were interspersed with worsening. In 2018, when thrombophilia tests became available at the health institution, a panel for hypercoagulable states was performed: protein C and S dosages, antithrombin, total complement and C3, prothrombin gene, Leiden factor mutation, anticardiolipin and lupus antibodies, protein electrophoresis, and ANA, were all within the normal range. There were, serum homocysteine levels of 17.8  $\mu\text{mol/L}$  (normal range: 5 to 12  $\mu\text{mol/L}$ ) and heterozygosity in segments C677T and A1298C for the methylenetetrahydrofolate reductase (MTHFR) mutation was observed.

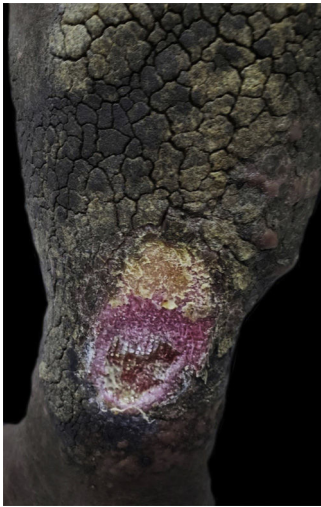Another skin biopsy (Fig. 1) and Doppler ultrasonography of the left lower limb were performed. Histopathologically, there was fibroplasia, newly formed vessels associated with inflammatory lymphocytic infiltrate and a neutrophilic exudate in the dermis. Upon ultrasound examination, varicose veins, incontinence of the great saphenous, and popliteal veins associated with recanalized thrombophlebitis of the great saphenous vein were identified.



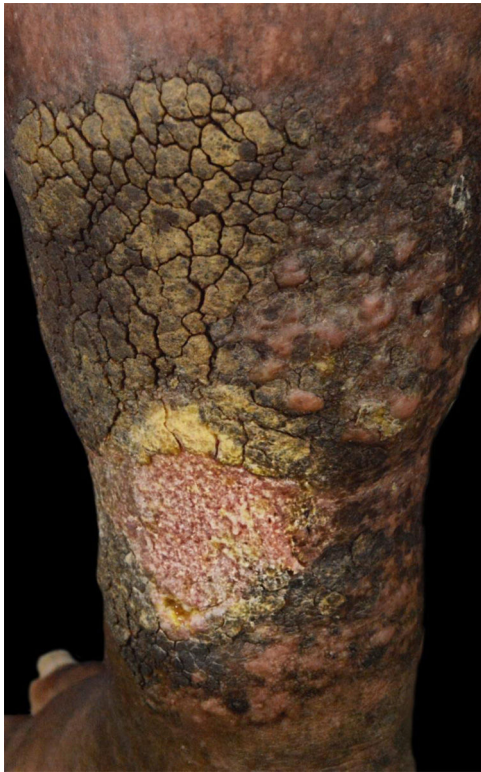**Figure 1** Histopathology demonstrating fibroplasia, newly formed vessels associated with an inflammatory infiltrate containing lymphocytes and neutrophils (Hematoxylin & eosin,  $\times 40$ ).

<sup>☆</sup> How to cite this article: Abdalla BMZ, Oliveira RTG, Afonso RI, Criado PR. A late diagnosis of hyperhomocysteinemia with probable evolution to verrucous elephantiasis nostra and leg ulcers. *An Bras Dermatol*. 2021;96:253–5.

<sup>☆☆</sup> Study conducted at the Faculdade de Medicina do ABC, Santo André, SP, Brazil.



**Figure 2** Left leg ulcer before treatment.



**Figure 3** Complete healing of the left leg ulcer after two months of treatment.

Treatment was initiated with the use of a vitamin B complex and oral folic acid, in addition to maintaining daily dressings.

After six months, serum homocysteine levels improved to 16.2  $\mu\text{mol/L}$  and the dermatological lesions healed (Figs. 2 and 3).

In the subsequent one-year follow-up, the patient did not present new ulcers.

The vascular changes induced by hyperhomocysteinemia are multifactorial, including damage to the endothelium, increased lipid peroxidation, and platelet aggregation.<sup>1</sup> The

damage to the vessel is the result of an inflammatory process that causes the adhesion of neutrophils and T cells to endothelial cells, with subsequent release of cytokine IL-8 and monocytes-1 chemoattractant protein.<sup>1</sup>

The MTHFR enzyme catalyzes the methyltetrahydrofolate step necessary for the resynthesis of methionine from homocysteine.<sup>3</sup> The cofactor vitamin B12 and folic acid participate in this metabolic pathway.<sup>4</sup>

The MTHFR gene has at least two functional polymorphisms, 677CT and 1298AC.<sup>3</sup> The first allele is associated with reduced enzyme activity; concentrations in serum, plasma, and red blood cells; and increased plasma homocysteine concentration.<sup>3</sup>

Hyperhomocysteinemia is found in cases of dermatitis and ulceration due to stasis, which indicate that it may be associated with their pathogenesis.<sup>1,5</sup> Supplementation with vitamin B6, B12, and folic acid can decrease homocysteine levels, even in patients with normal serum vitamin concentrations.<sup>1,3</sup>

This present case should alert physicians about hypercoagulable states in patients with leg ulcers under 50 years of age, as well as the need for a different approach in the evolution of lower extremity ulcers.

The authors advocate laboratory investigation of homocysteine in the differential diagnosis in cases of lower limb ulcers.<sup>4</sup>

The reduction of homocysteine using the replacement of certain selected vitamin supplements may be the future direction for preventing the development of the disease.<sup>1,3</sup>

### Financial support

None declared.

### Authors' contributions

Beatrice Abdalla: Approval of the final version of the manuscript; design and planning of the study; drafting and editing of the manuscript; collection, analysis, and interpretation of data; critical review of the literature.

Renan Tironi Giglio de Oliveira: Drafting and editing of the manuscript.

Rafaela Issa Afonso: Intellectual participation in propaedeutic and/or therapeutic conduct of studied cases.

Paulo Ricardo Criado: Approval of the final version of the manuscript; intellectual participation in propaedeutic and/or therapeutic conduct of studied cases; critical review of the literature; critical review of the manuscript.

### Conflicts of Interest

None declared.

### References

1. Durmazlar SPK, Akgul A, Eskioglu F. Hyperhomocysteinemia in patients with stasis dermatitis and ulcer: A novel finding with important therapeutic implications. *J Dermatolog Treat.* 2009;20:336–9.

- de Franciscis S, de Sarro G, Longo P, Buffone G, Molinari V, Stilitano DM, et al. Hyperhomocysteinaemia and chronic venous ulcers. *Int Wound J*. 2015;12:22–6.
- Brustolin S, Giugliani R, Félix TM. Genetics of homocysteine metabolism and associated disorders. *Braz J Med Biol Res*. 2010;43:1–7.
- Çaytemel C, Demir FT, Büyükbabani N, Türkoğlu Z, Uzuner EG. Multifactorial Painful Leg Ulcers Due to Hyperhomocysteinemia, Plasminogen Activator Inhibitor-1 4G/5G Heterozygote Gene Mutation, and Beta Thalassemia Minor: A Case Report. *Int J Low Extrem Wounds*. 2019;18:339–41.
- Pugashetti R, Zedek DC, Seiverling EV, Rajendran P, Berger T. Dermal mucinosis as a sign of venous insufficiency. *J Cutan Pathol*. 2010;37:292–6.

Beatrice Martinez Zugaib Abdalla  <sup>a,\*</sup>,  
Renan Tironi Giglio de Oliveira  <sup>a</sup>,  
Rafaela Issa Afonso  <sup>a</sup>, Paulo Ricardo Criado  <sup>b,c</sup>

<sup>a</sup> Faculdade de Medicina do ABC, Santo André, SP, Brazil  
<sup>b</sup> Department of Dermatology, Faculdade de Medicina, Universidade de São Paulo, São Paulo, SP, Brazil  
<sup>c</sup> Centro Universitário Saúde ABC, Santo André, SP, Brazil

\* Corresponding author.

E-mail: [bmzabdalla@gmail.com](mailto:bmzabdalla@gmail.com) (B.M. Abdalla).

Received 29 November 2019; accepted 13 April 2020

Available online 31 January 2021

<https://doi.org/10.1016/j.abd.2020.04.014>

0365-0596/ © 2021 Sociedade Brasileira de Dermatologia.

Published by Elsevier España, S.L.U. This is an open access article under the CC BY license (<http://creativecommons.org/licenses/by/4.0/>).

## Reactive eccrine syringofibroadenoma triggered by thermal damage: case report <sup>☆,☆☆</sup>



Dear editor,

Eccrine syringofibroadenoma (ESFA) is a rare tumor that consists of the proliferation of ductal structures that resemble the acral portion of the eccrine sweat glands. It was first described by Mascaró in 1963, and there are just over 70 published cases in the literature.<sup>1,2</sup> Although histologically distinct, the clinical presentation of ESFA is variable, from a solitary papule, plaque, or nodule to multiple lesions, with a predilection for the limbs of older patients.<sup>2,3</sup> There is no consensus regarding its pathogenesis: tumor, hamartoma, or reactive hyperplasia.<sup>4</sup> This report adds unprecedented aspects, as it demonstrates the association of ESFA with thermal damage and successful treatment using topical corticosteroids.

The authors report the case of a 71-year-old male, retired and without comorbidities. He reported the use of heat-generating plaster, consisting of iron powder, activated carbon, vermiculite, potassium chloride, and water (Fenaflan Patch<sup>®</sup>) to treat pain in the lateral region of the right thigh. However, there was a local reaction with burning and heat sensation, which caused the patient to remove the plaster before the indicated time. In the following days, he developed erythematous papules and a vegetating plaque, sometimes friable and bleeding, with mild pruritus. It progressed for three months, reaching the size of 4 cm (Fig. 1). A 5-mm punch biopsy was performed. The anatomopathological examination revealed anastomosing epithelial cords of cuboid cells forming trabeculae embedded in fibrous and myxoid stroma, which were highly vascularized from the epi-

dermis to the deep dermis. The diagnosis of reactive type ESFA was confirmed (Figs. 2 and 3).

Clobetasol in 0.05% cream was administered with occlusive application once a day for 20 days, with a fully effective response. The post-inflammatory residual erythema resolved completely within a few months.

The most current classification of ESFA includes five subtypes: solitary; multiple without skin changes; nevoid associated with ectodermal dysplasia; multiple associated with Schöpf syndrome; and the reactive subtype, associated with neoplastic or inflammatory dermatoses.<sup>3</sup> The literature presents the occasional description with other entities, both inflammatory and neoplastic, including bullous pemphigoid, palmoplantar erosive lichen planus, psoriasis, congenital syphilis, nevus sebaceous, chronic skin ulcer, basal cell carcinoma, and squamous cell carcinoma.<sup>2</sup>

The reactive type is probably triggered by tissue damage and, in the process of repair and remodeling, there is hyperplasia in response to the damage.<sup>3</sup> However, this is the first report in the literature to associate thermal injury as the triggering factor for ESFA.

Histopathology assessment is necessary for diagnostic confirmation, the eccrine ducts may or may not be demonstrated. Immunohistochemistry can help in difficult cases, with cells often positive for keratin 6 and 19, as well as filaggrin.<sup>2</sup>

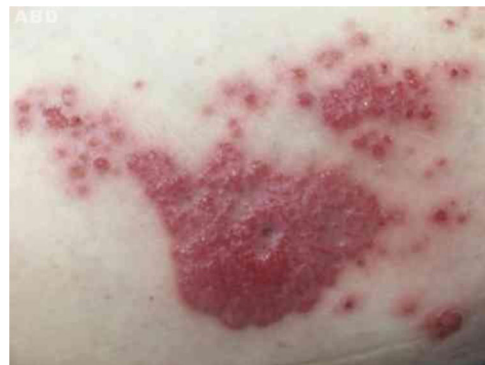

Fig. 1 Vegetating plaque and erythematous and pinkish papules grouped in the lateral region of the right thigh.

<sup>☆</sup> How to cite this article: Cunha Filho RR, Quioca LJ, Rastelli GJC, Fillus Neto J. Reactive eccrine syringofibroadenoma triggered by thermal damage: case report. *An Bras Dermatol*. 2021;96:255–6.

<sup>☆☆</sup> Study conducted at the Universidade do Oeste de Santa Catarina, Joaçaba Campus, SC, Brazil.