

## Scanning electron microscopy of dermatofibroma\*

Felipe Simões Lopes Quintana<sup>1,2</sup>, Hiram Larangeira de Almeida Jr.<sup>1,3</sup>, Caroline Pires Ruas<sup>4</sup>, Valéria Magalhães Jorge<sup>1,5</sup>

DOI: <http://dx.doi.org/10.1590/abd1806-4841.20197906>

**Abstract:** Dermatofibroma is a proliferation of spindle cells located in the dermis. We used scanning electron microscopy to examine two histologically confirmed lesions and observed preserved collagen bundles in the perilesional area. In the lesional area, the collagen was denser, without formation of bundles. Higher magnification showed collagen with mesh-like appearance similar to stretched tufts of cotton. Very high magnification evidenced the tufts of cotton and spindle cells measuring 2 to 12 microns.

**Keywords:** Collagen; Histiocytoma, Benign Fibrous; Microscopy, Electron, Scanning

### INTRODUCTION

Dermatofibroma (DFB) or fibrous histiocytoma is a proliferation of spindle cells located in the dermis, made up of a mixture of fibroblasts, collagen, and blood vessels. Several variants have been described. Histological features of some variants can coexist in the same lesion.<sup>1</sup>

In recent years, immunohistochemical studies have demonstrated factor XIIIa-positive dendritic cells, which may be involved in the genesis of DFB.<sup>2</sup>

DFB is one of the most common skin lesions, accounting for approximately 3% of skin lesion specimens received by dermatopathology laboratories.<sup>3</sup> Other histological variants described to date include aneurysmal, hemosiderotic, cellular, epithelioid, lipidized, clear cell, palisading, atrophic, keloidal, granular cell, myxoid, lichenoid, balloon cell, and signet ring cell variants.<sup>4-8</sup>

Dermatofibroma is composed of cells with round to oval shape and is a dermal nodule measuring less than 1 cm in diameter. Simple excision is usually curative, and local recurrence is rare.

Histologically, DFB is defined as a proliferation of spindle cells in variable proportions that are arranged in short woven fas-

cicles and histiocyte-like cells mixed with inflammatory and foamy siderophage cells in the dermis.

We report here the three-dimensional, ultrastructural findings of two DFB cases with scanning electron microscopy.

### RESULTS

A 46-year-old woman expressed her desire to have two dermatofibromas removed for aesthetic reasons. The excised fragment was cut in half; half was fixed in formalin for light microscopy and half in glutaraldehyde for scanning electron microscopy.

The findings were similar in the two lesions. Light microscopy with hematoxylin & eosin showed cell proliferation immersed in collagen without formation of bundles in the dermis (Figures 1a and b) and normal collagen bundles still observed in the lower portion of the fragment (Figure 1a). Higher magnification showed spindle-shaped cells in the affected area (Figure 1c). Weigert's stain revealed diminished density of elastic fibers in the area of fibroblast proliferation (Figure 1d).

Received 26 November 2017.

Accepted 16 March 2018.

\* Work conducted at Universidade Federal de Pelotas, Pelotas (RS), Brazil; Universidade Católica de Pelotas, Pelotas (RS), Brazil.

Financial support: None.

Conflict of interest: None.

<sup>1</sup> Post-Graduation Program in Health and Behavior, Universidade Católica de Pelotas, Pelotas (RS), Brazil.

<sup>2</sup> University Hospital, Universidade Federal de Pelotas, Pelotas (RS), Brazil.

<sup>3</sup> Department of Dermatology, Universidade Federal de Pelotas, Pelotas (RS), Brazil.

<sup>4</sup> Electron Microscopy Center of the South, Fundação Universidade de Rio Grande, Rio Grande (RS), Brazil.

<sup>5</sup> Pathology Department, Universidade Federal de Pelotas, Pelotas (RS), Brazil.

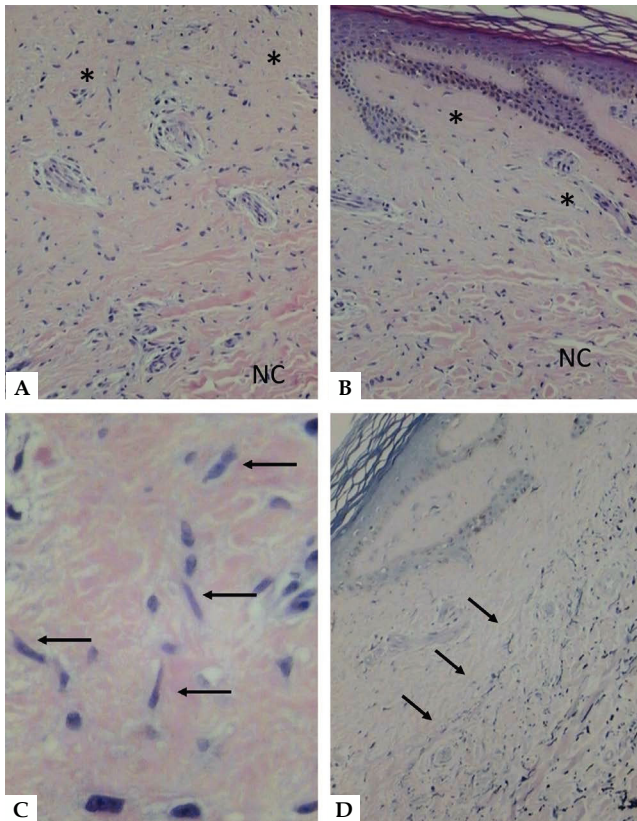
### MAILING ADDRESS:

Hiram Larangeira de Almeida Jr.

E-mail: [hiramalmeidajr@hotmail.com](mailto:hiramalmeidajr@hotmail.com)

©2019 by Anais Brasileiros de Dermatologia





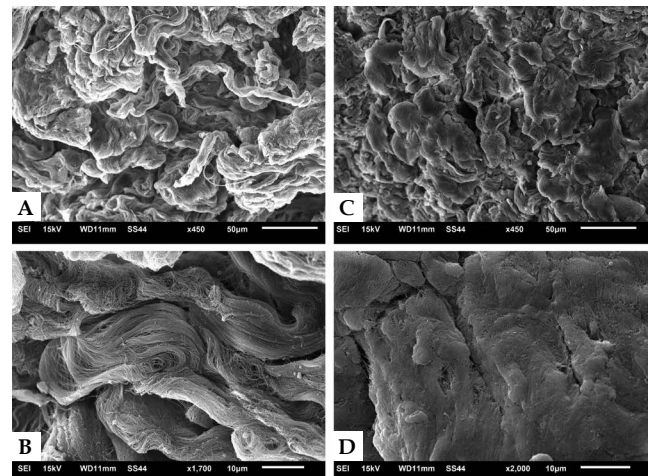
**FIGURE 1:** Light Microscopy - **A** - Collagen homogenization with cell proliferation (asterisks) with normal collagen in the lower portion (NC) (hematoxylin & eosin, x150). **B** - similar aspect in the lesion border, with involvement of the papillary dermis (hematoxylin & eosin, x150). **C** - detail of the fusiform cells (arrows) (hematoxylin & eosin, x400). **D** - diminished elastic fibers in the homogenous area, with clear demarcation of normal elastic tissue (arrows) in the lower portion (Weigert's stain, x150)

Scanning electron microscopy (SEM) showed preserved collagen bundles in the perilesional area (Figures 2a and b). In the lesional area, the collagen appeared denser, with no bundle formation (Figure 2c). Higher magnification showed collagen with mesh-like appearance similar to stretched tufts of cotton (Figure 2d). Very high magnification evidenced the "cotton tufts" (Figure 3a) and spindle cells measuring 2-12 microns (Figures 3b and c).


**DISCUSSION**

We found no reports in our literature review of three-dimensional analysis of DFB using SEM, but only studies with transmission electron microscopy, which only provides a two-dimensional analysis.<sup>9</sup>

Our findings demonstrated that, in addition to the proliferation of cells, there were important changes in dermal collagen on light microscopy which revealed no bundle formation and reduc-



**FIGURE 2:** Scanning electron microscopy. **A** - Low magnification of the perilesional area with normal collagen bundles (x450). **B** - Higher magnification of normal collagen bundles (x1,700). **C** - Low magnification of the lesional area with compact tufted collagen (x450). **D** - Higher magnification of affected compacted collagen (x2,000)



**FIGURE 3:** Scanning electron microscopy. **A** - Detail of the affected area with tufted collagen without bundle formation (x3,000). **B e C** - Detail of fusiform cells, measuring 2 to 12 microns (x7,000 and x8,000)





tion of elastic fibers in the affected area, confirming the changes in the normal dermal structure. Three-dimensional analysis identified the loss of normal configuration of collagen, which was entangled and not in bundles. Spindle cells could also be identified.

This structural modification in the dermis with changes in collagen configuration associated with the loss of elastic fibers may account for the typical fibrotic feeling of DFB on palpation. □

## REFERENCES

1. Barker SM, Winkelmann RK. Inflammatory lymphadenoid reactions with dermatofibroma/histiocytoma. *J Cutan Pathol.* 1986;13:222-6.
2. Song Y, Sakamoto F, Ito M. Characterization of factor XIIIa+ dendritic cells in dermatofibroma: Immunohistochemical, electron and immunoelectron microscopical observations. *J Dermatol Sci.* 2005;39:89-96.
3. Gonzales S, Duarte I. Benign fibrous histiocytoma of the skin. A morphologic study of 290 cases. *Pathol Res Pract.* 1982;174:379-91.
4. Han TY, Chang HS, Lee JH, Lee WM, Son SJ. A clinical and histopathological study of 122 cases of dermatofibroma (benign fibrous histiocytoma). *Ann Dermatol.* 2011;23:185-92.
5. Alves JV, Matos DM, Barreiros HF, Bártolo EA. Variants of dermatofibroma--a histopathological study. *An Bras Dermatol.* 2014;89:472-7.
6. Val-Bernal JF, Mira C. Dermatofibroma with granular cells. *J Cutan Pathol.* 1996;23:562-5.
7. Zelger BG, Sidoroff A, Zelger B. Combined dermatofibroma: co-existence of two or more variant patterns in a single lesion. *Histopathol.* 2000;36:529-39.
8. Luzar B, Calonje E. Cutaneous fibrohistiocytic tumours - an update. *Histopathol.* 2010;56:148-65.
9. Dominguez-Malagon H, Valdez-Carrillo Mdel C, Cano-Valdez AM. Dermatofibroma and dermatofibrosarcoma protuberans: a comparative ultrastructural study. *Ultrastruct Pathol.* 2006;30:283-91.

## AUTHORS' CONTRIBUTIONS

Felipe Simões Lopes Quintana	 ORCID	0000-0003-2781-1869
Approval of the final version of the manuscript; Conception and planning of the study; Elaboration and writing of the manuscript; Obtaining, analyzing and interpreting the data; Critical review of the literature; Critical review of the manuscript		
Hiram Larangeira de Almeida Jr	 ORCID	0000-0003-0705-1778
Approval of the final version of the manuscript; Conception and planning of the study; Elaboration and writing of the manuscript; Obtaining, analyzing and interpreting the data; Effective participation in research orientation; Critical review of the literature; Critical review of the manuscript		
Caroline Pires Ruas	 ORCID	0000-0002-6917-1727
Approval of the final version of the manuscript; Obtaining, analyzing and interpreting the data; Critical review of the manuscript		
Valéria Magalhães Jorge	 ORCID	0000-0003-3153-6847
Approval of the final version of the manuscript; Conception and planning of the study; Elaboration and writing of the manuscript; Obtaining, analyzing and interpreting the data; Effective participation in research orientation; Intellectual participation in propaedeutic and/or therapeutic conduct of the cases studied; Critical review of the literature; Critical review of the manuscript		

**How to cite this article:** Quintana FSL, Almeida Jr. HL, Ruas CP, Jorge VM. Scanning electron microscopy of dermatofibroma. *An Bras Dermatol.* 2019;94(3):358-60.