

PLECT or PPLECT? Granulomatous pyoderma gangrenosum in the differential diagnosis of the verrucous syndrome*

Kenselynn Oppermann¹, Ariane Rubin Cocco¹, Renata Heck¹, Renan Rangel Bonamigo^{1,2}

DOI: <http://dx.doi.org/10.1590/abd1806-4841.20187329>

Abstract: Pyoderma gangrenosum (PG) is an uncommon neutrophilic dermatosis, with variable clinical features, nonspecific histopathology and multifactorial pathogenesis, posing a challenging diagnosis for the dermatologist. Pyoderma gangrenosum is a diagnosis of exclusion and should be included in the differential diagnoses of the verrucous syndrome. We report a granulomatous variant affecting the face.

Keywords: Facial dermatoses; Granuloma; Pyoderma gangrenosum

Pyoderma gangrenosum (PG) is an uncommon entity with a diverse clinical spectrum and nonspecific histopathology. Awareness of its various manifestations, as well as its differential diagnoses, is essential for early therapy to reduce morbidity. On initial approach, PG should also be remembered as a clinical hypothesis of the verrucous syndrome.

We report a 72-year-old male patient who sought care for painful facial lesions that had evolved over six months. He reported that the first lesion appeared in the right temporal region and had rapidly and progressively worsened. Subsequently, a smaller lesion, though similar to the first one, appeared in the left temporal region. The patient was a smoker (more than 30 pack-years), previously healthy, and denied the use of medications.

The lesions consisted of verrucous, ulcerated, crusted plaques with erythematoviolaceous and infiltrated borders, initially in the right temporomalar region, with later involvement of the contralateral area (Figure 1). Two KOH preparations yielded blastoconidia and yeast-form hyphae, and oral itraconazole therapy instituted four months before showed no improvement.

On histopathology, a chronic granulomatous inflammatory process (Figure 2), with negative tests for fungi (PAS and Grocott) and mycobacteria (Ziehl-Neelsen), was observed. The samples sent

for detection and culturing of fungi, bacteria, and mycobacteria were negative. Direct inspection for *Leishmania sp.* (Giemsa) on the lesion was negative; the Mantoux (PPD) test was nonreactive.

After excluding infectious and neoplastic causes, the hypothesis of granulomatous PG variant was discussed and established as the principal possibility. Prednisone (1mg/kg/day), in combination with trimethoprim/sulfamethoxazole (TMP/SMX; 800mg + 160mg), was initiated, with regression of the lesions in the first month of treatment. Prednisone was gradually tapered and dapsone (50mg/day) substituted for TMP/SMX. Currently, the patient remains asymptomatic on dapsone (100mg/day) alone. The investigation for underlying diseases possibly associated with PG showed no abnormalities.

PG, first described by Brocq¹ and named by Brunsting *et al.*² in 1930, is a rare neutrophilic dermatosis of unknown etiology classically characterized by a crusted and painful ulcer with violaceous and undermined borders.³ The clinical spectrum is varied, and the diagnosis is based on clinicopathological correlation and on the exclusion of other causes.

PG can occur at any age, with predominance in adult women between the second and fifth decades of life. Its pathogenesis is multifactorial and involves neutrophilic dysfunction, inflammatory

Received 16 July 2017.

Accepted 13 October 2017.

* Work conducted at the Ambulatório de Dermatologia Sanitária de Porto Alegre, Porto Alegre (RS), Brazil.

Financial support: None.

Conflict of interests: None.

¹ Ambulatório de Dermatologia Sanitária de Porto Alegre, Porto Alegre (RS), Brazil.

² Service of Dermatology, Hospital de Clínicas de Porto Alegre, Universidade Federal do Rio Grande do Sul, Porto Alegre (RS), Brazil.

MAILING ADDRESS:

Kenselynn Oppermann

E-mail: kenselynn@gmail.com

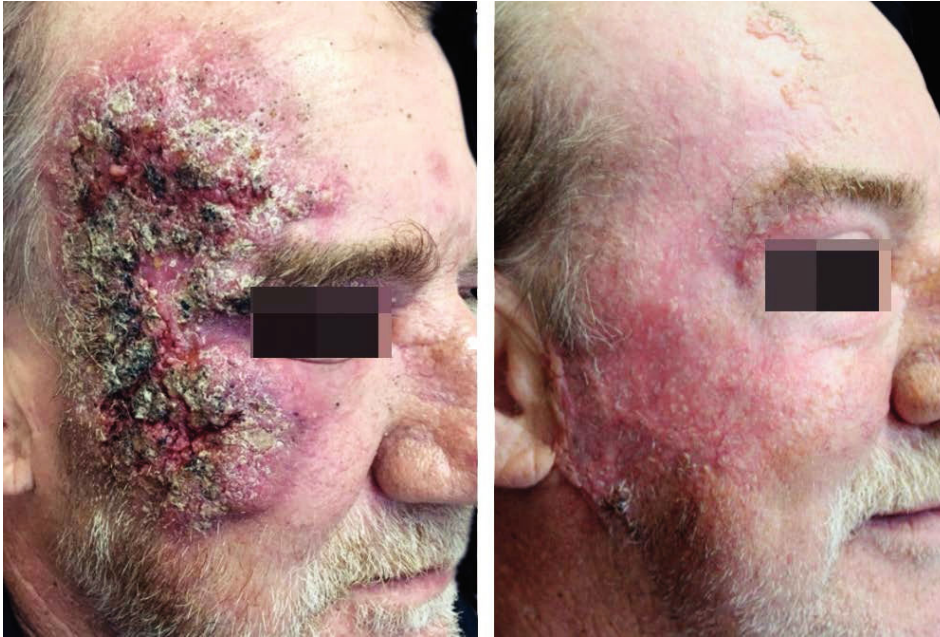

FIGURE 1: Before and after treatment. Left: extensive verrucous plaque in the right temporomalar region, with erythematous and infiltrated borders and scaly, crusted central ulcerations. Right: appearance after the established therapy

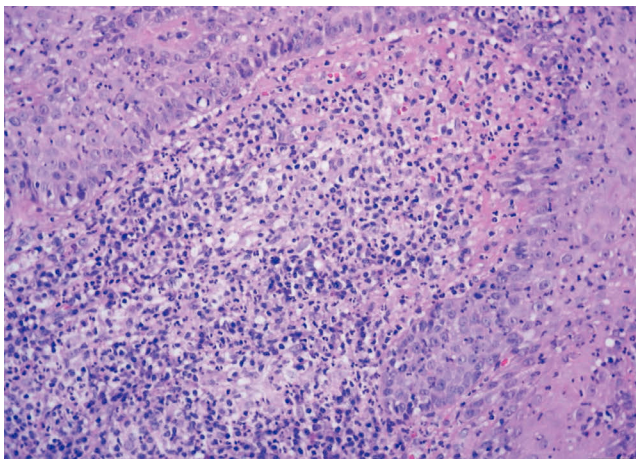


FIGURE 2: Histopathology: chronic granulomatous inflammatory process (Hematoxylin & eosin, x200)

mediators and genetic predisposition. It has been described in association with underlying systemic diseases in 50% of cases, most commonly inflammatory bowel disease, rheumatological or hematological conditions (monoclonal gammopathy, myelodysplasia, acute myeloid leukemia).⁴

Although the classic morphology comprises nodules or papules that evolve into rapidly progressive, painful ulcers with violaceous borders and a purulent base, there are many clinical variants such as ulcerative, bullous, pustular and granulomatous subtypes.⁵ Granulomatous PG can exhibit verrucous characteristics, as in the present case.

The histopathology is nonspecific and depends on the subtype of the lesion and on the duration of evolution, but it contributes to the exclusion of other diseases. There is neutrophilic infiltration in recent lesions, and necrosis associated with fibrosis in the chronic lesions, as well as a granulomatous process; however, these findings are not pathognomonic.⁵

The diagnosis is often challenging and delayed, requiring clinical and pathological correlation; hence the importance of familiarity with the differential diagnoses and morphological aspects. It should be noted that PG may be included as a differential diagnosis of the verrucous syndrome, classically recognized by the mnemonic term “PLECT” (paracoccidioidomycosis, leishmaniasis, sporotrichosis, chromomycosis, tuberculosis). Histoplasmosis should also be considered.


Negative screening investigation for systemic disease prompted us to consider the idiopathic nature of PG in our patient. Facial involvement was striking and the excellent response to both steroid and sulfonamide should be highlighted. Given the distinct verrucous aspect that granulomatous PG can present (which has long been described in the literature), could a second “P” be added to the term PLECT (pyoderma-PLECT, or PPLECT)? The reminder of this clinical form of PG by means of a well-known mnemonic tool probably results in greater diagnostic accuracy in difficult cases of the verrucous syndrome.


The most effective treatment for PG is systemic corticotherapy, which can be administered through pulse therapy for more severe cases. Other medications with antineutrophilic potential, such as dapsone and other sulfonamides, and clofazimine can also be used, as in the present case. Cyclosporin, azathioprine, and infliximab have also been employed as alternative drugs in refractory cases.⁶ □


REFERENCES


1. Brocq L. Nouvelle contribution a l'etude du phagedenisme geometrique. *Ann Dermatol Syphil.* 1916;6:1-39.
2. Brunsting LA, Goeckerman WH, O'Leary PA. Pyoderma (ecthyma) gangrenosum. *Arch Dermatol.* 1930;22:655-80.
3. Ahronowitz I, Harp J, Shinkai K. Etiology and Management of Pyoderma Gangrenosum A Comprehensive Review. *Am J Clin Dermatol.* 2012;13:191-211.
4. Braswell SF, Kostopoulos TC, Ortega-Loayza AG. Pathophysiology of pyoderma gangrenosum (PG):An updated review. *J Am Acad Dermatol.* 2015;73:691-8
5. Gameiro A, Pereira N, Cardoso JC, Gonçalo M. Pyoderma gangrenosum: challenges and solutions. *Clin Cosmet Investig Dermatol.* 2015;8:285-93.
6. Santos M, Talhari C, Rabelo RF, Schettini AP, Chirano CA, Talhari S. Pyoderma gangrenosum: a clinical manifestation of difficult diagnosis. *An Bras Dermatol.* 2011;86:153-6.

AUTHORS CONTRIBUTION

Kenselyn Oppermann  ORCID 0000-0003-0519-2868
 Approval of the final version of the manuscript; Conception and planning if the study; Elaboration and writing of the manuscript; Obtaining, analyzing and interpreting the data; Effective participation in research orientation; Intellectual participation in propaedeutic and/or therapeutic conduct of cases studied; Critical review of the literature; Critical review of the manuscript

Ariane Rubin Cocco  ORCID 0000-0002-1706-7434
 Elaboration and writing of the manuscript; Critical review of the literature; Critical review of the manuscript

Renata Heck  ORCID 0000-0003-2352-3915
 Approval of the final version of the manuscript; Effective participation in research orientation; Intellectual participation in propaedeutic and/or therapeutic conduct of cases studied

Renan Rangel Bonamigo  ORCID 0000-0003-4792-8466
 Approval of the final version of the manuscript; Conception and planning if the study; Elaboration and writing of the manuscript; Obtaining, analyzing and interpreting the data; Effective participation in research orientation; Intellectual participation in propaedeutic and/or therapeutic conduct of cases studied; Critical review of the literature; Critical review of the manuscript

How to cite this article: Oppermann K, Cocco AR, Heck R, Bonamigo RR. PLECT or PPLECT? Granulomatous pyoderma gangrenosum in the differential diagnosis of verrucous syndrome. *An Bras Dermatol.* 2018;93(4):605-7.