

## Generalized papular-purpuric eruption due to *Solenopsis fugax* bites\*

Paolo Romita<sup>1</sup>, Caterina Foti<sup>1</sup>, Mario Principato<sup>2</sup>, Luca Stingeni<sup>3</sup>

DOI: <http://dx.doi.org/10.1590/abd1806-4841.20187298>

**Abstract:** A 59-year-old atopic man referred to for the onset of a diffused itching papular-purpuric eruption involving his trunk and legs but without systemic symptoms. History revealed that he started feeling itching after spending few hours in his basement. Direct examination of the environmental dust ([www.edpa.it](http://www.edpa.it)) showed high level of infestation of *Solenopsis fugax*, a small *Myrmicinae* ant. The skin eruption completely healed without scarring in 2 weeks. Specific disinfection measures were performed and the patient did not comply of any recurrence during a 6-months follow-up.

**Keywords:** Ant venoms; Purpura; Skin diseases; Vasculitis

### INTRODUCTION

Ant bites are very common events and are frequently considered a transitory nuisance that self-heals in a few hours or days. They usually cause small erythematous, edematous, papular lesions that are centered by a tiny vesicle. However, envenomation can occasionally lead to severe reactions ranging from vasculitis to life-threatening disorders.

### CASE REPORT

A 59-year-old atopic man was referred to us in February 2016 with a severely itching papular-purpuric eruption involving his trunk and legs (Figure 1). The skin lesions were mildly infiltrated and showed a tendency to coalescence; systemic symptoms were absent. The patient denied taking drugs before the onset of the symptoms. The physical examination was unremarkable. A full laboratory panel, including autoimmune tests, coagulation tests and inflammatory markers, showed results in the normal range, except for a high D-dimer level (0.71 mg/l) and a low ANA titer (1:80). A broad viral panel was negative. A detailed clinical history revealed

that the patient started feeling the itching and burning sensations on his legs after spending a few hours in his basement where he kept his Christmas tree, a *Thuja occidentalis*. One day after spending time in his basement, the above mentioned skin lesions started to appear, so he came to the clinic. In light of this, we performed a parasitological analysis of his house (E.D.P.A.®, direct examination of the environmental dust; [www.edpa.it](http://www.edpa.it)) that showed a high level of infestation by *Solenopsis fugax* Latreille, 1798 (Hymenoptera, Formicidae) in the dust collected from his basement.<sup>1</sup> Specific disinfection measures for *Solenopsis fugax* based on cyfluthrin were performed. The skin eruptions healed completely without scarring in 2 weeks with decreasing doses of methylprednisolone (starting at 50 mg/day) and levocetirizine (5 mg/day). The patient did not complain of any recurrence during a 6-month follow-up.

### DISCUSSION

*Solenopsis fugax* is a small *Myrmicinae* ant (1.2-1.5 mm) of the *Solenopsis* genus, which is native to the British Isles (Figure 2). This

Received 17 May 2017.

Accepted 01 October 2017.

\* Work conducted at Department of Biomedical Science and Human Oncology, Dermatological Clinic, University of Bari, Bari, Italy.  
Financial support: None.  
Conflict of interests: None.

<sup>1</sup> Department of Biomedical Science and Human Oncology, University of Bari, Bari, Italy.

<sup>2</sup> Department of Veterinary Medicine, University of Perugia, Perugia, Italy.

<sup>3</sup> Clinical, Allergological and Venereological Dermatology Section, Department of Medicine, University of Perugia, Perugia, Italy.

MAILING ADDRESS:

Paolo Romita

E-mail: [romitapaolo@gmail.com](mailto:romitapaolo@gmail.com)

©2018 by Anais Brasileiros de Dermatologia



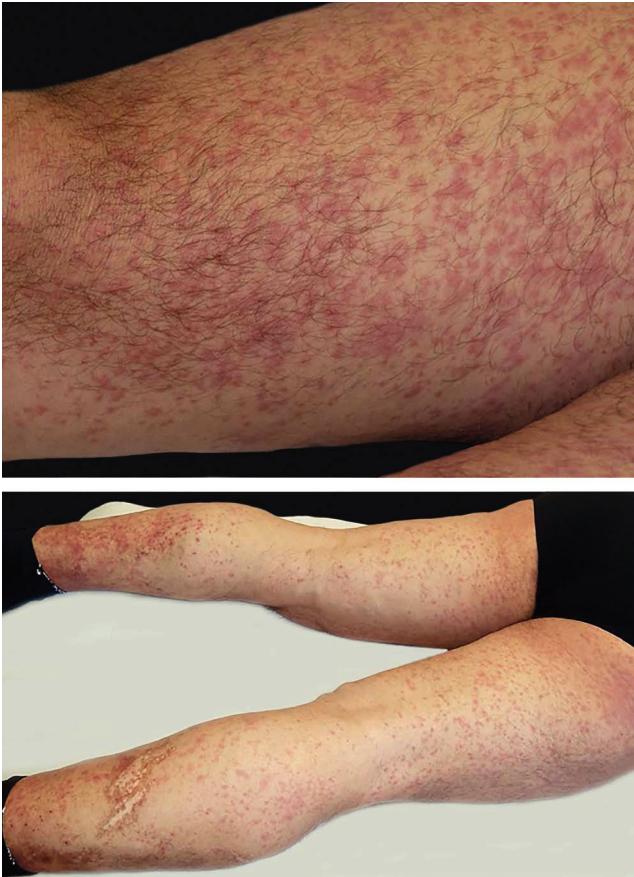

FIGURE 1: Severe itching papular-purpuric eruptions on the skin of the patient

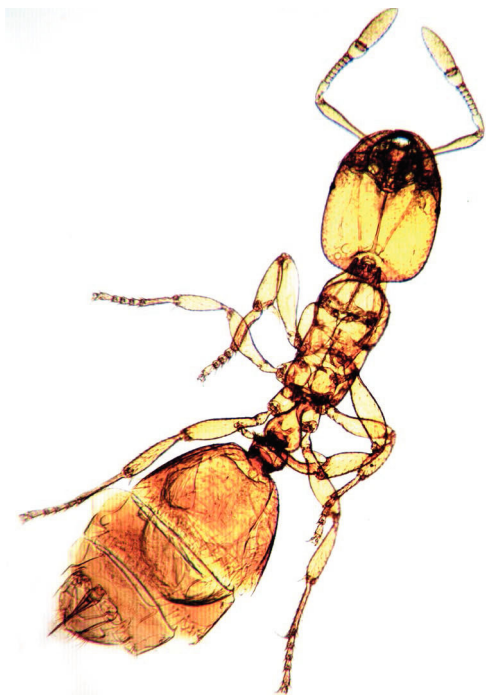


FIGURE 2: *Solenopsis fugax*

arthropod is widely present in Central and South Europe, Central Asia, Anatolia, China and North Africa.<sup>2</sup> In particular, its presence has been reported in Germany, France, Switzerland, Austria, Slovenia, Czech Republic, Poland, Slovakia, Hungary, Liechtenstein, Croatia, Romania, Serbia, Ukraine, Russia, Italy, Afghanistan, Albania, Armenia, Balearic Islands, Belarus, Belgium, Bulgaria, China, Denmark, Georgia, Gibraltar, Greece, Iran, Israel, Kazakhstan, Kyrgyzstan, Latvia, Lithuania, Luxembourg, Malta, Montenegro, Netherlands, Korea, Macedonia, Moldova, San Marino, Spain, Sweden, Turkmenistan, Great Britain and Ireland.<sup>2,3</sup> *Solenopsis fugax* colonies are enormous and composed of millions of ants that invade the countryside and gardens, where they make very shallow nests under rocks, between roots and under rotting fallen logs.<sup>4</sup> Infestations in urban houses (where the arthropod is found in cracks and fissures) are becoming increasingly frequent and are occasionally correlated with the presence of indoor plants (particularly *Cupressaceae*) and firewood. *Solenopsis fugax* urbanization is a hazard also because they can penetrate into houses due to their attraction to food debris.<sup>5</sup>


We report an unusual case of a disseminated papular-purpuric eruption due to *Solenopsis fugax* bites that had not been previously reported. In this case, our patient spent a few hours in a basement that was infested by these ants, probably due to the presence of his Christmas tree, a *Thuja occidentalis* belonging to the Cupressaceae family, which offers a suitable habitat. The diagnosis was made based on the clinical history, clinical aspect of the lesions and, most importantly, entomological identification of the insect found in the patient's house. The latter aspect plays a key role in the prognosis and differential diagnosis: it is mandatory to perform specific disinfection measures of the causative arthropod not only to avoid relapses, but also to help the physician exclude other diseases (such as vasculitis and viral or drug exanthema) that may present with similar clinical findings. The pathogenic mechanism is unknown. It could be related to a toxic mechanism due to the ant venom, which is injected from a poison gland located at the posterior end of the ant (gaster) and contains several irritating substances (including acids and alkaloids derived from piperidine).<sup>6</sup> On the other hand, a hypersensitivity mechanism cannot be excluded because other species of *Solenopsis*, such as *Solenopsis invicta*, have been described worldwide (mainly in the Asian-Pacific region) as causing immediate-type hypersensitivity reactions (small or large urticaria-like reactions and anaphylaxis) and delayed-type hypersensitivity reactions (serum sickness and vasculitis).<sup>7</sup> The most important fraction of oleaginous alkaloids secreted by poison glands is known as "solenopsin", which may trigger distant allergic reactions in atopic patients, such as a strophulus reaction. In this case, widespread eruptions (beyond the areas of bites) and the lack of a true pustulous eruption strongly suggest a hypersensitive phenomenon, as has been reported by Haddad & Larsson.<sup>8</sup> The rapid recovery after steroids and anti-histaminic also suggests an immunologic-mediated process rather than toxic envenomation. □

## REFERENCES

1. Stingeni L, Bianchi L, Hansel K, Neve D, Foti C, Corazza M, Bini V, Moretta I, Principato M. Dermatitis caused by arthropods in domestic environment: an Italian multicentre study. *J Eur Acad Dermatol Venereol*. 2017;31:1526-1533.
2. Rigato F, Toni I. Short notes. Hymenoptera, Formicidae In: Nardi G, Whitmore D, Bardiani M, Birtele D, Mason F, Spada L, et al, editors. Biodiversity of Marganai and Montimannu (Sardinia). Research in the framework of the ICP Forests network. Verona: Cierre Edizioni; 2011. p. 873-882
3. Bernard F. Les fourmis (Hymenoptera Formicidae). Paris: Masson et Cie Editeurs; 1968. p.182-183.
4. Torchote P, Sitthicharoenchai D, Chaisuekul C. Ant species diversity and community composition in three different habitats: mixed deciduous forest, teak plantation and fruit orchard. *Tropical Natural History*. 2010;10:37-51.
5. Hoffman DR. Ant venoms. *Curr Opin Allergy Clin Immunol*. 2010;10:342-6.
6. Potiwat R, Sitcharungsi R. Ant allergens and hypersensitivity reactions in response to ant stings. *Asian Pac J Allergy Immunol*. 2015;33:267-75.
7. Tankersley MS. The stinging impact of the imported fire ant. *Curr Opin Allergy Clin Immunol*. 2008 ;8:354-9.
8. Haddad Junior V, Larsson CE. Anaphylaxis caused by stings from the *Solenopsis invicta*, lavapés ant or red imported fire ant. *An Bras Dermatol*. 2015;90:22-5.


## AUTHORS CONTRIBUTION

Paolo Romita

 ORCID 0000-0002-5559-9722


Statistical analysis; Approval of the final version of the manuscript; Conception and planning of the study; Elaboration and writing of the manuscript; Obtaining, analyzing and interpreting the data; Effective participation in research orientation; Intellectual participation in propaedeutic and/or therapeutic conduct of the cases studied; Critical review of the literature; Critical review of the manuscript

Caterina Foti

 ORCID 0000-0001-6196-9788


Approval of the final version of the manuscript; Obtaining, analyzing and interpreting the data; Intellectual participation in the propaedeutic and/or therapeutic conduct of the cases studied; Critical review of the literature; Critical review of the manuscript

Mario Principato

 ORCID 0000-0002-2741-038X

Obtaining, analyzing and interpreting data; Effective participation in research orientation; Intellectual participation in propaedeutic and/or therapeutic conduct of the cases studied

Luca Stingeni

 ORCID 0000-0001-7919-8141

Approval of the final version of the manuscript; Conception and planning of the study; Obtaining, analyzing and interpreting the data; Critical review of literature; Critical review of the manuscript

**How to cite this article:** Romita P, Foti C, Principato M, Stingeni L. Generalized papular-purpuric eruption due to *Solenopsis fugax* bites. *An Bras Dermatol*. 2018;93(4):570-2.