

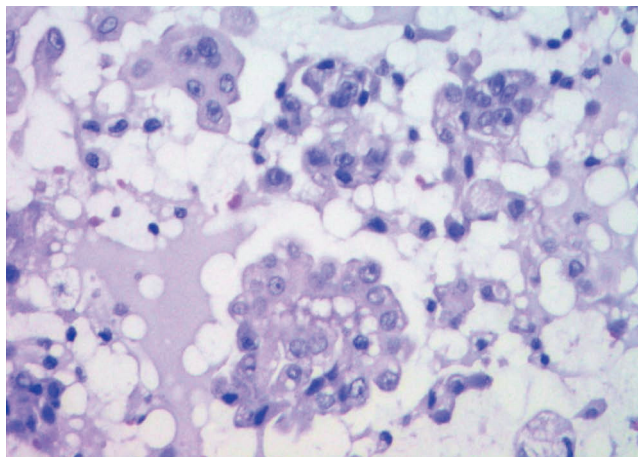FIGURE 3: Histopathological: transverse section (Hematoxylin & eosin, X400)

Malignant transformation is very rare. Five cases of ductal carcinoma *in situ* arising within a pre-existing hidradenoma papilliferum have been documented, and two cases have reported invasive carcinomas arising from HP (malignant perianal papillary hidradenoma and vulvar adenosquamous carcinoma).⁵

The treatment of choice for ectopic HP is complete excision of the tumor,⁴ as in the present case, and recurrence is typically attributed to incomplete excision.^{1,4} □


REFERENCES

1. Tanaka M, Shimizu S. Hidradenoma papilliferum occurring on the chest of a man. *J Am Acad Dermatol*. 2003;48:S20-1.
2. Virgili A, Marzola A, Corazza M. Vulvar Hidradenoma Papilliferum. A review of 10.5-year's experience. *J Reprod Med*. 2000 ;45:616-8.
3. Handa Y, Yamanaka N, Inagaki H, Tomita Y. Large Ulcerated Perianal Hidradenoma Papilliferum in a Young Female. *Dermatol Surg*. 2003;29:790-2.
4. Kim YJ, Lee JW, Choi SJ, Kim SJ, Kim YJ, Jeon YS, ET AL. Ectopic Hidradenoma Papilliferum of the Breast: Ultrasound Finding. *J Breast Cancer*. 2011;14:153-5.
5. Theodosiou G, Zafeiriadou V, Papageorgiou M, Mandekou-Lefaki I. An unusual lesion in the right place. *Dermatol Pract Concept*. 2016;6:7-9.


Rogério Nabor Kondo

 ORCID 0000-0003-1848-3314


Isabela Peron Melhado

 ORCID 0000-0003-2107-4482

Cassio Rafael Moreira

 ORCID 0000-0002-8781-1505

Jefferson Crespigio

 ORCID 0000-0002-2842-9349

Chromoblastomycosis due to *Cladosporium langeronii*. Molecular diagnosis of an agent previously diagnosed as *Fonsecaea pedrosoi**

Edoardo Torres-Guerrero¹

Roberto Arenas¹

Rigoberto Hernández Castro²

DOI: <http://dx.doi.org/10.1590/abd1806-4841.20187644>

Dear Editor,

Chromoblastomycosis is a chronic, progressive, subcutaneous mycosis caused by dematiaceous (black) fungi clinically characterized by warty nodular lesions, generally on lower limbs but any region can be involved. The etiological agents mainly belong to three genera: *Fonsecaea*, *Phialophora* and *Cladophialophora* (*Cladosporium*). All of these pathogens are characterized by parasitic structures known as fumagoid cells or Medlar bodies. Most of affected individuals are rural workers who have a history of local trauma with decaying plant debris and frequently wear inadequate footwear, such as sandals. In 2010, we published a clinical case regarding a patient with squamous cell carcinoma secondary to longstanding lesions of chromoblastomycosis, who died due to multiorgan failure with hydroelectrolytic imbalance.¹ Based on phenotypic fungal characteristics, the culture had been previously identified as *Fonsecaea pedrosoi*. The culture was stored and now, ten years after the case release, we carried out polymerase chain reaction (PCR) amplification and sequencing of internal transcribed spacer (ITS) and ribosomal DNA (rDNA; Figures 1 and 2).² The 550 bp PCR product was purified, sequenced in both directions and submitted to the BLAST database at NCBI. The sequence showed a 100% homology with *Cladosporium langeronii* DTO-124-D5, R1, CBS189.54, among others (Figure 3).

In 2006, Zalar *et al.* described *C. langeronii*, along with seven new species sampled from a variety of substrates, as species related to the ubiquitous *Cladosporium sphaerospermum*. This description and phylogenetic analysis was based on the amplification and sequence

Received 14 September 2017.

Accepted 06 November 2017.

* Work conducted at the Mycology Service and Ecology of Pathogen Agents Sector, Hospital "Dr. Manuel Gea González", Ciudad del Mexico, Mexico.

Financial support: None.

Conflict of interests: None.

¹ Mycology Service - Hospital "Dr. Manuel Gea González", Ciudad del Mexico, Mexico.

² Research Department, Ecology of Pathogen Agents Sector - Hospital "Dr. Manuel Gea González", Ciudad del Mexico, Mexico.

MAILING ADDRESS:

Edoardo Torres Guerrero

E-mail: drlalo2005@hotmail.com

©2018 by Anais Brasileiros de Dermatologia

How to cite this article: Kondo RN, Melhado IP, Moreira CR, Crespigio J. Ectopic hidradenoma papilliferum. *An Bras Dermatol*. 2018;93(3):474-5.

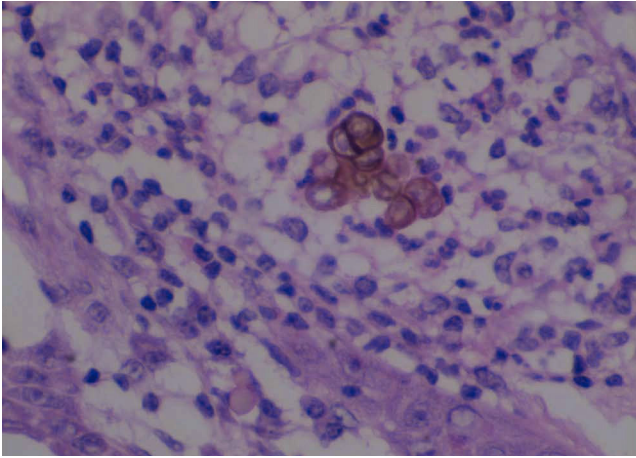


FIGURE 1: Chromoblastomycosis. Medlar bodies (Hematoxylin & eosin, X40)

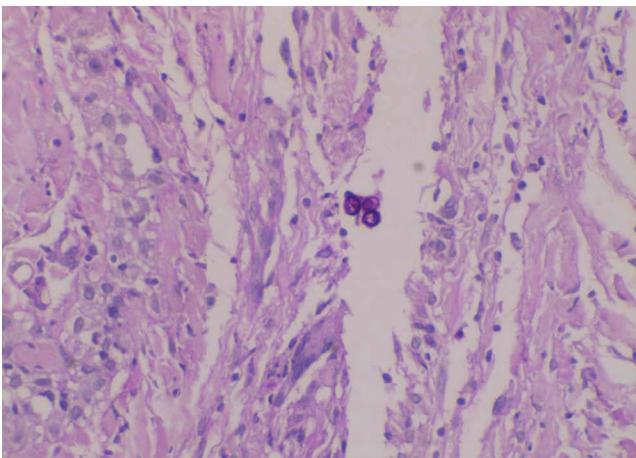


FIGURE 2: Chromoblastomycosis. Medlar bodies (PAS, X10)

of the rDNA-ITS region.³ *Cladosporium* species are particularly distinguished by their strikingly slow-growing colonies in potato dextrose agar, malt extract agar and oat agar at 25°C in the dark with a maximum salt concentration of 17%. *Cladosporium* develop dark-brown smooth oblong conidia with light ornamentations (minutely verruculose spores) and scarce secondary ramoconidia.⁴ *Cladosporium* are ubiquitous without any apparent predilection for a specific environment. Its habitat comprises polar ice, decomposing plant matter, window frames, nasal mucus, and more recently, water from the Caspian Sea.⁵ Clinical cases are suspected to be accidental as a consequence of traumatism involving contaminated materials.

The classical identification based on macroscopic and microscopic characteristics provides a weak diagnosis. Currently, molecular techniques based on the rDNA-ITS region of *Cladosporium* allow more precise species identification. Thus, we communicate the molecular confirmation *C. langeronii* as the causative agent of the 2007 clinical case. So far, only three sequences of *C. langeronii* rDNA-ITS have been reported associated with human cases. The first sequence, CBS189.54 NT (access number DQ780379), is associated with mycosis in Brazil, while the other two sequences (access

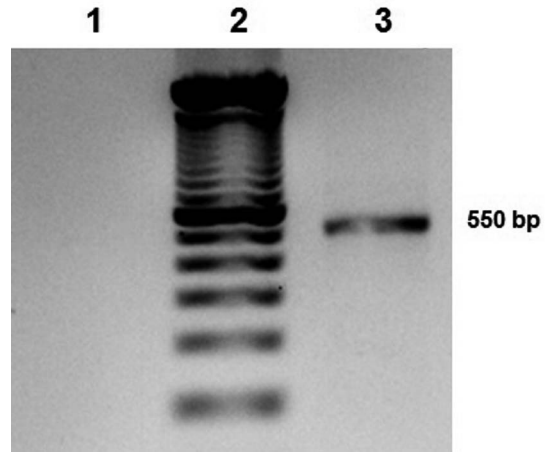



FIGURE 3: PCR amplification of the rDNA-ITS region: 1) Negative control; 2) Molecular weight marker 100bp ladder; and 3) *C. langeronii* isolate

numbers AF4555254 and AY3453524) are related to nasal mucosa.³ We believe communicating the molecular confirmation of a human disease caused by this extremely rare agent is important. □

REFERENCES

1. Torres E, Beristain JG, Lievanos Z, Arenas R. Chromoblastomycosis associated with a lethal squamous cell carcinoma. *An Bras Dermatol.* 2010;85:267-70.
2. Korabecná M, Liska V, Fajfrlík K. Primers ITS1, ITS2 and ITS4 detect the intraspecies variability in the internal transcribed spacers and 5.8S rRNA gene region in clinical isolates of fungi. *Folia Microbiol (Praha).* 2003;48:233-8.
3. Zalar P, de Hoog GS, Schroers HJ, Crous PW, Groenewald JZ, Gunde-Cimerman N. Phylogeny and ecology of the ubiquitous saprobe *Cladosporium sphaerospermum*, with descriptions of seven new species from hypersaline environments. *Stud Mycol.* 2007;58:157-83.
4. de Hoog GS, Guarro J, Gené J, Figueras MJ. *Atlas of clinical fungi.* 2nd ed. Spain: Centraalbureau voor Schimmelcultures/ Universitat Rovira e Virgili; 2000. p.582.
5. Sadati R, Barghi A, Abbasi Larki R. Isolation and screening of lipolytic fungi from coastal waters of the Southern Caspian sea (North of Iran). *Jundishapur J Microbiol.* 2015;8:e16426.

Edoardo Torres-Guerrero	 ORCID 0000-0003-2394-2730
Roberto Arenas	 ORCID 0000-0002-2992-9564
Rigoberto Hernández Castro	 ORCID 0000-0002-5656-0942

How to cite this article: Torres-Guerrero E, Arenas R, Hernández-Castro R. Chromoblastomycosis due to *Cladosporium langeronii*. Molecular diagnosis of an agent previously diagnosed as *Fonsecaea pedrosoi*. *An Bras Dermatol.* 2018;93(3):475-6.