

Figurate erythematous lesion by *Microsporium canis* in immunosuppressed patient*

Karine Paschoal Botelho¹
Deborah Pereira Gonçalves^{2,3}

Yuri Coelho Soares¹
Bárbara Lima Araújo Melo¹

DOI: <http://dx.doi.org/10.1590/abd1806-4841.20187094>

Abstract: Dermatophytes are fungi capable of invading keratinized tissues. Isolation of the fungus with the culture is essential to guide the treatment, because there are more resistant species like *Microsporium canis*. The chronic use of corticosteroids leads to the deregulation of immunity, promoting atypical manifestations of infections. Topical antifungal therapy is often insufficient, requiring systemic medications. We describe the case of a patient undergoing systemic corticosteroid therapy with a large figurate lesion who presented complete response to exclusively topical treatment.

Keywords: Immunosuppression; Mycology; Tinea

A 39-year-old female patient with systemic lupus erythematosus, on prolonged use of prednisone 40mg/day and hydroxychloroquine 400mg/day, for two months, presented with a round plaque with well-defined borders and extremely figurate center, with areas of scaling and of healthy skin of approximately 10cm in diameter (Figure 1). The direct microscopic examination septate hyaline hyphae; the culture was positive with a white filamentous aspect and a yolk

yellow reverse. The microculture showed fusiform macroconidia with more than six cellular divisions, confirming infection by *M. canis* (Figures 2 and 3). The patient was treated with isoconazole 1% associated to diflucortolone 1% cream for the first 10 days. For the following 20 days, she used isoconazole 1% cream alone, with a complete response to exclusively topical therapy (Figure 4).

The dermatophytes comprise 3 genera of fungi capable of invading keratinized tissues: *Trichophyton*, *Microsporium*, *Epidermo-*

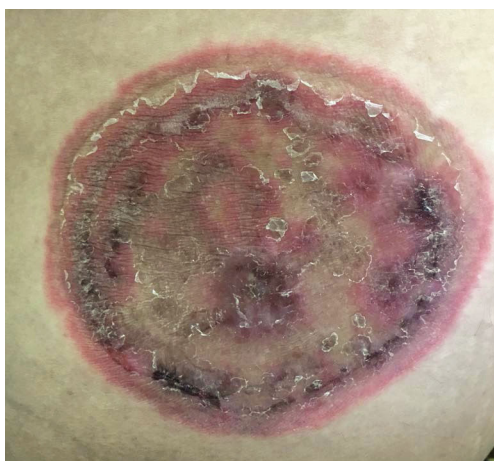

FIGURE 1: Round plaque with well-defined borders and figurate center

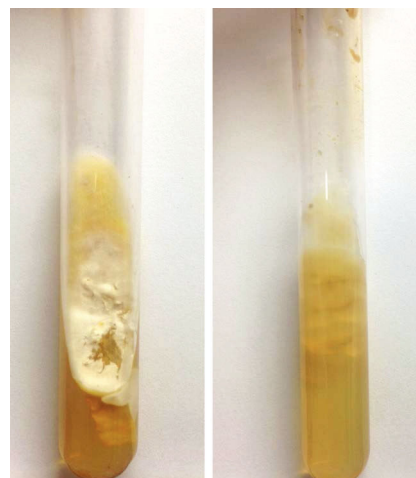


FIGURE 2: White, wooly colony with yolk-yellow reverse

Received on 21.03.2017.

Approved by the Advisory Board and accepted for publication on 20.11.2017.

* Study conducted at Centro de Dermatologia Dona Libânia - Fortaleza (CE), Brazil.

Financial support: None.

Conflict of interest: None.

¹ Outpatient Department of General Dermatology, Centro de Dermatologia Dona Libânia - Fortaleza (CE), Brazil.

² Department of Rheumatology, Hospital Universitário Walter Cantídio - Universidade Federal do Ceará (HUWC-UFC) - Fortaleza (CE), Brazil.

³ Department of Rheumatology, Hospital Geral Dr. César Cals (HGCC) - Fortaleza (CE), Brazil.

MAILING ADDRESS:

Yuri Coelho Soares

E-mail: yuri_coelho@hotmail.com

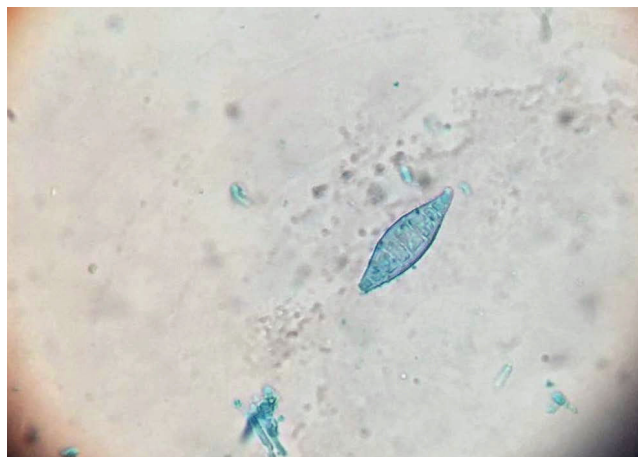


FIGURE 3: Micromorphology with fusiform macroconidia with more than 6 cellular divisions

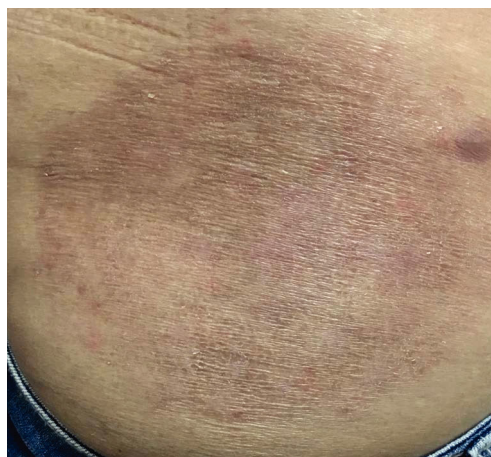

FIGURE 4: Lesion after treatment

phyton. Non-specific, cellular and humoral immunologic responses act in an attempt to block infection in the host.¹

Chronic use of corticosteroids causes a deregulation mainly of cellular immunity. Its anti-inflammatory properties mask signs and symptoms of an infection, leading to atypical manifestations such as lesions that are asymptomatic, have a widespread or even figurate distribution, mimicking other conditions such as observed in this case.²⁻⁴

Thus, immunosuppressed patients due to corticotherapy have higher risk of opportunistic infections. The isolation of the fungus in a culture is essential to guide treatment, because there are more resistant as *M.canis* in immunosuppressed patients.⁵ Topical antifungal therapy alone is usually insufficient, and systemic antifungal are commonly required.⁶ □

REFERENCES

1. Zaitz C. Dermatofitoses. In: Campbell I, Marques SA, Ruiz LRB, Framil VMS. Compêndio de Micologia Médica. 2. ed. Rio de Janeiro: Guanabara Koogan; 2010. p. 157-67.
2. Lionakis MS, Kontoyiannis DP. Glucocorticoids and invasive fungal infections. Lancet. 2003;362:1828-38.
3. Peixoto I, Maquine G, Francesconi VA, Francesconi F. Dermatofitose por *Tricophyton rubrum* como infecção oportunista em pacientes com doença de Cushing. An Bras Dermatol. 2010;85:888-90.
4. Venkatesan P, Perfect JR, Myers SA. Evaluation and management of Fungal infections in Immunocompromised patients. Dermatol Ther. 2005;18:44-57.
5. King D, Cheever LW, Hood A, Horn TD, Rinaldi MG, Merz WG. Primary invasive cutaneous *Microsporium canis* infections in immunocompromised patients. J Clin Microbiol. 1996;34:460-2.
6. Elewski BE, Sullivan J. Dermatophytes as opportunistic pathogens. J Am Acad Dermatol. 1994;30:1021-2.

How to cite this article: Botelho KP, Soares YC, Gonçalves DP, Melo BLA. Figurate lesion by *Microsporium canis* in immunosuppressed patient. An Bras Dermatol. 2018;93(1):141-2.