

Japanese family with haemorrhagic Darier disease clinically mimicking epidermolysis bullosa simplex with mottled pigmentation. *Br J Dermatol.* 2007;157:605–8.

4. Zhang J, Li M, Yao Z. Updated review of genetic reticulate pigmentary disorders. *Br J Dermatol.* 2017;177:945–59.
5. Alves ACF, Machado MCMR, Cymbalista NC, Oliveira ZNP, Sotto MN, Prianti MG, et al. Immunomapping in the diagnosis of hereditary epidermolysis bullosa dystrophica. *An Bras Dermatol.* 2001;76:551–60.

Flávia Regina Ferreira *, Carolina Fernandes Pereira ,
Juliana Carvalho Moretto , Mariana Patriota Naville 

Dermatology Service, Hospital Universitário de Taubaté, Taubaté, SP, Brazil

* Corresponding author.

E-mail: dermagica@uol.com.br (F.R. Ferreira).

Received 1 May 2019; accepted 20 August 2019

Available online 14 May 2020

<https://doi.org/10.1016/j.abd.2019.08.033>

0365-0596/ © 2020 Sociedade Brasileira de Dermatologia.

Published by Elsevier España, S.L.U. This is an open access article under the CC BY license (<http://creativecommons.org/licenses/by/4.0/>).

Rare presentation of Rothmund-Thomson syndrome with novel compound heterozygous mutations of the RECQL4 gene^{☆☆}



Dear Editor,

Rothmund-Thomson syndrome (RTS) is a rare autosomal recessive disorder that is characterized by facial rash (poikiloderma, a diagnostic hallmark), growth retardation, sparse scalp hair/eyelashes/eyebrows, juvenile cataracts, skeletal abnormalities, radial ray defects, and a predisposition to cancer. There are two clinical forms: type I, which is characterized by poikiloderma, ectodermal dysplasia, and juvenile cataracts with unknown etiology, and type II which is characterized by poikiloderma, congenital bone defects, an increased frequency of malignancy (especially osteosarcoma), and RECQL4 (8q24.3) mutation.¹ To date, around 400 cases have been reported.

Here, the authors report a case of poikiloderma and growth retardation in a Chinese girl presenting two RECQL4 mutations in a novel, compound heterozygous arrangement (c.2492_2493del and c.1391-2A>C) recorded *via* mutational screening, which is the first reported in RTS.

The proband is a 2-year-old girl with poikiloderma bilaterally on her face and ears. Her parents complained that their younger daughter showed erythema, swelling, and blistering bilaterally on her face since the age of 6 months, which gradually developed to reticulated hypo- and hyperpigmentation. The girl also presented with thinning of eyebrows, photosensitivity, and gastrointestinal problems including chronic emesis or diarrhea. Neither her parents nor her 5-year-old sister has similar symptoms. The patient was born at full term with a mild toe abnormality. However, slow weight gain, short stature, and teeth retardation were noted on a physical examination. The dermatological examination found bilateral depigmentation, hyperpigmentation,

punctate atrophy, and telangiectasia over the patient's face and ears (Fig. 1). Bone mineral density measurement was performed at 1 year of age, which showed low bone mineral density. Her cognitive ability, ophthalmic testing, and other examination results were within normal limits and no other alterations were found.

For differential molecular diagnosis of poikiloderma, targeted exome sequencing was performed. Mutational screening for BLM, the defective gene in Bloom's syndrome and other poikiloderma-related diseases, was negative. Gene sequencing revealed two distinct heterozygous mutations on the RECQL4 gene (Fig. 2). One of them is a point mutation located in exon 9, consisting of a change of adenine for cytosine (c.1391-2A>C), which was found in her unaffected father and sister. This mutation has not been reported, but the possible effect on the protein through a splice acceptor variant can be assumed. On the other allele, the mutation is a deletion of two nucleotides found in exon 16 (c.2492_2493delAT), which produces a frame shift (p.His831Argfs); this mutation is known to be rare and last evaluated by Kitao et al.² This mutation was found in her unaffected mother. These two mutations of the proband respectively come from her father and mother, known as compound heterozygous mutations, and accord with the autosomal recessive inheritance law. Her sister only presents c.1391-2A>C, which is a heterozygous mutation and, theoretically, she won't show any symptoms.

The patient reported here has the clinical signs like poikiloderma, sparse eyebrows, small stature, dental abnormality, and mild skeletal abnormality, which are mentioned in the previous articles.^{3,4} No cataracts and cancer have been found so far. Unlike other previous cases, the lesion doesn't affect her extremities, and the authors consider that she is too young to show all the symptoms. RTS was diagnosed according to typical lesion and mutation of RECQL4 gene, and the patient was advised to avoid sun exposure and undergo annual checkups for the eyes, skin, and bones.

The novels compound heterozygous RECQL4 mutations presented in this patient is the first reported in RTS. Loss of RECQL4 protein function occurs in approximately two-thirds of RTS patients and is associated with risk of osteosarcoma.⁵ Further functional studies to confirm the protein-damaging effect are needed to proceed. Poikiloderma is a symptom of many systemic diseases, such as lupus erythematosus, Bloom

[☆] How to cite this article: Zhang X, Geng S, Zheng Y. Rare presentation of Rothmund-Thomson syndrome with novel compound heterozygous mutations of the RECQL4 gene. *An Bras Dermatol.* 2020;95:538-40.

^{☆☆} Study conducted at the Department of Dermatology, Second Affiliated Hospital, Xi'an Jiaotong University, Shaanxi, China.

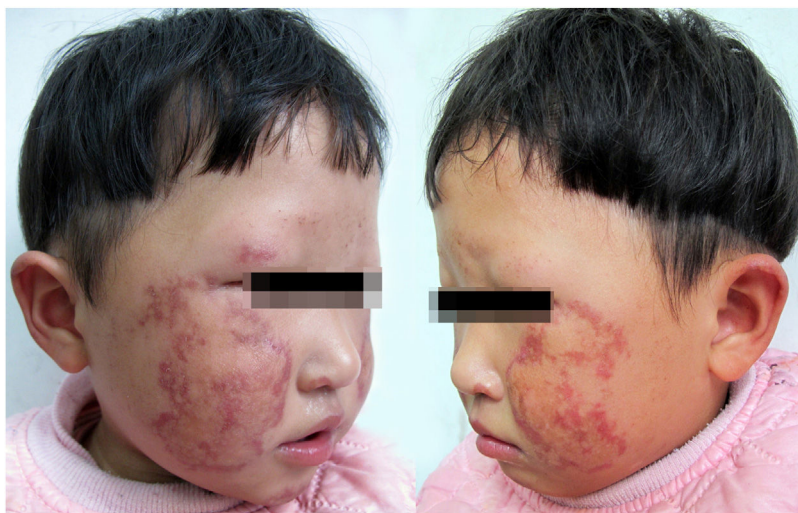

Figure 1 Poikiloderma in a patient with RTS. Depigmentation, hyperpigmentation, punctate atrophy, telangiectasia, and loss of eyebrows are seen bilaterally on the face.

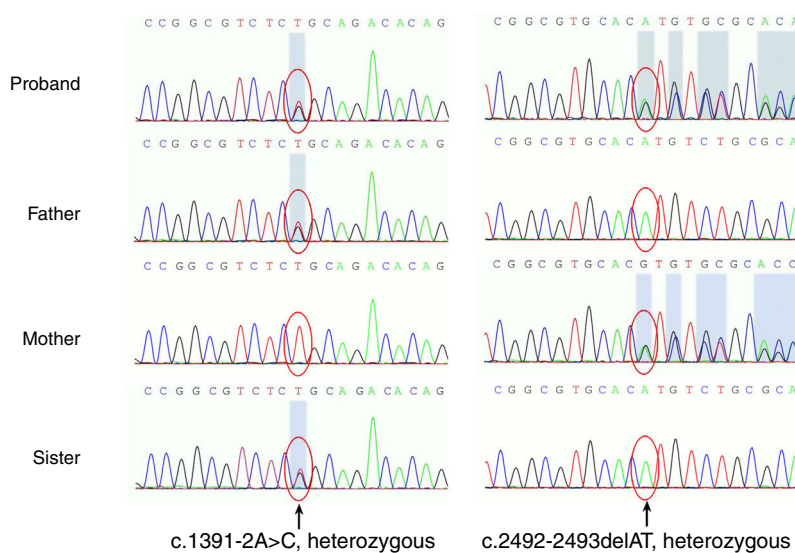


Figure 2 Two novel heterozygous variants in the RECQL4 gene confirmed by gene sequencing. One was in the splice site, c.1391-2A>C from her father, and also was seen in her sister. The other was a deletion mutation, c.2492_2493delAT (p.His831Argfs) from her mother.

syndrome, Kindler syndrome, and dyskeratosis congenita. The result of genetic testing is instructive and meaningful to a definitive diagnosis and future procreation guidance for the patient's family.

Financial support

None declared.

Authors' contributions

Xinyue Zhang: Drafting and editing of the manuscript.

Songmei Geng: Approval of final version of the manuscript; intellectual participation in the propaedeutic and/or therapeutic conduct of the studied cases.

Yi Zheng: Critical review of the literature.

Conflicts of interest

None declared.

References

- Larizza L, Roversi G, Volpi L. Rothmund-Thomson syndrome. *Orphanet J Rare Dis.* 2010;5:2.
- van Rij MC, Grijzen ML, Appelman-Dijkstra NM, Hansson KB, Ruivenkamp CA, Mulder K, et al. Rothmund-Thomson syndrome and osteoma cutis in a patient previously diagnosed as COPS syndrome. *Eur J Pediatr.* 2017;176:279–83.
- Larizza L, Roversi G, Verloes A. Clinical utility gene card for: Rothmund-Thomson syndrome. *Eur J Hum Genet.* 2013;21:7.

- Yang JY, Sohn YB, Lee JS, Jang JH, Lee ES. Rare presentation of Rothmund-Thomson syndrome with predominantly cutaneous findings. *JAAD Case Rep.* 2017;3:172–4.
- Siiitonen HA, Sotkasiira J, Biervliet M, Benmansour A, Capri Y, Cormier-Daire V, et al. The mutation spectrum in RECQL4 diseases. *Eur J Hum Genet.* 2009;17:151–8.

Xinyue Zhang , Songmei Geng *, Yi Zheng 

Department of Dermatology, Second Affiliated Hospital, Xi'an Jiaotong University, Shaanxi, China

* Corresponding author.

E-mail: gsm312@yahoo.com (S. Geng).

Received 12 January 2019; accepted 4 October 2019
Available online 14 May 2020

<https://doi.org/10.1016/j.abd.2019.10.006>

0365-0596/ © 2020 Sociedade Brasileira de Dermatologia.

Published by Elsevier España, S.L.U. This is an open access article under the CC BY license (<http://creativecommons.org/licenses/by/4.0/>).

Acute generalized exanthematous pustulosis with features mimicking toxic epidermal necrolysis secondary to amiodarone^{☆,☆☆}



Dear Editor,

Acute generalized exanthematous pustulosis (AGEP) is an infrequent cutaneous drug eruption, with a short latency of 24–48 h between the exposure and the onset of lesions.^{1,2} The symptoms consist of fever and small, sterile, non-follicular pustules on a background of erythema.^{1,2} Mucous membrane and internal organ involvement are unusual.^{1,2} The most common laboratory abnormality is leukocytosis and neutrophilia >7000/mL.² A score, developed by the EuroSCAR group, that takes into account clinical and histopathological criteria is useful for diagnosis.^{1,2} AGEP is usually a self-limited disease, which typically resolves with cutaneous desquamation in less than 15 days after suspending the causative drug, and it has an excellent prognosis.² However, although infrequent, patients can develop purpuric, targetoid, and bullous lesions, areas of denuded skin, a positive Nikolsky sign, and mucosal and multi-organ involvements, which denotes a more serious outcome.³ The present report describes a patient with AGEP induced by an atypical drug, who presented with this serious clinical picture.

A 69-year-old female patient, with a history of supraventricular extrasystoles, presented with fever, malaise, and small, non-follicular pustules on a background of erythema in the axillae and groin. Twenty-four hours earlier she had switched her antiarrhythmic treatment from bisoprolol to amiodarone. Upon admission, she was dyspneic and presented tachycardia, tachypnea, and suboptimal oxygen saturation. Her mucous membranes were not involved and the Nikolsky sign was negative. Her laboratory studies revealed leukocytosis (26,689 cell/mm³) with neutrophilia (88.25%). Blood cultures showed no growth and the chest X-ray did not reveal any abnormalities. AGEP was suspected,

amiodarone was suspended, skin biopsies were obtained, and oral meprednisone 0.5 mg/kg/day was started because of her pulmonary symptoms. Histopathology revealed subcorneal pustules with no necrotic keratinocytes (Fig. 1). The EuroSCAR score was 11, compatible with definite AGEP. In spite of the initial treatment, 24 h later the patient's lesions evolved and extended. She experienced diarrhea and developed purpuric and targetoid lesions in the thighs and the gluteal area (Fig. 2); and bullous lesions that led to small erosions on her flanks (Fig. 3). Nikolsky sign was again negative. Taking into account this torpid progression, it was hypothesized that intestinal absorption of corticosteroid could not have been sufficient, the prolonged half-life of amiodarone was playing a role, and the patient could have been undergoing a different drug reaction such as toxic epidermal necrolysis (TEN) or that she could have been suffering from an overlapping of two adverse drug reactions. At this point new skin biopsies were obtained. The histopathology was again compatible with AGEP. Meprednisone dose was raised to 1 mg/kg/day and was administered intravenously. Finally, the skin lesions and systemic symptoms resolved with skin desquamation 11 days after the onset. However, after

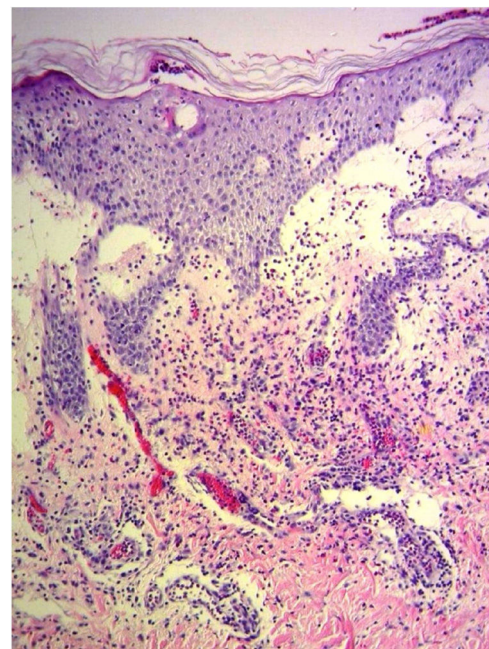


Figure 1 Subcorneal pustules and spongiosis (Hematoxylin & eosin, x100).

[☆] How to cite this article: Distel C, Bollea-Garlatti ML, Torre AC, Riganti J. Acute generalized exanthematous pustulosis with features mimicking toxic epidermal necrolysis secondary to amiodarone. *An Bras Dermatol.* 2020;95:540–2.

^{☆☆} Study conducted at the Hospital Italiano de Buenos Aires, Buenos Aires, Argentina.