

2. Stiube A, Jenni D, Wiederkehr L, Anzengruber F, Nobbe S. Terra firme-forme dermatosis diagnostic sign and treatment: a case report. *Case Rep Dermatol*. 2019;11:108–12.
3. Vakirlis E, Theodosiou G, Lallas A, Apalla Z, Sotiriou E. Terra firma-forme dermatosis: differential diagnosis and response to salicylic acid therapy. *Pediatr Dermatol*. 2019;00:1–4.
4. Sasaya EMK, Ghislandi C, Trevisan F, Ribeiro TO, Mulinari-Brenner F, Gaiowski CB. Dermatitis neglecta. *An Bras Dermatol*. 2015;90(S1):58–60.
5. National Center for Biotechnology Information. PubChem Compound Database [Internet]. US: National Library of Medicine. Available from: <https://pubchem.ncbi.nlm.nih.gov/compound/3776> [cited 16.02.19].

Bruna Anjos Badaró *, Lucia Martins Diniz , Paulo Sergio Emerich Nogueira 

Service of Dermatology, Hospital Universitário Cassiano Antônio Moraes, Universidade Federal do Espírito Santo, Vitória, ES, Brazil

* Corresponding author.

E-mail: brunaanjosbadaro@hotmail.com (B.A. Badaró).

Received 28 February 2019; accepted 17 July 2019

Available online 20 March 2020

<https://doi.org/10.1016/j.abd.2019.07.013>

0365-0596/ © 2020 Sociedade Brasileira de Dermatologia.

Published by Elsevier España, S.L.U. This is an open access article under the CC BY license (<http://creativecommons.org/licenses/by/4.0/>).

Inflammatory segmental vitiligo during oral isotretinoin use: a casual association? ☆☆☆



Dear Editor,

Segmental vitiligo (SV) accounts for 3–20% of all cases of vitiligo and is usually not associated with autoimmune diseases when compared to non-segmental vitiligo (NSV).¹ Among the theories proposed for the pathophysiology of SV, it is essential to emphasize the presence of an autoimmune attack against a mosaic area.¹

In the literature, there are few reports on the emergence of vitiligo as a side effect of medications, especially oral isotretinoin. The objective of the present report is to demonstrate a possible new side effect of this medication since there are no descriptions of its association with SV in the literature.

A 17 year-old male patient, previously healthy and without a family history of vitiligo, was diagnosed with resistant acne, previously treated with topical and systemic antibiotic therapy. During the fifth month of treatment with oral isotretinoin (0.4 mg/kg/day, cumulative dose of 5.400 mg), there were a chromic spots surrounded by an erythematous-scaling halo in malar and perioral areas, not exceeding the mid line on the right side of the face (Fig. 1). Wood's light examination revealed fluorescent chalky white aspect, as well as polios is in beard hair (Fig. 2) favoring the SV diagnosis. After the withdrawal of isotretinoin, the patient began treatment with 0.1% tacrolimus ointment twice daily with an improvement of perilesional erythema after two months, although without improvement of achromy. Subsequently, it was submitted to 20 sessions of UVB-NB phototherapy, with little perifollicular pigmentation.

In the literature review, only three cases of vitiligo in the context of oral isotretinoin use are described. One report

describes the case of a patient who developed vitiligo during the use of oral isotretinoin at a dose of 0.3–0.4 mg/kg/day for the treatment of moderate to severe acne.² In another report, acrofacial vitiligo was developed only two months after the end of treatment with isotretinoin, which reduces the probability of a cause-and-effect relationship.³ There is also a report of worsening of NSV lesions in the lower lip and lower perioral region after chronic cheilitis due to the use of oral isotretinoin; a condition attributed in this case to the Koebner phenomenon.⁴

The mechanism of action of isotretinoin in this presumed association is not yet fully elucidated, but the drug appears to play a role in triggering autoimmunity in genetically susceptible individuals.⁵ Several reports of autoimmune diseases such as diabetes, autoimmune hepatitis, Guillain-Barré syndrome, and thyroiditis have been reported after the end of the isotretinoin regimen or during the last week of treatment.⁵ Besides, in vitro studies have also demonstrated that retinoid may have a pro-apoptotic effect on melanocytes.³

Although the cause-effect relationship of this association has not yet been proven, the increasing appearance of new cases in the literature is a warning sign for dermatologists to keep vigil on this possible new side effect.

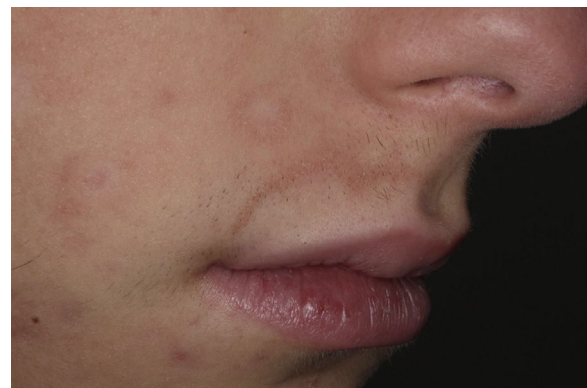

Figure 1 Achromic spots surrounded by halo erythematous and polios is in beard hairs in the malar and right perioral regions.

☆ How to cite this article: Avelar-Caggiano MFS, Castro CCS, Delatorre G. Inflammatory segmental vitiligo during oral isotretinoin use: a casual association? *An Bras Dermatol*. 2020;95:399–400.

☆☆ Study conducted at the Hospital Santa Casa de Misericórdia de Curitiba, Paraná, PR, Brazil.




Figure 2 Wood's light examination revealed fluorescence bright blue-white in malar and perioral right regions.

Financial support

None declared.

Authors' contributions

Maria Fernanda de Santana Avelar-Caggiano: Conception and planning of the study; elaboration and writing of the manuscript; obtaining, analysis, and interpretation of the data; critical review of the literature.

Caio César Silva de Castro: Approval of the final version of the manuscript; effective participation in research orientation; intellectual participation in the propaedeutic and/or therapeutic conduct of the studied cases; critical review of the manuscript.

Gerson Dellatorre: Approval of the final version of the manuscript; effective participation in research orientation; intellectual participation in the propaedeutic and/or therapeutic conduct of the studied cases; critical review of the manuscript.

Conflicts of interest

None declared.

References

1. VanGeel N, Mollet I, Brochez L, Dutré M, De Schepper S, Verhaeghe E, et al. New insights in segmental vitiligo: case report and review of theories. *Br J Dermatol.* 2011;166:240–6.
2. Rao PK, Bhat RM, Nandakishore B, Dandakeri S, Martis J, Kamath GH. Safety and efficacy of low-dose isotretinoin in the treatment of moderate to severe acne vulgaris. *Indian J Dermatol.* 2014;59:316.
3. Kokandi AA. Vitiligo appearing after oral isotretinoin therapy for acne. *Case Rep Dermatol Med.* 2018;2018:1–3.
4. Garner ML, McShane DB, Burkhart CN, Morrell DS. Isotretinoin and vitiligo: can chronic cheilitis cause koebnerization? *Pediatr Dermatol.* 2015;32:108–9.
5. Nugroho J, Schweiger B. Isotretinoin as a possible environmental trigger to autoimmunity in genetically susceptible patients. *Case Rep Pediatr.* 2017;2017:1–3.

Maria Fernanda de Santana Avelar-Caggiano ^{a,*},
Caio César Silva de Castro ^b, Gerson Dellatorre ^a

^a Service of Dermatology, Hospital Santa Casa de Misericórdia de Curitiba, Curitiba, PR, Brazil

^b Medical School, Pontifícia Universidade Católica do Paraná, Curitiba, PR, Brazil

* Corresponding author.

E-mail: mafe_avelar@yahoo.com.br (M.F. Avelar-Caggiano).

Received 1 April 2019; accepted 22 July 2019

Available online 20 March 2020

<https://doi.org/10.1016/j.abd.2019.07.014>

0365-0596/ © 2020 Sociedade Brasileira de Dermatologia.

Published by Elsevier España, S.L.U. This is an open access article under the CC BY license (<http://creativecommons.org/licenses/by/4.0/>).

Herpes zoster incognito: an immunohistochemical diagnosis^{☆☆☆}



Dear Editor,

A 60-year-old woman presented with a 1 week history of an erythematous and edematous plaque on her scalp. The lesion, 2.5 cm in diameter, was associated to mild pain (Fig. 1). Histopathological examination showed a massive inflammatory infiltrate in the dermis, especially surrounding sebaceous glands and responsible of oedema in the papil-

lary dermis with initial dermo-epidermal vesicle formation (Fig. 2A). In the suspect of a herpetic infection, immunohistochemistry was performed, revealing negativity for Herpes Simplex virus (HSV) and positivity for Varicella Zoster virus (VZV) (Fig. 2B). Our diagnosis was therefore herpes zoster incognito.

Herpes zoster (HZ), due to the reactivation of VZV, present in a latent state in sensory ganglia, can remain inactive for decades or also for the whole life. Essential condition is a previous contact, usually during infancy, with VZV. HZ is characterized by unilateral erythematous-vesicular rash and a localized pain. Nevertheless, especially at the onset of an eruption or in forms considered as abortive, when lesions are macules, papules, and plaques, clinical diagnosis may be challenging. Microscopical examination can be used to confirm infection by herpesviruses, but sometimes typical signs such as multinucleated epithelial cells or ghosts of them are not encountered in a specimen.

[☆] How to cite this article: Nazzaro G, Veraldi S. Herpes zoster incognito: an immunohistochemical diagnosis. *An Bras Dermatol.* 2020;95:401–2.

^{☆☆} Study conducted at the Department of Pathophysiology and Transplantation, Università degli Studi di Milano, Fondazione IRCCS Ca' Granda Ospedale Maggiore Policlinico, Milan, Italy.