

and interpretation; effective participation in the research guidance; intellectual participation in the propaedeutic and/or therapeutic conduct of the studied cases; critical review of the literature; final approval of the final version of the manuscript.

Igor Kapetanovic: Writing of the manuscript or critical review of important intellectual content; data collection, analysis and interpretation; final approval of the final version of the manuscript.

Aleksandra Sokic-Milutinovic: Intellectual participation in the propaedeutic and/or therapeutic conduct of the studied cases; critical review of the literature; final approval of the final version of the manuscript.

## Conflicts of interest

None declared.




## Acknowledgment

This study was partially supported by the Serbian Ministry of Education and Science (Grant n<sup>o</sup> 451-03-47/2023-01/200110).

## References

- Horiuchi Y, Shimakura S. Mesalazine and photosensitivity. *Am J Gastroenterol.* 1999;94:3386–7.
- Cozzani E, Pappalardo F, Gallo R, Parodi A. Photosensitivity induced by mesalazine: report of a case. *Am J Gastroenterol.* 2014;109:923–4.
- Al-Niaimi F, Lyon C. Mesalazine-induced photosensitivity. *Eur J Dermatol.* 2011;21:105–6.
- Klotz U. The pharmacological profile and clinical use of mesalazine (5-aminosalicylic acid). *Arzneimittelforschung.* 2012;62:53–8.

- Moum B. Which are the 5-ASA compound side effects and how is it possible to avoid them? *Inflamm Bowel Dis.* 2008;14:S212–13.
- Glatz M, Hofbauer GF. Phototoxic and photoallergic cutaneous drug reactions. *Chem Immunol Allergy.* 2012;97:167–79.
- Monteiro AF, Rato M, Martins C. Drug-induced photosensitivity: photoallergic and phototoxic reactions. *Clin Dermatol.* 2016;34:571–81.
- Shukla A, Mahapatra A, Gogtay N, Khopkar U. Esomeprazole-induced photoallergic dermatitis. *J Postgrad Med.* 2010;56:229–31.
- Naranjo CA, Busto U, Sellers EM, Sandor P, Ruiz I, Roberts EA, et al. A method for estimating the probability of adverse drug reactions. *Clin Pharmacol Ther.* 1981;30:239–45.

Svetlana Popadic  a,b,\* , Igor Kapetanovic  b , Aleksandra Sokic-Milutinovic  c,d

<sup>a</sup> Department of Dermatology and Venereology, Faculty of Medicine, University of Belgrade, Belgrade, Serbia

<sup>b</sup> Clinic of Dermatovenereology, University Clinical Center of Serbia, Belgrade, Serbia

<sup>c</sup> Department of Gastroenterology and Hepatology, Faculty of Medicine, University of Belgrade, Belgrade, Serbia

<sup>d</sup> Clinic for Gastroenterology and Hepatology, Clinical Center of Serbia, Belgrade, Serbia

\* Corresponding author.

E-mail: [scpopadic@gmail.com](mailto:scpopadic@gmail.com) (S. Popadic).

Received 24 April 2023; accepted 10 July 2023

<https://doi.org/10.1016/j.abd.2023.07.001>  
0365-0596/ © 2023 Published by Elsevier España, S.L.U. on behalf of Sociedade Brasileira de Dermatologia. This is an open access article under the CC BY license (<http://creativecommons.org/licenses/by/4.0/>).

## Oral isotretinoin for the treatment of chronic pityriasis versicolor: case report and literature review<sup>☆</sup>



Dear Editor,

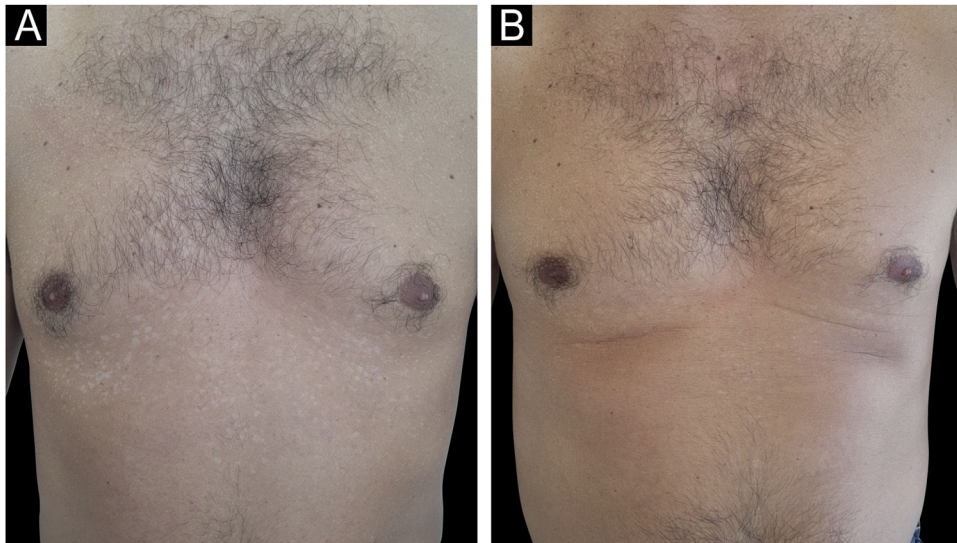
Pityriasis versicolor (PV) is a superficial mycosis caused by yeast species of the *Malassezia* genus. It affects individuals worldwide, mostly in countries with tropical and subtropical climates, where the incidence can reach up to 50% of the population.<sup>1</sup> Propaedeutic and complementary methods such as the Zireli sign, dermoscopy, and Wood's light are useful both in the diagnosis of the infection and in evaluating the therapeutic response by helping to differentiate between active disease and post-inflammatory hypochromia.<sup>1–4</sup>

Treatment is especially challenging in cases of recurrent or chronic evolution, not due to the pathogen intrinsic

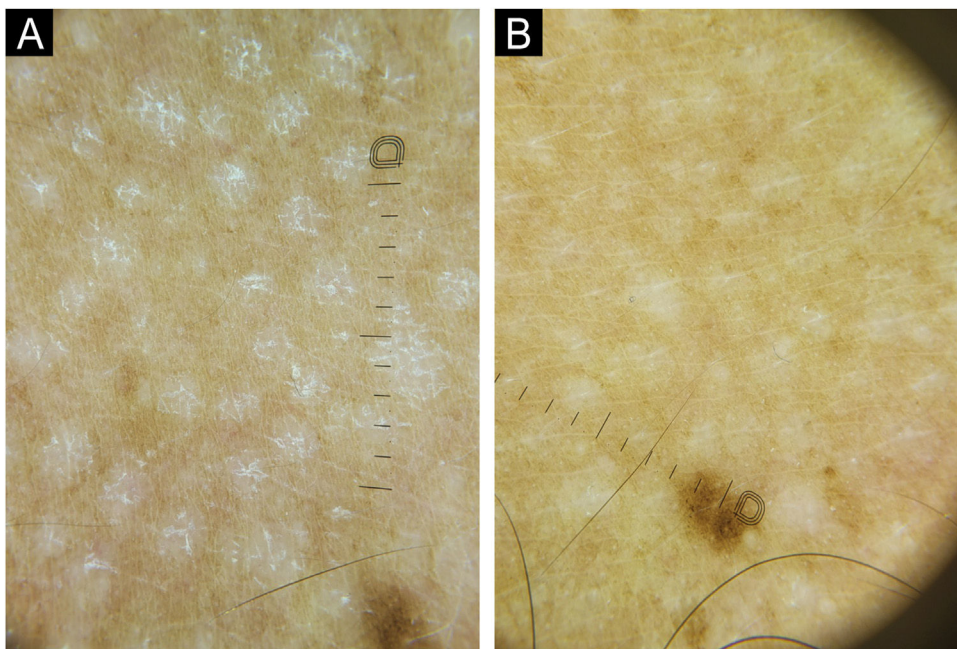
resistance to antifungals used topically and systemically, but due to individual host factors present in the human microbiome that favor an environment suitable for the persistence of the lipophilic fungus.<sup>3,5</sup> Scientific studies on the use of oral isotretinoin as an alternative to treat infection are scarce, the vast majority of which are case reports.<sup>6–8</sup> The authors report on a patient with chronic PV without improvement following classical treatments based on antifungals, he showed a good response after a few weeks of oral isotretinoin use.

A 40-year-old healthy male patient, undergoing dermatological follow-up for eight years due to chronic PV was evaluated. During the period, he had undergone several treatments with antiseborrheic soaps, topical antifungals in shampoo, cream and spray lotion formulations (ciclopirox olamine and azole derivatives), in addition to oral treatments with ketoconazole, itraconazole and fluconazole, with little improvement and always maintaining a positive Zireli sign, compatible with active infection.<sup>2,4</sup> Dermatological examination revealed diffusely oily skin and PV in a follicular pattern. The patient denied using creams and emollients, and the habit of taking two showers a day. Considering the chronic condition with resistance to classic therapies and oily skin characteristics, general laboratory

<sup>☆</sup> Study conducted at the Dermatology Clinic, Hospital da Santa Casa de São Paulo, São Paulo, SP, Brazil.



**Figure 1** Patient with chronic pityriasis versicolor. (A) Before treatment. (B) After eight weeks of treatment with a low/weekly dose of oral isotretinoin.



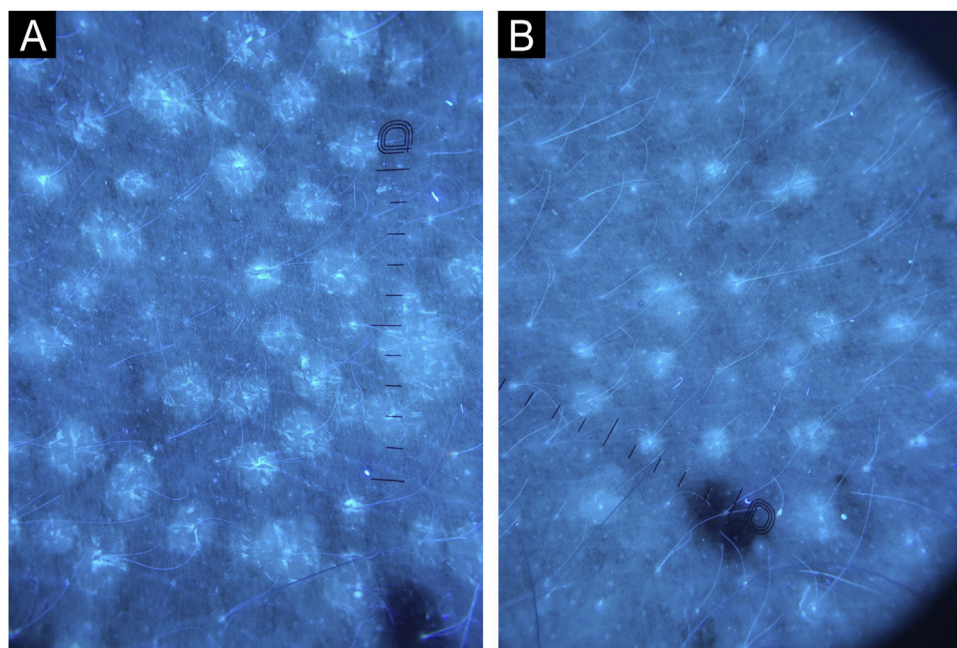
**Figure 2** Dermoscopy with polarized light of a patient with chronic pityriasis versicolor. (A) Circular macules centered on the hair follicles, with the presence of desquamation after the Zirelí propaedeutic maneuver, compatible with active disease. (B) After eight weeks of treatment with oral isotretinoin, a reduction in the number and size of lesions was observed, with no desquamation after the Zirelí maneuver, compatible with post-inflammatory hypochromia after resolution (Dermatoscope DL5 DermLite®,  $\times 10$ ).

tests were carried out, which showed normal results. Then an off-label treatment of oral isotretinoin as monotherapy was proposed, without association with previously reported treatments. A dose of 20 mg/week was prescribed, and the patient improved significantly after eight weeks of follow-up, without any laboratory alterations. A total dose of 160 mg was administered during the period (Figs. 1, 2 and 3). To improve the oily skin condition and prevent the recurrence of the infection, continuous use of this dose of isotretinoin was maintained.

The classification of recurrent and chronic PV is based on the number of lesion recurrences after treatment with adequate antifungals over a two-year period: up to four for

recurrent, and more than four for chronic conditions. As concluded by Framil et al., there is no correlation between the *Malassezia* species, the clinical form, and recurrence episodes, but a close relationship with individual predisposing factors.<sup>3</sup>

The use of isotretinoin for PV was initially described in 2006 by Bartel et al., in a case of a 14-year-old adolescent with PV on the back and severe acne, treated with 40 mg of isotretinoin, twice a day (1 mg/kg/day), for five months. There was clinical and mycological cure of PV, suggesting a direct role against *Malassezia* or through the reduction of the cutaneous lipid content by the drug, making the environment less favorable for the lipophilic fungus.<sup>6</sup> In 2018, Yazici



**Figure 3** Dermoscopy with Wood's light ( $\times 10$ ) in a patient with chronic pityriasis versicolor. Hypochromia and pre-treatment desquamation compatible with active disease are more accurately observed (A); and post-treatment with a reduction in the number and size of macules, in addition to absence of desquamation, compatible with post-inflammatory hypochromia after resolution (B). (Dermatoscope DL5 Dermlite<sup>®</sup>,  $\times 10$ ).

et al. described another case of a patient with chronic PV for 15 years who was treated with oral isotretinoin at a dose of 20 mg/day for two months, showing sustained improvement after one year of medication withdrawal.<sup>7</sup> In a recent extensive review study on isotretinoin, Bagatin et al. discuss several off-label uses of the drug, including seborrheic dermatitis but do not specifically address PV.<sup>8</sup> Geissler et al. reported that treatment with very low doses of isotretinoin (2.5 mg/3 times a week) is effective in controlling seborrhea, with a 51% reduction in the size of the sebaceous gland, as demonstrated on histopathology.<sup>9</sup>

Reduced doses to control moderate acne have been successfully described since the 90s,<sup>10</sup> an opinion supported to this day by reviews that demonstrate a tendency to prescribe lower daily doses (0.1 – 0.5 mg/kg, up to 5 mg), for a longer period (up to 18 months), fewer adverse events, better tolerability and relapse rates similar to those observed with conventional doses.<sup>8</sup>

Although the efficacy of isotretinoin is well-known in acne, literature on its use in PV is scarce. The likely mechanism underlying the long-term efficacy and remission of PV with isotretinoin use seems to be related to decreased sebum production and sebaceous gland atrophy. Further studies are needed to establish the ideal dose and duration of therapy. The authors think that low-dose isotretinoin may be a good therapeutic option for recurrent and chronic PV. It is clear that research into the use of isotretinoin to control PV is a field that is extremely lacking in robust and consistent studies.

### Financial support

None declared.

### Authors' contributions

John Verrinder Veasey: Design and planning of the study; data collection, or analysis and interpretation of data; drafting and editing of the manuscript or critical review of important intellectual content; collection, analysis and interpretation of data; intellectual participation in the propaedeutic and/or therapeutic conduct of the studied cases; critical review of the literature; approval of the final version of the manuscript.

Gustavo de Sá Menezes Carvalho: Design and planning of the study; data collection, or analysis and interpretation of data; drafting and editing of the manuscript or critical review of important intellectual content; collection, analysis and interpretation of data; critical review of the literature; approval of the final version of the manuscript.

Guilherme Camargo Julio Valinoto: Design and planning of the study; data collection, or analysis and interpretation of data; drafting and editing of the manuscript or critical review of important intellectual content; collection, analysis and interpretation of data; critical review of the literature; approval of the final version of the manuscript.


### Conflicts of interest

None declared.


### References

- Gupta AK, Bluhm R, Summerbell R. Pityriasis versicolor. *J Eur Acad Dermatol Venereol.* 2002;16:19–33.
- Veasey JV, de Macedo PM, Amorim JR, Orofino-Costa R. The correct nomenclature of Zirelí sign in the propaedeutics of pityriasis versicolor (in memoriam). *An Bras Dermatol.* 2021;96:591–4.

3. Framil VMS, Melhem MS, Szesz MW, Zaitz C. New aspects in the clinical course of pityriasis versicolor. *An Bras Dermatol.* 2011;86:1135–40.
4. Veasey JV, Avila RB, Miguel BAF, Muramatu LH. White piedra, black piedra, tinea versicolor, and tinea nigra: contribution to the diagnosis of superficial mycosis. *An Bras Dermatol.* 2017;92:413–6.
5. Kamamoto CSL, Nishikaku AS, Gompertz OF, Melo AS, Hassun KM, Bagatin E. Cutaneous fungal microbiome: *Malassezia* yeasts in seborrheic dermatitis scalp in a randomized, comparative and therapeutic trial. *Dermatoendocrinol.* 2017;9:e1361573.
6. Bartell H, Ransdell BL, Ali A. Tinea versicolor clearance with oral isotretinoin therapy. *J Drugs Dermatol.* 2006;5:74–5.
7. Yazici S, Baskan EB, Saricaoglu H. Long-term remission of recurrent pityriasis versicolor with short-term systemic isotretinoin therapy. *J Dermat Cosmetol.* 2018;2:94–5.
8. Bagatin E, Costa CS, Rocha MADD, Picosse FR, Kamamoto CSL, Pirmez R, et al. Consensus on the use of oral isotretinoin in dermatology – Brazilian Society of Dermatology. *An Bras Dermatol.* 2020;95 Suppl 1:19–38.
9. Geissler SE, Michelsen S, Plewig G. Very low dose isotretinoin is effective in controlling seborrhea. *J Dtsch Dermatol Ges.* 2003;1:952–8.
10. Layton AM, Knaggs H, Taylor J, Cunliffe WJ. Isotretinoin for acne vulgaris – 10 years later: a safe and successful treatment. *Br J Dermatol.* 1993;129:292–6.

John Verrinder Veasey  <sup>a,b,\*</sup>,

Gustavo de Sá Menezes Carvalho  <sup>a,b</sup>,

Guilherme Camargo Julio Valinoto  <sup>a,b</sup>

<sup>a</sup> *Dermatology Clinic, Hospital da Santa Casa de São Paulo, São Paulo, SP, Brazil*

<sup>b</sup> *Discipline of Dermatology, Santa Casa de São Paulo School of Medical Sciences, São Paulo, SP, Brazil*

\* Corresponding author.

E-mail: [johnveasey@uol.com.br](mailto:johnveasey@uol.com.br) (J.V. Veasey).

Received 22 July 2023; accepted 25 August 2023

<https://doi.org/10.1016/j.abd.2023.08.014>

0365-0596/ © 2024 Published by Elsevier España, S.L.U. on behalf of Sociedade Brasileira de Dermatologia. This is an open access article under the CC BY license (<http://creativecommons.org/licenses/by/4.0/>).

## Pityriasis rubra pilaris after COVID-19 vaccination: successful treatment with ustekinumab\*



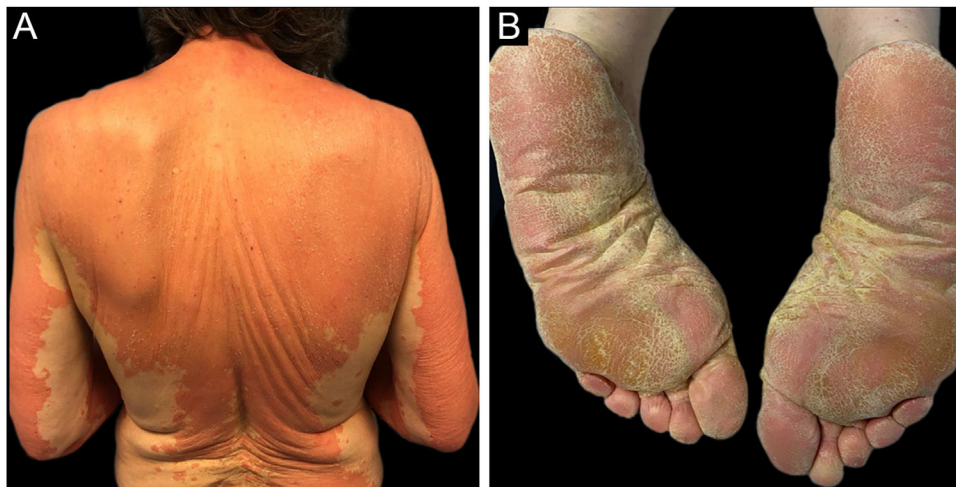Dear Editor,

Pityriasis Rubra Pilaris (PRP) is a rare erythematous papulosquamous inflammatory dermatosis.<sup>1</sup>

Since the approval of mRNA vaccines for COVID-19, the dermatology community strived to characterize the adverse cutaneous effects associated with their administration.

We report a case of PRP following administration of mRNA Pfizer-BioNTech COVID-19 vaccine with refractoriness to first-line systemic therapy that was successfully treated with ustekinumab.

A 69-year-old Caucasian woman, with no relevant medical history, was referred due to a 6-month course of generalized rash that did not improve with highly potent topical and systemic corticosteroids (1 mg/kg/day) or oral cyclosporin (4 mg/kg/day). She reported a facial erythematous scaly rash 2-days after receiving the first dose of the Pfizer-BioNTech COVID-19 vaccine. A few days following the second vaccine dose the patient noticed a worsening of the rash with progression to the trunk and limbs. She reported



**Figure 1** Orange-red squamous plaques with islands of sparing in the trunk and both arms (A). Orange-red waxy and symmetrical palmoplantar keratoderma (B).

\* Study conducted at the Centro Hospitalar Universitário de São João, EPE, Porto, Portugal.