

LETTER - THERAPY

Low-dose oral minoxidil for persistent chemotherapy and radiotherapy-induced alopecia in a pediatric female patient*



Dear Editor,

Cytotoxic chemotherapy, molecularly targeted therapy, immunotherapy, radiotherapy, stem cell transplant, and endocrine therapies may lead to hair disorders which in most cases are reversible.^{1,2} However, persistent Chemotherapy-Induced Alopecia (pCIA) and persistent Radiotherapy-Induced Alopecia (pRIA) can occur.^{1,2} They are defined as incomplete hair regrowth more than 6 months after treatment conclusion.² It depends on the type, duration, and dose of oncological treatment.¹ This article reports a pediatric female patient with pCIA and pRIA, who showed

significant hair regrowth using Low-Dose Oral Minoxidil (LDOM).

A 4-year-old female patient was diagnosed with Atypical Rhabdoid Teratoid Tumor (ARTT) of the cerebellum. Dana-Farber protocol chemotherapy was initiated with vincristine, cisplatin, doxorubicin, cyclophosphamide, etoposide, temozolomide, and actinomycin D for 18 months. In addition, she was submitted to 10 sessions of intrathecal chemotherapy with cytarabine and dexamethasone, followed by skull and neuraxis radiotherapy, and an occipital craniotomy with partial tumor resection. Fortunately, she achieved oncological remission but evolved with pCIA and pRIA. At age 9, alopecia became a cosmetic concern, so 5% topical minoxidil was tried once daily for 6-months with no clinical response. At age 14, LDOM was started at 0.5 mg/day with some improvement in hair density after 6 months. This dose was increased to 1 mg/day for another 6 months with remarkable clinical and trichoscopic response and no reported side effects (Figs. 1–2).

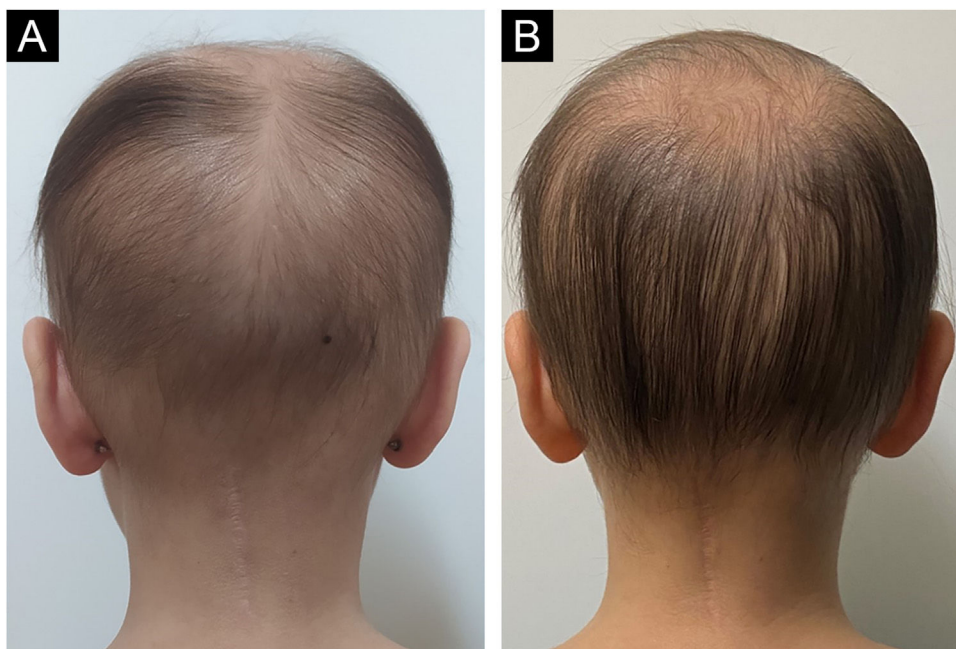


Figure 1 (A) Clinical photograph of female pediatric patient with pRIA and pCIA before treatment, showing diffuse alopecia with thin hairs. (B) Clinical image of the same patient after one year of treatment with LDOM showing improvement of hair density.

* Study conducted at the Pedro Ernesto Hospital, Universidade do Estado do Rio de Janeiro, Rio de Janeiro, RJ, Brazil.

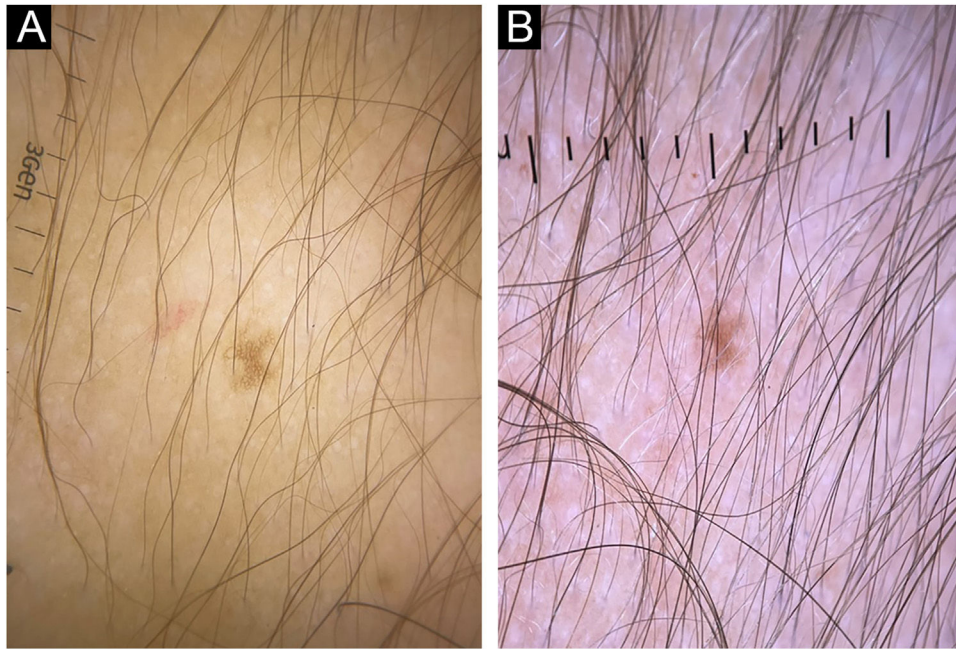


Figure 2 (A) Trichoscopy image low hair density with a predominance of thin hairs before treatment with LDOM. (B) Trichoscopy image of the same area, showing a significant improvement in hair density and predominance of thicker hair shafts after one year of LDOM treatment.

pCIA has been reported in 14% of childhood cancer survivors.¹ Acute hair loss during chemotherapy occurs due to the cytotoxic action on the hair follicle, interrupting mitosis and disturbing the hair cycle. The exact mechanisms that lead to pCIA and pRIA are unclear but may be related to damage to follicle stem cells and altered signaling with failure to restore a new cycle.^{2,3} The association of chemotherapy and radiotherapy increases the risks of persistent alopecia.²

Busulfan, cyclophosphamide, anthracycline, carboplatin, docetaxel, paclitaxel, and etoposide are the agents most commonly associated with pCIA. Clinically, pCIA may present similar to androgenetic alopecia, with a diffuse or patchy pattern or total alopecia. Histopathology often shows non-scarring alopecia with reduced hair density and miniaturization.³

Oral minoxidil is an arterial vasodilator first introduced as an antihypertensive medication.^{4,5} In dermatology, LDOM (0.25–5 mg/day) has been increasingly used for androgenetic alopecia, alopecia areata, traction alopecia, and, more recently, pCIA.^{4,5} For pRIA in the pediatric population, LDOM has not yet been reported. A retrospective study with 63 pediatric patients treated with LDOM for different types of hair loss showed no serious adverse effects.⁵

pCIA and pRIA can cause significant distress, impacting the psychosocial development of children and adolescents. It is particularly challenging when they co-occur. We presented a case of associated pCIA and pRIA successfully treated with LDOM. Despite the few reports in the literature of this medication in the pediatric age group for persistent hair loss conditions, it seems to be safe and effective and should be considered by dermatologists.

Financial support

None declared.

Authors' contributions

Raíssa Rodriguez Melo: Prepared the draft; wrote the manuscript and approved the final version to be published.

Rita Fernanda Cortez de Almeida: Designed the study; wrote the manuscript and approved the final version to be published.

Luciana Rodino Lemes: Designed the study; wrote the manuscript and approved the final version to be published.

Sidney Frattini Junior: prepared the draft, reviewed the text and approved the final version to be published.

Paulo Muller Ramos: Designed the study; critically reviewed the manuscript and approved the final version to be published.

Daniel Fernandes Melo: Conceived the study; critically reviewed the manuscript and approved the final version to be published.







Conflicts of interest

None declared.

References

- Freites-Martinez A, Shapiro J, Goldfarb S, Nangia J, Jimenez JJ, Paus R, et al. Hair disorders in patients with cancer. *J Am Acad Dermatol.* 2019;80:1179–96.
- Kessler S, Marzooq A, Sood A, Beebe K, Walsh A, Montoya L, et al. Alopecia in children undergoing chemotherapy, radiation, and hematopoietic stem cell transplantation: scoping review and approach to management. *Pediatr Dermatol.* 2022;39:354–62.
- Bhojru B, Asfour L, Lutz G, Mitchell L, Jerjen R, Sinclair RD, et al. Clinicopathologic characteristics and response to treatment of persistent chemotherapy-induced alopecia in breast cancer survivors. *JAMA Dermatol.* 2021;157:1335–42.

4. Lyakhovitsky A, Segal O, Maly A, Zlotogorski A, Barzilai A. Permanent chemotherapy-induced alopecia after hematopoietic stem cell transplantation treated with low-dose oral minoxidil. *JAAD Case Rep.* 2022;22:64–7.
5. John JM, Sinclair RD. Systemic minoxidil for hair disorders in pediatric patients: a safety and tolerability review. *Int J Dermatol.* 2023;62:257–9.

Raíssa Rodriguez Melo ^{a,*},
 Rita Fernanda Cortez de Almeida ^a,
 Luciana Rodino Lemes ^a, Sidney Frattini Junior ^b,
 Paulo Müller Ramos ^c, Daniel Fernandes Melo ^d

^a *Dermatology Department, Universidade do Estado do Rio de Janeiro, Rio de Janeiro, RJ, Brazil*

^b *The Mole Clinic, Private Practice, Ancaster, Ontario, Canada*

^c *Department of Infectious Diseases, Dermatology, Imaging Diagnosis and Radiotherapy, Faculty of Medicine, Universidade Estadual Paulista, Botucatu, SP, Brazil*

^d *Dermatology Department, Universidade do Estado do Rio de Janeiro (UERJ), Rio de Janeiro, RJ, Brazil*

* Corresponding author.

E-mail: rodriguezraissaa@gmail.com (R.R. Melo).

Received 20 June 2023; accepted 5 July 2023

<https://doi.org/10.1016/j.abd.2023.07.010>

0365-0596/ © 2024 Sociedade Brasileira de Dermatologia.

Published by Elsevier España, S.L.U. This is an open access article under the CC BY license (<http://creativecommons.org/licenses/by/4.0/>).

Mesalamine-induced photosensitivity – A case report and literature review[☆]



Dear Editor,

We present a case of mesalamine-induced photosensitivity in a patient with Ulcerative Colitis (UC). To the best of our knowledge, this is the fourth case of mesalamine-induced photosensitivity reported so far.^{1–3}

In April 2018, a 26-year-old male presented with diffuse erythema and erythematous papules on sun-exposed areas (Figs. 1 and 2). Skin lesions appeared during the first sunny spring days (average UV index was 5 – moderate). He has no previous history of sun sensitivity. In personal history, five weeks before admission to our department, he started treatment for UC. Treatment included oral and rectal forms of mesalamine alongside oral prednisolone and esomeprazole.

At admission routine laboratory analysis of blood and urine were within normal limits. Immunological analysis (IgG, IgM anti-cardiolipin antibodies, IgG anti-mitochondrial antibodies, IgG anti-nucleus antibodies, IgG anti-smooth muscle antibodies, IgG anti-liver kidney microsome type 1 antibodies, IgG anti-parietal antibodies, anti-Extractable Nuclear Antigen (ENA) antibody screen, IgG anti-dsDNA, C3 and C4) were all negative. HIV antigen/antibody, HBsAg, and anti-HCV were all negative. VDRL was negative. Lupus bend tests from sun-exposed and sun-protected areas were negative.

We suggested sun protection along with sun avoidance and initiated topical corticosteroid preparations with concomitant UC treatment (mesalamine 3g/day, prednisolone 20mg/day and esomeprazole 20mg BID) for 4 days. The suggested treatment was without result, erythema was persistent. Due to suspicion that sun sensitivity was induced by mesalamine, mesalamine and topical corticosteroid treatment were discontinued and 20 mg of prednisolone alongside

esomeprazole and sun protection remain the only treatment. During the following 4 days, he spent up to 1 hour/day in the sun and despite that, there was a complete regression of skin lesions (Figs. 1 and 2).

We were interested on whether photosensitivity appears again in the absence of mesalamine so, we suggested unlimited sun exposure without sun protection, for the next 6 days (10 days in total without mesalamine). During those days were no signs of photosensitivity, but UC worsened and mesalamine re-challenge was approached. He took the first, reintroduced, dose of mesalamine and 12–15 h later, he spent 30 minutes outside on a sunny morning. During those 30 minutes, erythema reappeared on sun-exposed areas. We established the diagnosis of mesalamine-induced photosensitivity (Figs. 1 and 2). The gastroenterologist substituted mesalamine with azathioprine and prednisolone was tapered and stopped. UC has been in remission since October 2018, and as of April 2023, he has no manifestations of sun sensitivity.

Mesalamine is the preferred, safe, first-line treatment with proven efficacy in mild to moderate forms of UC⁴ with mild systemic absorption despite its delayed release mechanism.⁵ According to the literature mesalamine may be associated with skin rashes and pruritus.^{4,5}

Many drugs have been implicated in photosensitive reactions but mesalamine is not considered to be one.^{6,7} Only one case of probable esomeprazole-induced photoallergic dermatitis has been reported so far.⁸ Cutaneous adverse drug reactions in sun-exposed areas may be phototoxic or photo-allergic type.⁶ Photo-toxicity appears rapidly after sun exposure because of light activation of the photosensitizing agent, while photoallergy skin lesion appears after 2–3 days due to activation of cell-mediated immune response.⁷ Esomeprazole was not in the treatment protocol in other reported cases with mesalamine-induced photosensitivity.^{1–3} In our patient photosensitivity was not associated with esomeprazole intake. The proof for that is that he had no skin lesions while being treated with esomeprazole in periods when mesalamine was temporarily or permanently withdrawn. The prompt reappearance of erythema in our patient after mesalamine re-challenge indicates a phototoxic type of photosensitivity.

[☆] Study conducted at the Department of Dermatovenereology School of Medicine, University of Belgrade, Clinic of Dermatovenereology University Clinical Center of Serbia, Belgrade, Serbia