




3. Framil VMS, Melhem MS, Szesz MW, Zaitz C. New aspects in the clinical course of pityriasis versicolor. *An Bras Dermatol.* 2011;86:1135–40.
4. Veasey JV, Avila RB, Miguel BAF, Muramatu LH. White piedra, black piedra, tinea versicolor, and tinea nigra: contribution to the diagnosis of superficial mycosis. *An Bras Dermatol.* 2017;92:413–6.
5. Kamamoto CSL, Nishikaku AS, Gompertz OF, Melo AS, Hassun KM, Bagatin E. Cutaneous fungal microbiome: *Malassezia* yeasts in seborrheic dermatitis scalp in a randomized, comparative and therapeutic trial. *Dermatoendocrinol.* 2017;9:e1361573.
6. Bartell H, Ransdell BL, Ali A. Tinea versicolor clearance with oral isotretinoin therapy. *J Drugs Dermatol.* 2006;5:74–5.
7. Yazici S, Baskan EB, Saricaoglu H. Long-term remission of recurrent pityriasis versicolor with short-term systemic isotretinoin therapy. *J Dermat Cosmetol.* 2018;2:94–5.
8. Bagatin E, Costa CS, Rocha MADD, Picosse FR, Kamamoto CSL, Pirmez R, et al. Consensus on the use of oral isotretinoin in dermatology – Brazilian Society of Dermatology. *An Bras Dermatol.* 2020;95 Suppl 1:19–38.
9. Geissler SE, Michelsen S, Plewig G. Very low dose isotretinoin is effective in controlling seborrhea. *J Dtsch Dermatol Ges.* 2003;1:952–8.
10. Layton AM, Knaggs H, Taylor J, Cunliffe WJ. Isotretinoin for acne vulgaris – 10 years later: a safe and successful treatment. *Br J Dermatol.* 1993;129:292–6.

John Verrinder Veasey  <sup>a,b,\*</sup>,

Gustavo de Sá Menezes Carvalho  <sup>a,b</sup>,

Guilherme Camargo Julio Valinoto  <sup>a,b</sup>

<sup>a</sup> *Dermatology Clinic, Hospital da Santa Casa de São Paulo, São Paulo, SP, Brazil*

<sup>b</sup> *Discipline of Dermatology, Santa Casa de São Paulo School of Medical Sciences, São Paulo, SP, Brazil*

\* Corresponding author.

E-mail: [johnveasey@uol.com.br](mailto:johnveasey@uol.com.br) (J.V. Veasey).

Received 22 July 2023; accepted 25 August 2023

<https://doi.org/10.1016/j.abd.2023.08.014>

0365-0596/ © 2024 Published by Elsevier España, S.L.U. on behalf of Sociedade Brasileira de Dermatologia. This is an open access article under the CC BY license

(<http://creativecommons.org/licenses/by/4.0/>).

## Pityriasis rubra pilaris after COVID-19 vaccination: successful treatment with ustekinumab\*



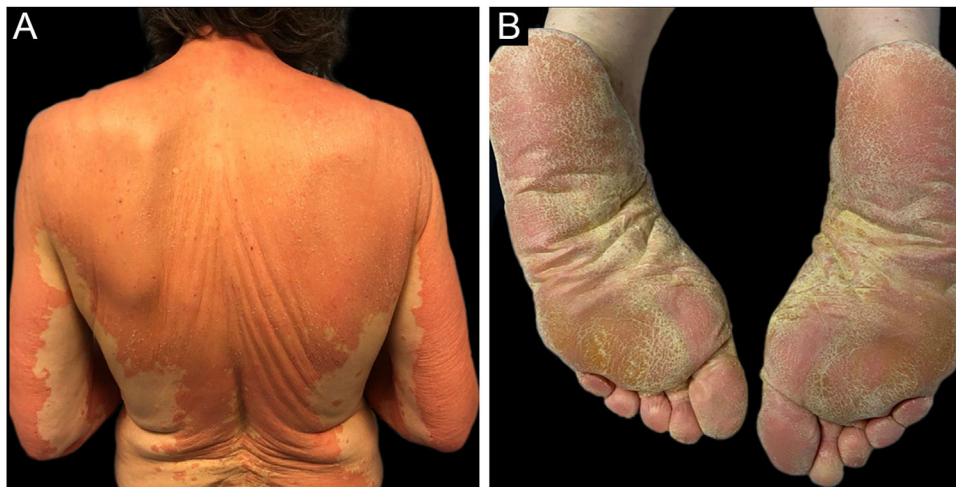Dear Editor,

Pityriasis Rubra Pilaris (PRP) is a rare erythematous papulosquamous inflammatory dermatosis.<sup>1</sup>

Since the approval of mRNA vaccines for COVID-19, the dermatology community strived to characterize the adverse cutaneous effects associated with their administration.

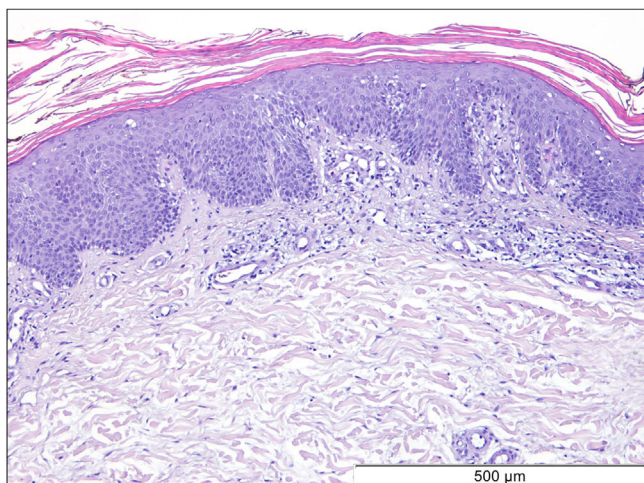
We report a case of PRP following administration of mRNA Pfizer-BioNTech COVID-19 vaccine with refractoriness to first-line systemic therapy that was successfully treated with ustekinumab.

A 69-year-old Caucasian woman, with no relevant medical history, was referred due to a 6-month course of generalized rash that did not improve with highly potent topical and systemic corticosteroids (1 mg/kg/day) or oral cyclosporin (4 mg/kg/day). She reported a facial erythematous scaly rash 2-days after receiving the first dose of the Pfizer-BioNTech COVID-19 vaccine. A few days following the second vaccine dose the patient noticed a worsening of the rash with progression to the trunk and limbs. She reported



**Figure 1** Orange-red squamous plaques with islands of sparing in the trunk and both arms (A). Orange-red waxy and symmetrical palmoplantar keratoderma (B).

\* Study conducted at the Centro Hospitalar Universitário de São João, EPE, Porto, Portugal.



**Figure 2** Histological examination revealed moderate acanthosis with hyperkeratosis and parakeratosis: mild epidermal spongiosis and, in the superficial dermis, a mild perivascular chronic inflammatory cell infiltrate (Hematoxylin & eosin).

intense itch and denied a personal or family history of skin diseases or recent infections. On physical examination, she presented with sharply demarcated confluent orange-red squamous plaques extending from her scalp to the arms and proximal thighs with islands of sparing. There were scattered erythematous plaques over the lower legs and orange-red waxy palmoplantar keratoderma (Fig. 1). Blood tests showed leukopenia ( $3150 \text{ mm}^3$ ) with normal eosinophil counts. Serological testing for the virus and extended immunological study were negative. Computed tomography was unremarkable. Histological examination revealed moderate acanthosis, with a few broad rete ridges, hyperkeratosis, and parakeratosis with mild spongiosis (Fig. 2). In the superficial dermis, there was a mild perivascular chronic inflammatory cell infiltrate. Genetic testing was negative for CARD14 mutations.

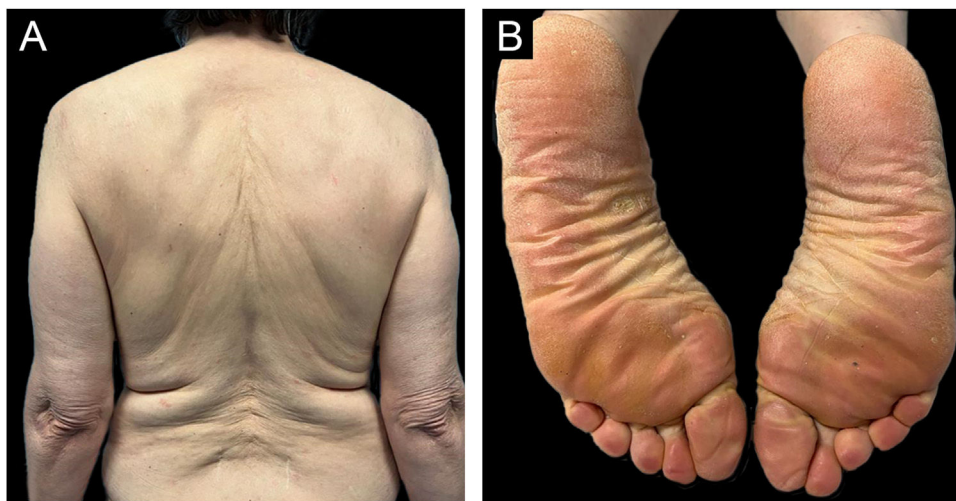
She was initially treated with Methotrexate (MTX) 12.5 mg once a week for 4 weeks, however, it was necessary to increase it to 15 mg during 12 weeks without any

improvement. Hands and feet topical PUVA (Psoralen and Ultraviolet A therapy) was performed concomitantly to MTX with no additional benefit. Subsequently, acitretin 25 mg every other day was prescribed but the patient stopped it 15 weeks later due to an unsatisfactory response and increase in transaminases (10 times de upper limit of normal) which then normalized after the drug withdrawal. As the patient showed refractoriness to first-line systemic therapies we decided to start therapy with ustekinumab (45 mg at week 0, week 4 and then every 12 weeks). At week-4 of ustekinumab almost complete response was achieved, only residual erythema of the face was observed (Fig. 3). The response was maintained during 6 months of follow up and no further COVID-19 vaccine was done.

The etiology and pathogenesis of PRP remains unclear, most cases are sporadic although infections, drugs, malignancies and vaccines are all possible triggers.<sup>1</sup> Since the approval of SARS-CoV-2 vaccines a crescent number of COVID-19 vaccine-induced PRP cases have been reported.<sup>2,3</sup> Given the existing literature, the fact that PRP is a rare condition and the close temporal relationship with COVID-19 vaccination we suggest a causal relationship in the present case.

Treatment of PRP is challenging due to lack of evidence and the gold standard of treatment are oral retinoids followed by methotrexate.<sup>1</sup> In most COVID-19 vaccine-induced PRP cases treatment was systemic, including retinoids, corticosteroids and methotrexate.<sup>2,3</sup> More recently, for patients with failure or contraindication for conventional therapies, biologics have emerged as a promising alternative.<sup>2,4</sup> Those treatments were initially mostly empirical, however Feldmeyer et al. identified higher expression levels of pro-inflammatory innate cytokines and adaptative T-cell cytokines (especially the Th17 cytokines IL-17 and IL-22) in lesional skin of PRP, suggesting the role of IL-23-Th17-pathway in the disease pathogenesis.<sup>5</sup> In fact, interleukin 17 (IL-17), IL-23, and IL-12/23 antagonists have been used with success.<sup>2-4,6</sup>

Our patient's response to ustekinumab after failure of conventional therapies provides additional evidence for the role of IL-23-Th17-pathway in the disease pathogenesis and effectiveness of anti-IL12/23 agents.



**Figure 3** After four weeks of treatment with ustekinumab, there was a great improvement of the lesions (A-B).

## Financial support

None declared.

## Authors' contributions

Bárbara Vieira Granja: The study concept and design; writing of the manuscript or critical review of important intellectual content; critical review of the literature; final approval of the final version of the manuscript.

Patrícia Amoedo: The study concept and design; writing of the manuscript or critical review of important intellectual content; final approval of the final version of the manuscript.

Nuno Preto Gomes: Writing of the manuscript or critical review of important intellectual content; final approval of the final version of the manuscript.

Catarina Costa: Critical review of important intellectual content; final approval of the final version of the manuscript.

Filomena Azevedo: Intellectual participation in the propaedeutic and/or therapeutic conduct of the studied cases; critical review of the literature; final approval of the final version of the manuscript.

Sofia Magina: Intellectual participation in the propaedeutic and/or therapeutic conduct of the studied cases; critical review of the literature; final approval of the final version of the manuscript.

## Conflicts of interest

None declared.

## References

1. Wang D, Chong VC, Chong WS, Oon HH. A review on pityriasis rubra pilaris. *Am J Clin Dermatol.* 2018;19:377–90.

2. Gambichler T, Scheel CH, Arafat Y, Heinzer E, Noldes K, Bulic Z, et al. First onset of pityriasis rubra pilaris following SARS-CoV-2 booster vaccination: case report and review of the literature. *Dermato.* 2022;2:73–8.
3. Gambichler T. Clinical characteristics of patients with pityriasis rubra pilaris following SARS-CoV-2 vaccination. *J Eur Acad Dermatol Venereol.* 2023, <http://dx.doi.org/10.1111/jdv.19046> [Ahead of print].
4. Roenneberg S, Biedermann T. Pityriasis rubra pilaris: algorithms for diagnosis and treatment. *J Eur Acad Dermatol Venereol.* 2018;32:889–98.
5. Feldmeyer L, Mylonas A, Demaria O, Mennella A, Yawalkar N, Laffitte E, et al. Interleukin 23-Helper T Cell 17 axis as a treatment target for pityriasis rubra pilaris. *JAMA Dermatol.* 2017;153:304–8.
6. Gamonal SBL, Marques NCV, Pereira HMB, Gamonal ACC. Pityriasis rubra pilaris (type I) following administration of the BNT162b2 mRNA COVID-19 vaccine: successful treatment with ustekinumab and acitretin. *Dermatol Ther.* 2022;35:e15899.

Bárbara Vieira Granja <sup>a,\*</sup>, Patrícia Amoedo <sup>a</sup>, Nuno Preto Gomes <sup>a</sup>, Catarina Costa <sup>b</sup>, Filomena Azevedo <sup>a</sup>, Sofia Magina <sup>a,c</sup>

<sup>a</sup> Department of Dermatology and Venereology, Centro Hospitalar Universitário de São João, EPE, Porto, Portugal

<sup>b</sup> Department of Pathology, Centro Hospitalar Universitário de São João, EPE, Porto, Portugal

<sup>c</sup> Department of Biomedicine, Faculty of Medicine, Universidade do Porto, Porto, Portugal

\* Corresponding author.

E-mail: [bgranja@campus.ul.pt](mailto:bgranja@campus.ul.pt) (B. Vieira Granja).

Received 9 June 2023; accepted 10 July 2023

<https://doi.org/10.1016/j.abd.2023.07.009>

0365-0596/ © 2024 Sociedade Brasileira de Dermatologia.

Published by Elsevier España, S.L.U. This is an open access article under the CC BY license (<http://creativecommons.org/licenses/by/4.0/>).

## Successful treatment of rheumatoid neutrophilic panniculitis with tofacitinib<sup>☆</sup>



Dear Editor,

The Janus kinase (JAK) family of enzymes, consisting of proteins JAK1, JAK2, JAK3, and TYK2, is a group of tyrosine kinases of great importance in the intracellular signalization, which, when activated by cytokines and growth factors, act on the signal transducers and activators of transcription (STAT), allowing their dimerization and translocation to the nucleus, regulating gene expression and transcription.<sup>1</sup> This signaling pathway, called JAK/STAT, is related to several biological functions, such as proliferation, apoptosis, differentiation, immune regulation, and also hematopoiesis.<sup>2</sup>

JAK inhibitors (JAKi) are promising in the treatment of several rheumatological, hematological, and dermatological diseases. JAKi are small molecules capable of blocking the binding of JAK to its intracellular domain of cytokine receptors, preventing its phosphorylation and STAT dimerization, abolishing signal transduction via JAK/STAT and, consequently, inhibiting the pro-inflammatory response.<sup>3</sup>

Different JAKs can be blocked selectively or together, allowing the development of targeted treatments with fewer adverse reactions. The first JAKi approved for the treatment of autoimmune diseases was Tofacitinib, a small synthetic molecule that targets JAK1 and JAK3, with lesser action on JAK2 and TYK2. The utilization of JAKi in inflammatory and autoimmune diseases has increased over the years, used in the treatment of rheumatoid arthritis, psoriatic arthritis, systemic lupus erythematosus, dermatomyositis, ulcerative colitis, myelofibrosis, polycythemia vera, alopecia areata, vitiligo and atopic dermatitis.<sup>4</sup>

A 60 year-old patient with a history of seropositive rheumatoid arthritis (RA) was evaluated. She used several medication regimens and only achieved good disease control with the following regimens: etanercept, sulfasalazine and hydroxychloroquine. This treatment con-

<sup>☆</sup> Study conducted at the Universidade Federal de Pelotas, Pelotas, RS, Brazil.