

multiple lesions are observed, although solitary lesions have also been recorded.⁴

Cutaneous metastatic lesions of MM are classified into non-specific ones, which are more common: secondary amyloidosis, alopecia, pyoderma gangrenosum, flat xanthomas, anhidrosis, sclerodermiform lesions, lichen myxedematosus, among others, and specific ones, which represent the spread of multiple myeloma in the final stage of the disease: secondary plasmacytomas that occur by direct extension to the skin from underlying bone lesions, such as in the case described in the present report, or by lymphatic and/or hematogenous spread.^{3,4} They present as erythematous nodules, ulcerated or not, or plaques measuring up to 5 cm in diameter. Around 50% of the patients die within six months of the diagnosis. Cutaneous plasmacytomas can also appear in patients without a previous diagnosis of MM and are then called primary cutaneous plasmacytomas.

Therefore, a thorough dermatological examination is essential for the early diagnosis of cutaneous metastases from multiple myeloma. Thus, it becomes possible not only to optimize patient treatment but also to corroborate the importance of dermatologists because of their responsibility in the diagnosis and follow-up of patients with severe systemic diseases.

Financial support

None declared.

Authors' contributions

Larissa Helena Marques Carrai: Design and planning of the study; drafting and editing of the manuscript; collection, analysis and interpretation of data; critical review of the literature.

Elaine Cristina Faria Abrahão Machado: Design and planning of the study; drafting and editing of the manuscript; collection, analysis and interpretation of data; critical review of the literature.

Livia Matida Gontijo: Approval of the final version of the manuscript; effective participation in research orientation; drafting and editing of the manuscript; collection,

analysis and interpretation of data; critical review of the manuscript.





Luiza Castro: Design and planning of the study; drafting and editing of the manuscript; collection, analysis and interpretation of data; critical review of the literature.

Conflicts of interest

None declared.

References

1. Marques SA, Shibata AS, Martins DS, Miot HA, Marques MEA. Metástase cutânea de câncer de mama: relato de caso e revisão da literatura. *Diagn Tratamento*. 2008;13:164–8.
2. Machado DSB, Borges GS, Felipe GC, Ribeiro M, Zamboni F, Siqueira K, et al. Metástases cutâneas como apresentação de câncer de pulmão: relato de caso. *Revista Brasileira de Oncologia Clínica*. 2010;7:124–5.
3. Araújo C, Marques H, Fernandes JC, Pardo A, Brito C. Cutaneous plasmacytomas secondary to nonsecretory multiple myeloma. *J Dermatol Clin Res*. 2014;2:1022.
4. Souza DAF, Freitas THP, Helena P, Paes RAP, Müller H, Hungria VT. Mieloma múltiplo com plasmocitomas cutâneos. *An Bras Dermatol*. 2004;79:581–5.

Larissa Helena Marques Carrai *,
Elaine Cristina Faria Abrahão Machado ,
Luiza Castro , Livia Matida Gontijo 

Pontifícia Universidade Católica de Campinas, Campinas, SP, Brazil

* Corresponding author.

E-mail: dralarissa.carrai.dermatologia@gmail.com
(L.H. Carrai).

Received 5 October 2022; accepted 27 October 2022
Available online 23 February 2024

<https://doi.org/10.1016/j.abd.2022.10.018>
0365-0596/ © 2024 Published by Elsevier España, S.L.U. on behalf of Sociedade Brasileira de Dermatologia. This is an open access article under the CC BY license (<http://creativecommons.org/licenses/by/4.0/>).

High-resolution ultrasound with Doppler as a confirmatory diagnostic method in retronychia[☆]



Dear Editor,

We present the case of a 45-year-old female patient who was referred to the dermatologist with erythema, pain, and discharge in the left hallux. This condition had been present

for four months and was resistant to topical and oral antibiotics. She had active secretion and complete loss of the union of the proximal fold in the affected nail, henceforth chronic paronychia was the original diagnosis (Fig. 1). A high-resolution ultrasound with Doppler analysis of the nail apparatus was requested. The findings established the diagnosis of rethonychia (Figs. 2–4). Then we decided to perform a surgical intervention.

Retronychia is a disorder of the nail apparatus in which there is an abnormal growth of the nail plate within the proximal fold, leading to the formation of several generations of misaligned nail plates under the fold.^{1,2}

Retronychia affects middle-aged adults, mostly females.³ It is characterized by unilateral involvement and affects almost exclusively the hallux.⁴ Repeated trauma, pregnancy,

[☆] Study conducted at the Sonoderma Institution, Medellín, Colombia.

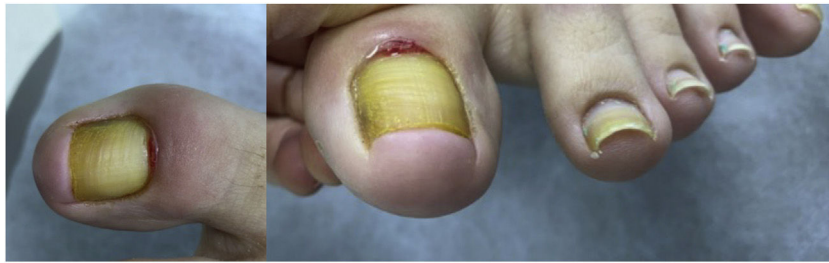

Figure 1 There is absence of plate growth due to complete loss of the union of the proximal fold.

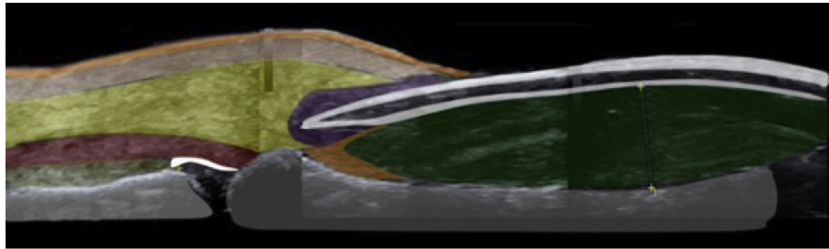


Figure 2 Sonoanatomy of the nail apparatus in retronychia: nail plate (white), nail bed (green), nail matrix (orange), inflammatory halo (purple), extensor tendon (red), subcutaneous tissue (yellow), dermis (pink), epidermis (orange) and phalanx (gray).

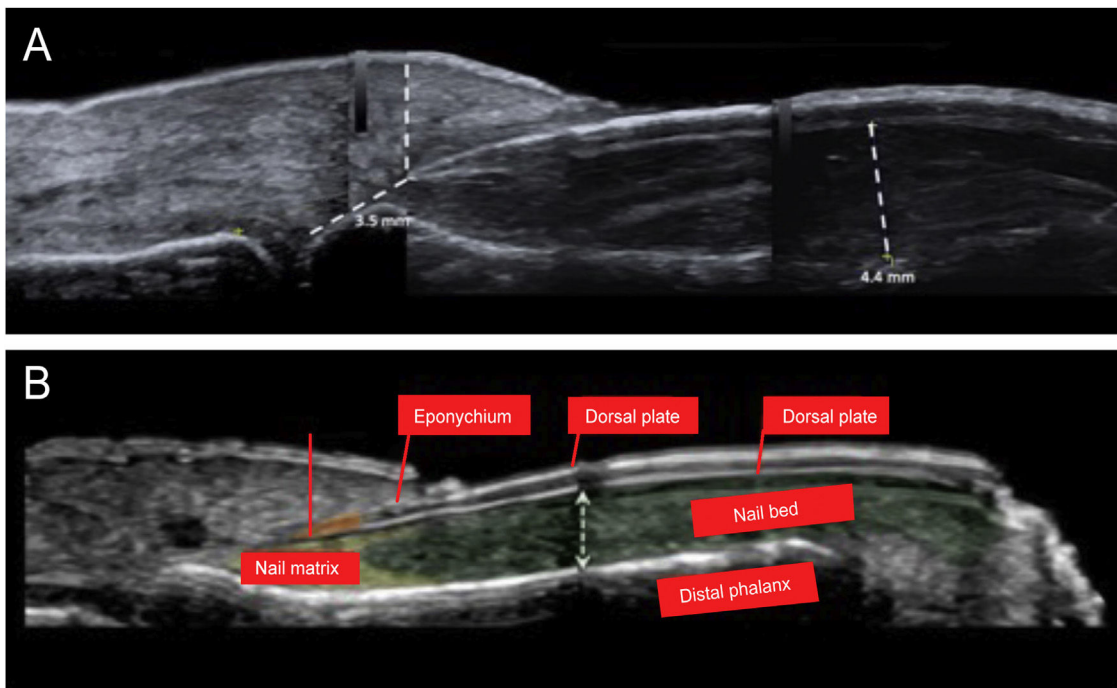


Figure 3 (a) High-resolution skin ultrasound with Doppler analysis performed with a 22 Mhz translator showed thickening of the nail bed with hypochoic appearance. It measured 4.4 mm and did not show any signs of hypervascularization on the Doppler exam. However, it did show a reduction in the space between the origin of the nail plate and the base of the distal phalanx: its measure was approximately 3.5 mm and presented a hypochoic inflammatory halo. (b) Normal anatomy of the nail.

puerperium, use of tight footwear, and anatomical alterations such as fingers in claws or curved nails have been described as associated factors.⁴

After persistent minor traumas, the process begins with an interruption of the growth of the nail plate that leads to its misalignment and incomplete separation from the matrix, where the nail plate loses its fixation in the proximal part of the bed but remains attached to the matrix

in the lateral aspects.⁵ The nail plate moves in a retrograde direction and becomes embedded in the proximal nail fold, leading to inflammation and large tissue formation.¹ The new nail plate will push the old one upwards, leading to abnormal growth and inflammation, thus becoming a vicious cycle, where up to four generations of nail plates can be superimposed under the proximal nail fold. Retronychia

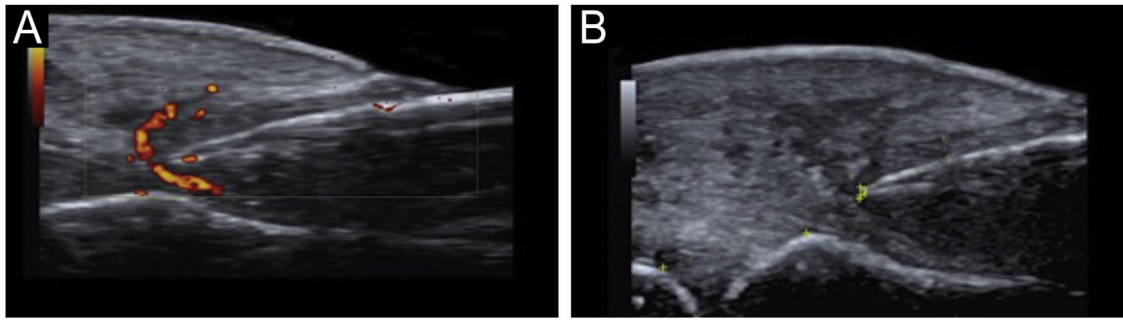


Figure 4 (a) Power Doppler around the nail plate. (b) Visualization of thickening of the nail fold (dermis and hypodermis) of 5 mm.

chia often manifests as a chronic paronychia that is resistant to antimicrobial therapy.⁶

The diagnosis of retronychia is based primarily on clinical aspects and is confirmed by imaging methods. There are different imaging modalities to study the ungular apparatus, including simple radiography, ultrasound, and Magnetic Resonance Imaging (MRI).⁷ Ultrasound has proven to be useful; it has the advantage that it is a non-invasive method, it is accessible and helps in surgical planning.⁸ The type of ultrasound used for the diagnosis in the case presented is a high-resolution method with Doppler analysis, which is different from classical ultrasound. It uses transducers with higher frequencies, up to 22 MHz, that provide a complete and real-time view of the ungular apparatus. It differs by the addition of Doppler analysis and requires a trained person. In the literature, there is evidence of the use of this type of ultrasound to evaluate nail diseases. High-resolution ultrasound proves to be a precise and complete tool where various characteristics of the ungular apparatus can be evaluated that leads to a high histological correlation of different nail conditions.⁹

MRI is also another option. It is excellent for the evaluation of tumors, especially vascular tumors. However, it is highly costly, and it also requires complete immobility of the affected limb, making it difficult to use in the pediatric population.⁷

Ultrasound criteria for rethonychia have been described:⁵

1. Presence of a hypoechoic halo surrounding the origin of the nail plate.
2. Distance (≤ 5.1 mm) between the origin of the nail plate and the base of the distal phalanx (thumbs and first toes) or a difference in this distance ≥ 0.5 mm compared to the contralateral healthy finger.
3. Proximal nail fold thickness ≥ 2.2 mm in men or ≥ 1.9 mm in women and/or a thickness ≥ 0.3 mm compared to the contralateral healthy finger.

If it is unilateral, it must meet these three criteria; if it is bilateral, it can meet any of the three criteria.

Other findings on ultrasound in retronychia are:¹

- Two or more overlapping nail plates.
- Increased blood flow in the dermis of the proximal fold and the nail bed.

Possible causes of chronic paronychia such as infections, neoplasms, systemic diseases, and medications should be ruled out.¹

The mainstay of treatment is based on surgical avulsion, performing a proximal approach to the old nail plate and the possible underlying ingrown plates.¹ High-potency topical steroids could be used in conjunction with a bandage to fix the nail to the bed.³

To prevent retronychia it is important to recommend patients to wear comfortable shoes, avoid repetitive trauma, and in case of foot deformities these should be corrected.²

Financial support

None declared.

Authors' contribution

Cristina Vélez Arroyave: Critical literature review; preparation and writing of the manuscript and study conception and planning.

Laura Carvajal Betancur: Critical literature review; preparation and writing of the manuscript and study conception and planning.

Ángela María Londoño García: Approval of the final version of the manuscript; effective participation in research orientation and study conception and planning.

Leonard Pacheco Peñaranda: Approval of the final version of the manuscript; effective participation in research orientation and study conception and planning.





Conflicts of interest

None declared.

References

1. Alonso-Pacheco ML, de Miguel-Mendieta E, Maseda-Pedrero R, Mayor-Arenal M. Retronychia: a case report including ultrasound imaging and surgical treatment. *Actas Dermosifiliogr.* 2016;107:e33-7.
2. Ventura F, Correia O, Duarte AF, Barros AM, Haneke E. "Retronychia - clinical and pathophysiological aspects". *J Eur Acad Dermatol Venereol.* 2016;30:16-9.

3. de Mello CDBF, Souza MDRE, Noriega LF, Chiacchio ND. Retronychia. *An Bras Dermatol.* 2018;93:707–11.
4. Gerard E, Prevezas C, Doutre M-S, Beylot-Barry M, Cogrel O. Risk factors, clinical variants and therapeutic outcome of retronychia: a retrospective study of 18 patients. *European Journal of Dermatology.* 2016;26:377–81.
5. Fernández J, Reyes-Baraona F, Wortsman X. Ultrasonographic Criteria for Diagnosing Unilateral and Bilateral Retronychia: Ultrasonography of Retronychia. *J Ultrasound Med.* 2018;37:1201–9.
6. Nakouri I, Litaïem N, Jones M, Zeglaoui F. Clinical Features and Surgical Treatment. *Journal of the American Podiatric Medical Association.* 2018;108:3.
7. La Uña: De lo Superficial a lo Profundo.
8. Wortsman X, Wortsman J, Guerrero R, Soto R, Baran R. Anatomical Changes in Retronychia and Onychomadesis Detected Using Ultrasound. *Dermatologic Surgery.* 2010;36:1615–20.
9. Singh R, Bryson D, Singh HP, Jeyapalan K, Dias JJ. High-resolution ultrasonography in assessment of nail-related disorders. *Skeletal Radiol.* 2012;41:1251–61.

Cristina Vélez Arroyave  ^{a,*},
 Laura Carvajal Betancur  ^a,
 Ángela María Londoño García  ^b,
 Leonard Pacheco Peñaranda  ^c

^a *Department of Dermatology, Universidad CES, Medellín, Colombia*

^b *Department of Dermatology, Epidemiologist, Universidad CES, Medellín, Colombia*

^c *Department of Radiology, Expert in Dermatological Ultrasound, Responsible for Sonoderma, Medellín, Colombia*

Corresponding author.

E-mail: cristinaveleza@gmail.com (C.V. Arroyave).

Received 19 May 2021; accepted 20 July 2021

Available online 29 January 2024

<https://doi.org/10.1016/j.abd.2021.07.013>
 0365-0596/ © 2023 Published by Elsevier España, S.L.U. on behalf of Sociedade Brasileira de Dermatologia. This is an open access article under the CC BY license (<http://creativecommons.org/licenses/by/4.0/>).

Multiple familial trichoepithelioma: report of a disfiguring case[☆]



Dear Editor,

This case describes a 40-year-old woman, with normochromic asymptomatic papules and nodules on the face, scalp, and upper back since puberty, which gradually increased in number and size (Fig. 1).

She reported difficulty in getting a job due to the skin lesions. She denied other comorbidities and medication use and reported that other family members had similar, but less extensive lesions (Fig. 2).

Dermoscopy (Fig. 1) and histopathology (Fig. 3) were compatible with trichoepitheliomas. It was not possible to perform genetic testing due to its unavailability.

Treatment was administered with imiquimod 5% cream twice a day and 0.5% topical tretinoin at night for six months, progressing with skin irritation and without significant improvement of the lesions.

Multiple familial trichoepithelioma (MFT) is a rare autosomal dominant genodermatosis associated with genetic mutations in the tumor suppression and cylindromatosis (CYLD) genes located, respectively, on chromosomes 9p21 and 16q12-q13.1-3. These genes favor the proliferation and differentiation of the germ cells of the pilosebaceous units, enabling the development of trichoepitheliomas.^{1,2}

MFT affects more women due to its lower expressiveness and genetic penetrance in males.^{1,2} There is no racial predilection³ and a family history is generally positive.^{1,2}

It manifests in childhood or adolescence, with the appearance of papulonodular, normochromic, or erythematous, shiny lesions, which mainly affect symmetrically the central region of the face.^{1,2} They can also affect the scalp, cervical region, and upper chest.^{1,2} Over the years, the lesions can increase in number and size.^{1,2}

The phenotype in MFT is variable.⁴ While there are patients with few lesions, others have multiple confluent and deforming lesions.⁴ This generates important aesthetic consequences and psychosocial suffering.^{1,3} Malignant transformation of trichoepitheliomas into trichoblastic or basal cell carcinoma may also occur, although it is rare.^{1,2}

The dermoscopy of trichoepitheliomas shows small, fine-caliber arboriform vessels, chrysalises and milium pseudocysts over white, pink and, less frequently, yellowish or brown areas.³

Histopathology indicates the presence of keratin pseudocysts and lobules of monomorphic basaloid cells arranged in a cribriform pattern, surrounded by abundant fibrous stroma.^{1,2}

The diagnosis of MFT depends on clinical-histopathological findings.^{3,5} The genetic study is useful for counseling, but not essential.^{3,5}

Several syndromes present with facial papules and nodules, such as Brooke-Spiegler, familial cylindromatosis, Bazex-Dupré-Christol and tuberous sclerosis.^{3,5} Hence, both clinically and histopathologically, it is important to rule out other associated complications that indicate another diagnosis.

Both MFT and familial cylindromatosis (FC) are considered different spectrums of Brooke-Spiegler syndrome (BSS), due to the mutation in the common CYLD.⁴ However, in BSS there are multiple spiradenomas, cylindromas, and trichoepitheliomas, while in FC there are only cylindromas, and in MFT, only trichoepitheliomas.⁴

[☆] Study conducted at the Service of Dermatology, Complexo Hospitalar Padre Bento de Guarulhos, Guarulhos, SP, Brazil.