

called *neurogenic inflammation*,<sup>1,3</sup> which is mediated by neuromodulators. The most important are Calcitonin Gene-Related Protein (CGRP) and Substance P (SP). They act on the endothelial cells and smooth muscle cells leading to vascular changes. SP induces edema and neovascularization. CGRP is a potent microvascular vasodilator that worsens local inflammation.<sup>3</sup>

The response of NR is poor to conventional therapies.<sup>4</sup> Drugs that attenuate neurotransmitter release could be effective (pregabalin, gabapentin, antidepressants, memantine, and duloxetine).<sup>1</sup> Pregabalin modulates the release of SP and CGRP. Duloxetine has an anti-inflammatory and immune-modulatory effect.<sup>5</sup> Both drugs helped with her anxiety and depression symptoms as well as the somatic symptoms.

Light therapies, like IPL, are successful for rosacea. IPL uses photothermolysis to destroy blood vessels reducing facial erythema. The fluence, pulse width, and inter-pulse interval considerations will depend on the patient's phototype, the severity of the condition, and tolerance to treatment, and is adjustable according to the physician's criteria. Light-based interventions should be used with caution because of skin sensitivity.<sup>2</sup>

Other treatments are surgical intervention (sympathectomy), botulinum toxin, and local cold stimuli.<sup>4</sup>

Few NR cases are described, and there still exist gaps in its management. Our patient had a successful response to neuromodulators and IPL without side effects. This combination has not been previously reported.

## Financial support

None declared.

## Authors' contributions

Andrea Paola Cespedes Pérez: Adequate the study concept and design; writing of the manuscript; research guidance; critical review of the literature; critical review of the manuscript; approval of the final version of the manuscript.

Diana Isabel Conde Hurtado: Adequate the study concept and design; writing of the manuscript; research guidance; critical review of the literature; critical review of the manuscript; approval of the final version of the manuscript.




Ricardo Flaminio Rojas López: Adequate the study concept and design; acquisition of data, analysis of data; intellectual participation in propaedeutic and/or therapeutic conduct of the studied case; writing of the manuscript; critical review of the literature; critical review of the manuscript; approval of the final version of the manuscript.

## Conflicts of interest

Dr. Ricardo Flaminio Rojas is an advisory board member and speaker at Galderma.

## References

1. Gregory P, Ajeet M. Neurogenic rosacea: an uncommon and poorly recognized entity. *J Am Acad Dermatol.* 2015;72:AB54.
2. Scharschmidt TC, Yost JM, Truong SV, Steinhoff M, Wang KC, Berger TG. Neurogenic rosacea: a distinct clinical subtype requiring a modified approach to treatment. *Arch Dermatol.* 2011;147:123–6.
3. Jae Eun Choi ADN. Skin neurogenic inflammation. *Semin Immunopathol.* 2018;40:249–59.
4. Kim HO, Kang SY, Kim KE, Cho SY, Kim KH, Kim IH. Neurogenic rosacea in Korea. *J Dermatol.* 2020;48:1–7.
5. Eskeland S, Halvorsen JA, Tanum L. Antidepressants have anti-inflammatory effects that may be relevant to dermatology: a systematic review. *Acta Derm Venereol.* 2017;97:897–905.

Diana Isabel Conde Hurtado \*,  
Andrea Paola Céspedes Pérez ,  
Ricardo Flaminio Rojas López 

*DermaHair Center, Floridablanca, Colombia*

\* Corresponding author.

E-mail: [dconde@unab.edu.co](mailto:dconde@unab.edu.co) (D.I. Hurtado).

Received 5 June 2022; accepted 5 September 2022

Available online 14 December 2023

<https://doi.org/10.1016/j.abd.2022.09.016>

0365-0596/ © 2023 Sociedade Brasileira de Dermatologia.

Published by Elsevier España, S.L.U. This is an open access article under the CC BY license (<http://creativecommons.org/licenses/by/4.0/>).

## Pediatric case of trichilemmal cyst arising on the face<sup>☆</sup>

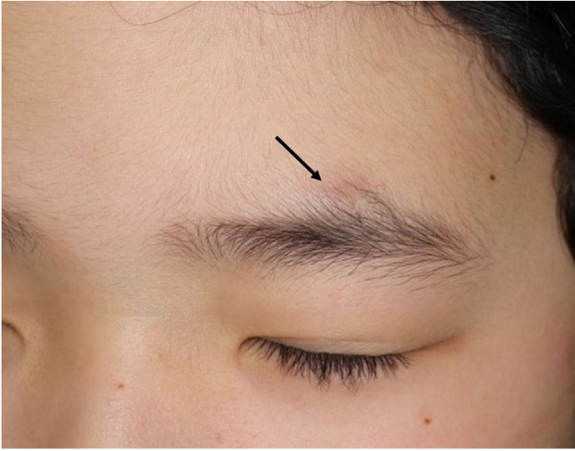


Dear Editor,

Trichilemmal cyst is sometimes seen in the scalp of adults. We herein describe a rare case of a trichilemmal cyst arising on the forehead of a child.

A 9-year-old boy visited our hospital, complaining of a nodule above the left eyebrow that had increased in size over the previous year. He had no past medical history, and he and his parents denied any prior triggering events such as trauma on this site. Physical examination showed a 7 × 5 mm, normal skin-colored, slightly dome-shaped subcutaneous nodule (Fig. 1). Laboratory examination was normal. The nodule was surgically removed under local anesthesia. Histopathological examination revealed a relatively well-circumscribed cystic structure located in the subcutaneous tissue (Fig. 2A). The cyst was filled with acidophilic amorphous substances, and the cyst walls consisted of

<sup>☆</sup> Study conducted at the Department of Dermatology, Fukushima Medical University, Fukushima, Japan.



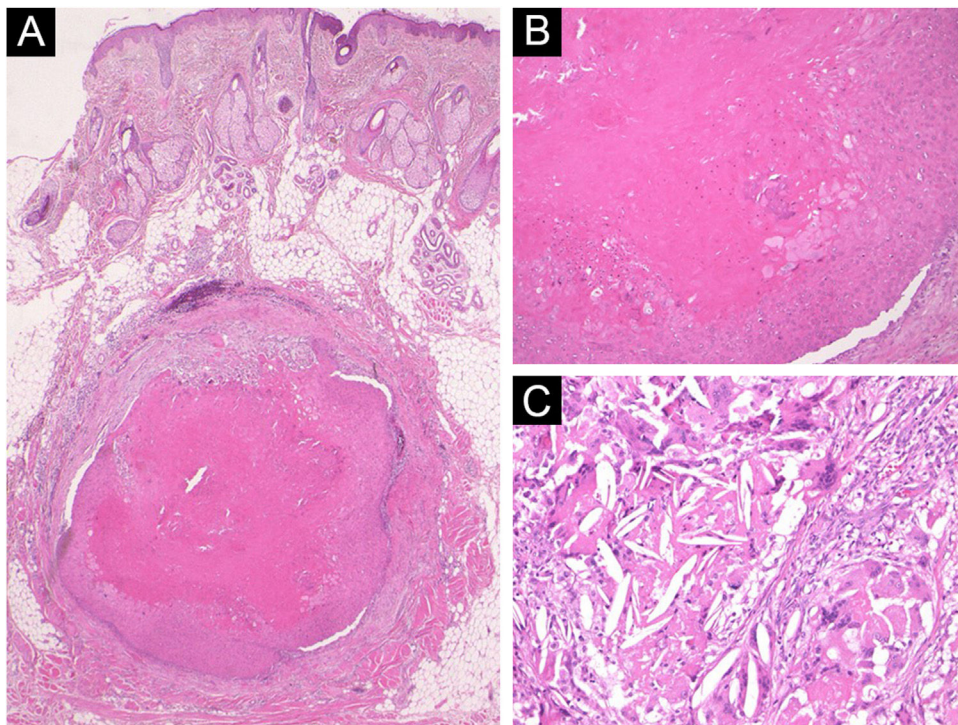
**Figure 1** A slightly dome-shaped subcutaneous nodule above the left eyebrow (arrow).

epithelial cells without forming granular cell layers (Fig. 2B). The serial sections of histopathology showed cholesterol crystals and foreign body giant cells within and around the cyst (Fig. 2C). After the surgery was performed, 10 years have passed without local recurrence.

We diagnosed the case as a trichilemmal cyst based on the histopathological features of well-defined cystic structures consisting of epithelial cells showing trichilemmal keratinization. Cholesterol crystals and cholesterol clefts, which are often observed in epidermal cysts, were observed in the present case, but those histopathological features are not diagnostic. The presence of foreign body granu-

loma may suggest previous partial ruptures of trichilemmal cysts. The cyst wall was not adjacent to sebaceous glands, and hair follicles and hair shafts were not observed in and around the cysts. Moreover, the subcutaneous nodule did not exist at birth, and thus dermoid cyst was excluded. Trichilemmal cyst is a benign adnexal tumor that arises from the outer root sheath of a hair follicle. It usually presents as an asymptomatic firm nodule, which at times can be slightly painful. It is mainly seen in areas bearing hair follicles, mostly on the scalp. Middle-aged females are more commonly affected.<sup>1</sup> The onset of a trichilemmal cyst in a young boy is rare. To our knowledge, only 3 cases have been reported which developed trichilemmal cysts under the age of 10, including the present case.<sup>2,3</sup> Clinical findings of these cases are shown in Table 1. The thigh, penis, and eyebrow were involved, which were rare sites. Our patient in the current case is now the youngest among the reported Japanese cases. On the other hand, the youngest case was in a 5-year-old male, who developed a trichilemmal cyst on the penis after hypospadias repair.<sup>3</sup> The authors speculated that the distal hypospadias repair had triggered squamous metaplasia with keratinization, leading to the development of a trichilemmal cyst in a non-hair-bearing area of the body.

In our department, 25 cases including the present case were diagnosed as trichilemmal cysts over the past 10 years. The pediatric case was only 1 (the present case). The patients consisted of 12 males and 13 females, and the mean age was 49 years. The involved sites were most frequently observed in the scalp (n = 16), followed by the face (7), abdomen (1) and forearm (1). Among the facial lesions, 2 were observed in the eyebrow, 2 were observed in the



**Figure 2** (A) Histopathological examination showing a cystic structure located in the subcutaneous tissue (Hematoxylin & eosin,  $\times 20$ ). (B) Higher magnification shows that the cyst walls keratinize towards the lumen without forming granular cell layers (Hematoxylin & eosin,  $\times 200$ ). (C) Cholesterol crystals and foreign body giant cells (Hematoxylin & eosin,  $\times 200$ ).

**Table 1** Summary of the reported cases of pediatric trichilemmal cyst.

Authors	Age/Sex	Site	Size	Clinical features	Color
Imamura H, et al. <sup>2</sup>	10/male	Flexor aspect of thigh	About 15 × 20 mm	Elastic, soft, non-tender nodule	Slightly blue
Madan S, Joshi R. <sup>3</sup>	5/male	Ventral aspect of the frenulum of the penis	15 × 16 mm	Soft, cystic, smooth-surfaced, elastic, non-tender and relatively mobile mass	Unidentified
Our case	9/male	Above eyebrow	7 × 5 mm	Slightly dome-shaped, non-tender subcutaneous nodule	Slightly red

upper and lower eyelids, 2 were observed in the forehead, and 1 was observed in the cheek. Trichilemmal cyst is one of the nodules arising on the head and neck, which rarely involves the children.

### Financial support

None declared.

### Authors' contributions

Mai Endo: Design of the study; writing of the manuscript; data collection, analysis and interpretation; review and approval of the final version of the manuscript.



Toshiyuki Yamamoto: Design of the study; writing of the manuscript; data collection, analysis and interpretation; review and approval of the final version of the manuscript.

### Conflicts of interest

None declared.

### References

- Jha AK, Sinha R, Prasad S, Kumar S. Multiple trichilemmal cysts of the scalp in a young male. *Int J Trichology*. 2015;7:167–9.
- Imamura H, Izumi T, Kimura S. Two cases of trichilemmal cyst on the thigh. *Jpn J Clin Dermatol (in Japanese)*. 1997;51:168–70.
- Madan S, Joshi R. Trichilemmal cyst of the penis in a paediatric patient. *Sultan Qaboos Univ Med J*. 2015;15:e129–132.

Mai Endo \*, Toshiyuki Yamamoto 

*Department of Dermatology, Fukushima Medical University, Fukushima, Japan*

\*Corresponding author.

E-mail: [enmai04@fmu.ac.jp](mailto:enmai04@fmu.ac.jp) (M. Endo).

Received 31 March 2022; accepted 17 June 2022

Available online 14 December 2023

<https://doi.org/10.1016/j.abd.2022.06.015>

0365-0596/ © 2023 Published by Elsevier España, S.L.U. on behalf of Sociedade Brasileira de Dermatologia. This is an open access article under the CC BY license (<http://creativecommons.org/licenses/by/4.0/>).

## Rapidly involuting congenital haemangioma (RICH) associated with transient thrombocytopenia and coagulopathy\*



Dear Editor,

A full-term male infant was born by natural delivery, with a vascular tumor in the right thigh of 10 × 5 cm in diameter, with central ulceration and no adhered to deep planes, since birth (Fig. 1). He was transferred to the neonatal intensive care unit at 3 hours of life after detecting hypoprothrombinemia (24% prothrombin activity), prothrombin time: 36.8

seconds (range: 9–12), no signs of hemolytic anemia, normal bilirubin, and normal platelet count, he was treated with vitamin K and 2 infusions of fresh frozen plasma. He presented with moderate thrombocytopenia (60 × 10<sup>9</sup>/L) on the fourth day of life, which remitted along with rapid involution of the tumor. At 2 weeks of life, the tumor has completely resolved leaving a residual subcutaneous atrophy.

He was treated from birth with prednisone 2 mg/kg/day for 5 days with withdrawal after improvement of the tumor. Given the clinical picture of a congenital vascular tumor with rapid involution, the diagnosis of rapidly involuting congenital hemangioma (RICH) was made, with no need for a biopsy.

With the diagnosis of RICH-associated coagulopathy, the patient has been followed up for 8 months with a very important regression of the lesion (Fig. 2).

\* Study conducted at the Dermatology Service, Hospital Miguel Servet, Zaragoza, Spain.