

Table 1 Summary of the reported cases of pediatric trichilemmal cyst.

Authors	Age/Sex	Site	Size	Clinical features	Color
Imamura H, et al. ²	10/male	Flexor aspect of thigh	About 15 × 20 mm	Elastic, soft, non-tender nodule	Slightly blue
Madan S, Joshi R. ³	5/male	Ventral aspect of the frenulum of the penis	15 × 16 mm	Soft, cystic, smooth-surfaced, elastic, non-tender and relatively mobile mass	Unidentified
Our case	9/male	Above eyebrow	7 × 5 mm	Slightly dome-shaped, non-tender subcutaneous nodule	Slightly red

upper and lower eyelids, 2 were observed in the forehead, and 1 was observed in the cheek. Trichilemmal cyst is one of the nodules arising on the head and neck, which rarely involves the children.

Financial support

None declared.

Authors' contributions

Mai Endo: Design of the study; writing of the manuscript; data collection, analysis and interpretation; review and approval of the final version of the manuscript.



Toshiyuki Yamamoto: Design of the study; writing of the manuscript; data collection, analysis and interpretation; review and approval of the final version of the manuscript.

Conflicts of interest

None declared.

References

- Jha AK, Sinha R, Prasad S, Kumar S. Multiple trichilemmal cysts of the scalp in a young male. *Int J Trichology*. 2015;7:167–9.
- Imamura H, Izumi T, Kimura S. Two cases of trichilemmal cyst on the thigh. *Jpn J Clin Dermatol (in Japanese)*. 1997;51:168–70.
- Madan S, Joshi R. Trichilemmal cyst of the penis in a paediatric patient. *Sultan Qaboos Univ Med J*. 2015;15:e129–132.

Mai Endo *, Toshiyuki Yamamoto 

Department of Dermatology, Fukushima Medical University, Fukushima, Japan

*Corresponding author.

E-mail: enmai04@fmu.ac.jp (M. Endo).

Received 31 March 2022; accepted 17 June 2022

Available online 14 December 2023

<https://doi.org/10.1016/j.abd.2022.06.015>

0365-0596/ © 2023 Published by Elsevier España, S.L.U. on behalf of Sociedade Brasileira de Dermatologia. This is an open access article under the CC BY license (<http://creativecommons.org/licenses/by/4.0/>).

Rapidly involuting congenital haemangioma (RICH) associated with transient thrombocytopenia and coagulopathy*



Dear Editor,

A full-term male infant was born by natural delivery, with a vascular tumor in the right thigh of 10 × 5 cm in diameter, with central ulceration and no adhered to deep planes, since birth (Fig. 1). He was transferred to the neonatal intensive care unit at 3 hours of life after detecting hypoprothrombinemia (24% prothrombin activity), prothrombin time: 36.8

seconds (range: 9–12), no signs of hemolytic anemia, normal bilirubin, and normal platelet count, he was treated with vitamin K and 2 infusions of fresh frozen plasma. He presented with moderate thrombocytopenia (60 × 10⁹/L) on the fourth day of life, which remitted along with rapid involution of the tumor. At 2 weeks of life, the tumor has completely resolved leaving a residual subcutaneous atrophy.

He was treated from birth with prednisone 2 mg/kg/day for 5 days with withdrawal after improvement of the tumor. Given the clinical picture of a congenital vascular tumor with rapid involution, the diagnosis of rapidly involuting congenital hemangioma (RICH) was made, with no need for a biopsy.

With the diagnosis of RICH-associated coagulopathy, the patient has been followed up for 8 months with a very important regression of the lesion (Fig. 2).

* Study conducted at the Dermatology Service, Hospital Miguel Servet, Zaragoza, Spain.

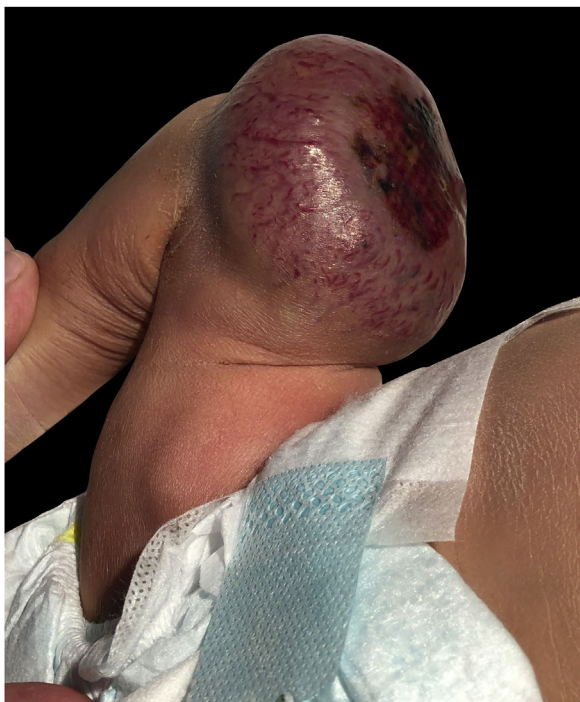

Figure 1 10 × 9 cm vascular tumor, image taken at birth, necrotic ulcerated plaque is observed on the surface of the tumor.

Discussion

Coagulopathy and thrombocytopenia are complications that may appear in some vascular tumors, especially when they reach a large volume, due to thromboembolic complications and potential hemodynamic repercussions. The main differential diagnosis that should be considered in this patient is Kasabach-Merritt Syndrome (KMS), a life-threatening thrombocytopenic coagulopathy associated with rare vascular tumors, such as Kaposiform hemangioendothelioma, and less frequently with tufted angioma but not with common infantile or congenital hemangiomas.¹

Unlike the persistent coagulopathy seen with KMS,¹ the thrombocytopenia which appears in RICH commonly does not disturb coagulation factors or is not as pronounced, and then normalizes in the first month of life.²

In the literature published as RICH and transient thrombocytopenia, there are only 11 cases described, including the case that we have reported, all of them are summarized in Table 1.^{1,3-5}

Thrombocytopenia in RICH may correlate with the size of the tumor because it has never been reported in RICHs of less than 5 cm, ranging up to 13 cm.

A male predominance was evident (sex ratio 2.3). The lesions were located in the extremities in 63.63% of the cases, which has already been previously demonstrated that the most common CH location was on the limbs. Regarding thrombocytopenia, in all of the patients it occurred in the first days of life, resolving in the majority of cases before 2 weeks. Most of them (72.72%) were treated with oral pred-

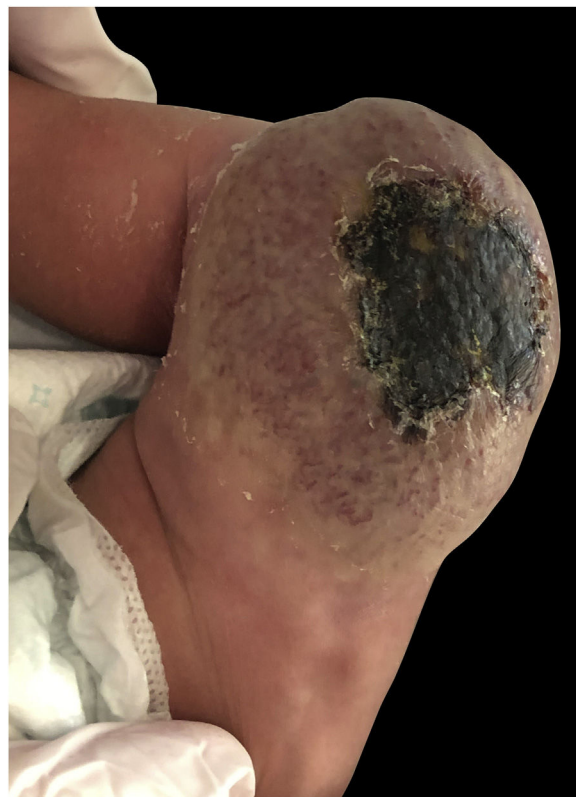

Figure 2 Progressive decrease in the volume of the tumor was seen 6 months of subsequent follow-up in consultation, disappearing ulceration with central necrosis and a persistent redundant skin plaque with residual surface telangiectasia.

nison in the range of 2 mg kg daily with a minimum of 4 days and a maximum of 2 months. Finally, 100% of the lesions regressed spontaneously within the first year of life.

In conclusion, this association may be underreported and underdiagnosed since platelet count and coagulation studies are not routinely ordered in the evaluation of RICH.

Financial support

None declared.

Authors' contributions

APR, TG, CCR and YG contributed to the preparation of manuscript and critically modified. APR and TGC contributed in the preparation of figures. All authors contributed to the article and approved the submitted version.

Conflict of interest





None declared.

Table 1 Summary of all cases published to date of RICH-type hemangioma and associated thrombocytopenia.

	Sex	Glut-1	Size	Location	Platelet	Start of thrombocytopenia	Resolution of thrombocytopenia	Clinical signs of regression of hemangioma	Treatment
Baselga et al. ¹	Male	Negative	6 × 7 × 1.5 cm	Scalp	56 (×10 ⁹ L ⁻¹)	Day 5	14 days	6 months (resected)	Surgical removal
Baselga et al. ¹	Female	Negative	8 × 8 cm	Arm	62 (×10 ⁹ L ⁻¹)	Day 4	14 days	14 days	Oral PDN for 4 days and embolization
Baselga et al. ¹	Male	Negative	NA	Leg	5 (×10 ⁹ L ⁻¹)	Day 2	7 days	5 days	Oral PDN, 1 month; platelet transfusion day 2
Baselga et al. ¹	Male	NA	8 × 5 × 2.5 cm	Thorax	7 (×10 ⁹ L ⁻¹)	Day 1	30 days	NA	Embolization
Baselga et al. ¹	Male	NA	5.1 × 4.1 cm	Thigh	19 (×10 ⁹ L ⁻¹)	Day 2	11 days	11 days	Intravenous dexamethasone, oral PDN
Baselga et al. ¹	Female	NA	10 × 8 cm	Arm	21 (×10 ⁹ L ⁻¹)	Day 8	60 days	2 months	Oral PDN, 2 months
Baselga et al. ¹	Male	NA	11 × 13 cm	Leg	30 (×10 ⁹ L ⁻¹)	Day 12	30 days	NA	Oral PDN, 2 months
Braun et al. ³	NA	NA	NA	NA	102 –108 g/L	Day 2-9	NA	NA	None
Andreu-Barasoain et al. ⁴	Male	NA	6 cm	Arm	34 (×10 ⁹ L ⁻¹)	Day 16	1 month	1 year	Oral PDN for 1 month
Rangwala et al. ⁵	Female	NA	7.5 × 9.3 cm	Arm	3 (×10 ⁹ L ⁻¹)	Day 10	2 week	1 month	A single platelet transfusion; Oral PDN for 5 days; Propranolol 1 mg/kg daily (1 month); flecainide; and a 6-week prednisolone taper.
Palma et al.	Male	NA	10 × 5 cm	Thigh	60 (×10 ⁹ L ⁻¹)	Day 4	2 weeks	2 weeks	Vitamin K and 2 infusions of fresh frozen plasma; Oral PDN for 5 days

References

- Baselga E, Cordisco MR, Garzon M, Lee MT, Alomar A, Blei F, et al. Rapidly involuting congenital haemangioma associated with transient thrombocytopenia and coagulopathy: a case series. *Br J Dermatol.* 2008;158:1363–70.
- Sarkar M, Mulliken JB, Kozakewich HP, Robertson RL, Burrows PE. Thrombocytopenic coagulopathy (Kasabach–Merritt phenomenon) is associated with kaposiform hemangioendothelioma and not with common infantile hemangioma. *Plast Reconstr Surg.* 1997;100:1377–86.
- Braun V, Prey S, Gurioli C, Boralevi F, Taieb A, Grenier N, et al. Congenital haemangiomas: a single-centre retrospective review. *BMJ Paediatr Open.* 2020;4:e000816.
- Andreu-Barasoain M, Naz E, Díaz M, López-Esteban JL. Rapidly involuting congenital hemangioma associated with transient anemia and thrombocytopenia. *Int J Dermatol.* 2013;52:1025–6.
- Rangwala S, Wysong A, Tollefson MM, Khuu P, Benjamin LT, Bruckner AL. Rapidly involuting congenital hemangioma associated with profound, transient thrombocytopenia. *Pediatr Dermatol.* 2014;31:402–4.

Ana María Palma ^{a,b}, Tamara Gracia-Cazaña ^{a,b,*},
Carmen Ruiz de la Cuesta-Martín ^c, Yolanda
Gilaberte ^{a,b}

^a *Dermatology Service, Hospital Miguel Servet, Zaragoza, Spain*

^b *IIS Aragon, Zaragoza University, Zaragoza, Spain*

^c *Pediatric Service, Hospital Miguel Servet, Zaragoza, Spain*

* Corresponding author.

E-mail: tamgracaz@gmail.com (T. Gracia-Cazaña).

Received 6 March 2022; accepted 20 June 2022

Available online 21 December 2023

<https://doi.org/10.1016/j.abd.2022.06.014>

0365-0596/ © 2023 Sociedade Brasileira de Dermatologia.

Published by Elsevier España, S.L.U. This is an open access article under the CC BY license (<http://creativecommons.org/licenses/by/4.0/>).

Solitary palmar adult xanthogranuloma[☆]



Dear Editor,

A 45-year-old woman with a history of breast cancer two years earlier, consulted for an enlarging asymptomatic lesion on the right palm which had appeared 4 months prior to consultation. During physical examination, she presented a 5 mm dome-shaped yellowish papule with a desquamative peripheral rim (Fig. 1A). Dermoscopy revealed homogeneous symmetric yellow structure-less areas with a central crust and pink surrounding rim ('setting sun' pattern) (Fig. 1B). Skin ultrasound revealed a round hypoechoic lesion occupying dermis and hypodermis, with multiple peripheral small vessels (Fig. 2). A benign adnexal tumor was suspected, but a cutaneous metastasis needed to be ruled out. Complete lesion excision revealed a dermal proliferation of mononucleated foamy histiocytes and Touton's giant cells, which were positive for CD68 and negative for S100 and CD1a immunohistochemical stains (Fig. 3). A diagnosis of solitary adult xanthogranuloma was made. After complete excision, the lesion has not recurred. The patient remains in complete remission of her breast carcinoma.

Adult xanthogranuloma is a subtype of non-Langerhans Cell Histiocytosis (LCH) belonging to the xanthogranuloma family, classified into the C ('Cutaneous') group of the revised classification of histiocytoses.¹ Adult xanthogranuloma is histologically identical to Juvenile Xanthogranuloma (JXG), the most common non-LCH. It usually presents in males in the first two decades of life, and the most common presentation is a solitary asymptomatic papule or nodule varying from 5 mm to 1–2 cm in size, with a translucent, smooth, yellowish to brownish surface and occasional telangiectasias. In adults, this lesion tends to persist over time, rather than involute with time as in children. Adult and juvenile xanthogranulomas are usually located in the head and neck region, followed by the trunk and extremities; however, all cutaneous locations have been described, including palms and soles.² Case reports including cases of JXG on the volar surfaces (palms and soles) have described unusual colors appearing in this location, such as dull red or flesh-colored, and a well-defined hyperkeratotic peripheral rim upon dermoscopy.³ Typical dermoscopic findings of adult and juvenile xanthogranuloma include a yellow/orange and red/pink homogeneous background, often referred to as the 'setting sun' pattern.⁴ Clinical dif-

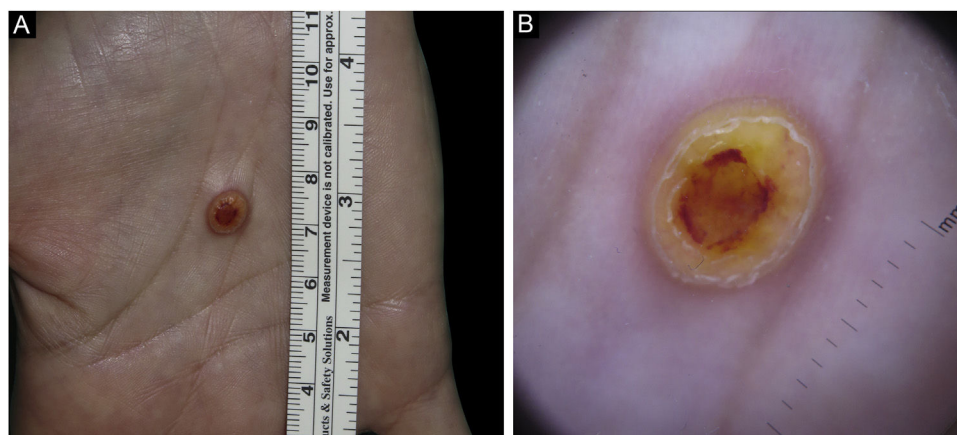


Figure 1 Solitary adult xanthogranuloma of the palm. (A) Yellowish 5 mm dome-shaped papule with central erythematous crust and a desquamative erythematous peripheral rim. (B) Dermoscopy showing homogeneous symmetric yellow structure-less areas with a central crust and pink surrounding rim ('setting sun' pattern).

[☆] Study conducted at the Hospital Clínic de Barcelona, Barcelona, Catalonia, Spain.