







4. Lyakhovitsky A, Segal O, Maly A, Zlotogorski A, Barzilai A. Permanent chemotherapy-induced alopecia after hematopoietic stem cell transplantation treated with low-dose oral minoxidil. *JAAD Case Rep.* 2022;22:64–7.
5. John JM, Sinclair RD. Systemic minoxidil for hair disorders in pediatric patients: a safety and tolerability review. *Int J Dermatol.* 2023;62:257–9.

Raíssa Rodriguez Melo <sup>a,\*</sup>,  
 Rita Fernanda Cortez de Almeida <sup>a</sup>,  
 Luciana Rodino Lemes <sup>a</sup>, Sidney Frattini Junior <sup>b</sup>,  
 Paulo Müller Ramos <sup>c</sup>, Daniel Fernandes Melo <sup>d</sup>

<sup>a</sup> *Dermatology Department, Universidade do Estado do Rio de Janeiro, Rio de Janeiro, RJ, Brazil*

<sup>b</sup> *The Mole Clinic, Private Practice, Ancaster, Ontario, Canada*

<sup>c</sup> *Department of Infectious Diseases, Dermatology, Imaging Diagnosis and Radiotherapy, Faculty of Medicine, Universidade Estadual Paulista, Botucatu, SP, Brazil*

<sup>d</sup> *Dermatology Department, Universidade do Estado do Rio de Janeiro (UERJ), Rio de Janeiro, RJ, Brazil*

\* Corresponding author.

E-mail: [rodriguezraissaa@gmail.com](mailto:rodriguezraissaa@gmail.com) (R.R. Melo).

Received 20 June 2023; accepted 5 July 2023

<https://doi.org/10.1016/j.abd.2023.07.010>

0365-0596/ © 2024 Sociedade Brasileira de Dermatologia.

Published by Elsevier España, S.L.U. This is an open access article under the CC BY license (<http://creativecommons.org/licenses/by/4.0/>).

## Mesalamine-induced photosensitivity – A case report and literature review<sup>☆</sup>



Dear Editor,

We present a case of mesalamine-induced photosensitivity in a patient with Ulcerative Colitis (UC). To the best of our knowledge, this is the fourth case of mesalamine-induced photosensitivity reported so far.<sup>1–3</sup>

In April 2018, a 26-year-old male presented with diffuse erythema and erythematous papules on sun-exposed areas (Figs. 1 and 2). Skin lesions appeared during the first sunny spring days (average UV index was 5 – moderate). He has no previous history of sun sensitivity. In personal history, five weeks before admission to our department, he started treatment for UC. Treatment included oral and rectal forms of mesalamine alongside oral prednisolone and esomeprazole.

At admission routine laboratory analysis of blood and urine were within normal limits. Immunological analysis (IgG, IgM anti-cardiolipin antibodies, IgG anti-mitochondrial antibodies, IgG anti-nucleus antibodies, IgG anti-smooth muscle antibodies, IgG anti-liver kidney microsome type 1 antibodies, IgG anti-parietal antibodies, anti-Extractable Nuclear Antigen (ENA) antibody screen, IgG anti-dsDNA, C3 and C4) were all negative. HIV antigen/antibody, HBsAg, and anti-HCV were all negative. VDRL was negative. Lupus bend tests from sun-exposed and sun-protected areas were negative.

We suggested sun protection along with sun avoidance and initiated topical corticosteroid preparations with concomitant UC treatment (mesalamine 3g/day, prednisolone 20mg/day and esomeprazole 20mg BID) for 4 days. The suggested treatment was without result, erythema was persistent. Due to suspicion that sun sensitivity was induced by mesalamine, mesalamine and topical corticosteroid treatment were discontinued and 20 mg of prednisolone alongside

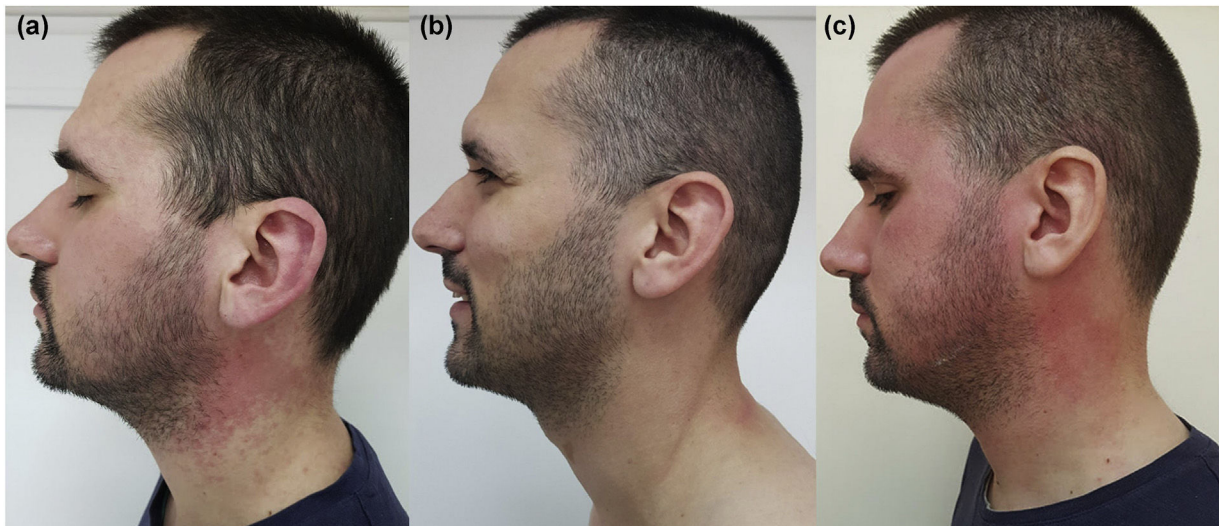esomeprazole and sun protection remain the only treatment. During the following 4 days, he spent up to 1 hour/day in the sun and despite that, there was a complete regression of skin lesions (Figs. 1 and 2).

We were interested on whether photosensitivity appears again in the absence of mesalamine so, we suggested unlimited sun exposure without sun protection, for the next 6 days (10 days in total without mesalamine). During those days were no signs of photosensitivity, but UC worsened and mesalamine re-challenge was approached. He took the first, reintroduced, dose of mesalamine and 12–15 h later, he spent 30 minutes outside on a sunny morning. During those 30 minutes, erythema reappeared on sun-exposed areas. We established the diagnosis of mesalamine-induced photosensitivity (Figs. 1 and 2). The gastroenterologist substituted mesalamine with azathioprine and prednisolone was tapered and stopped. UC has been in remission since October 2018, and as of April 2023, he has no manifestations of sun sensitivity.

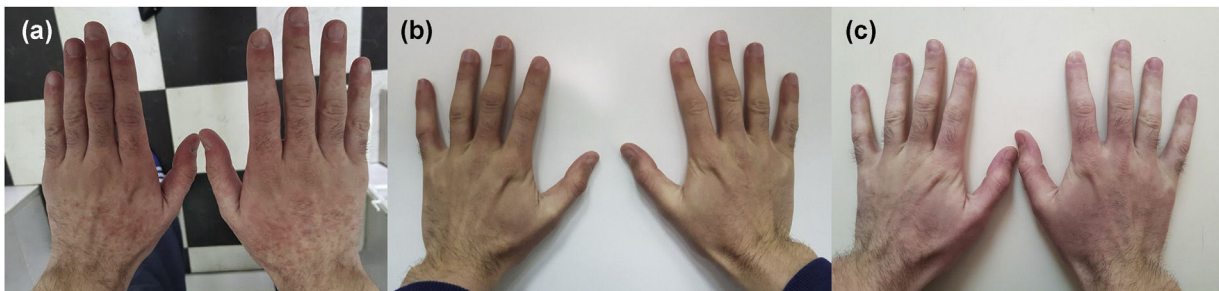Mesalamine is the preferred, safe, first-line treatment with proven efficacy in mild to moderate forms of UC<sup>4</sup> with mild systemic absorption despite its delayed release mechanism.<sup>5</sup> According to the literature mesalamine may be associated with skin rashes and pruritus.<sup>4,5</sup>

Many drugs have been implicated in photosensitive reactions but mesalamine is not considered to be one.<sup>6,7</sup> Only one case of probable esomeprazole-induced photoallergic dermatitis has been reported so far.<sup>8</sup> Cutaneous adverse drug reactions in sun-exposed areas may be phototoxic or photo-allergic type.<sup>6</sup> Photo-toxicity appears rapidly after sun exposure because of light activation of the photosensitizing agent, while photoallergy skin lesion appears after 2–3 days due to activation of cell-mediated immune response.<sup>7</sup> Esomeprazole was not in the treatment protocol in other reported cases with mesalamine-induced photosensitivity.<sup>1–3</sup> In our patient photosensitivity was not associated with esomeprazole intake. The proof for that is that he had no skin lesions while being treated with esomeprazole in periods when mesalamine was temporarily or permanently withdrawn. The prompt reappearance of erythema in our patient after mesalamine re-challenge indicates a phototoxic type of photosensitivity.

<sup>☆</sup> Study conducted at the Department of Dermatovenereology School of Medicine, University of Belgrade, Clinic of Dermatovenereology University Clinical Center of Serbia, Belgrade, Serbia



**Figure 1** (A) Erythema and erythematous papules on the cheeks, auricles, and neck. (B) Face, auricles, and neck without skin lesions. (C) Erythema and erythematous papules on the scalp, face, auricles, and neck.



**Figure 2** (A) Erythema and erythematous papules on dorsal side of the hands. (B) Dorsal side of the hands without skin lesions. (C) Erythema on dorsal side of the hands.

**Table 1** Cases of mesalamine induced photosensitivity reported in the literature.

	Patient age at presentation	Onset of symptoms after mesalamine introduction	Season at the time of onset of skin lesions	Symptom resolution after mesalamine discontinuation	Mesalamine re-exposure
<b>Our patient</b>	26	5 weeks	Spring	4 days	Yes
<b>Al-Niaimi et al.</b>	56	2–3 months	Summer	10 days	No
<b>Cozzani et al.</b>	46	6 months	Summer	6 months	No
<b>Horiuchi et al.</b>	48	2 weeks	Spring	NA	NA

NA, Not applicable (mesalamine not discontinued).

Among all published cases (Table 1.) our case is the only case with discontinuation of mesalamine treatment and a re-challenge test. In accordance with the Naranjo ADR probability scale,<sup>9</sup> the strength of association between mesalamine and the development of (sun) photosensitivity in our patient was “definite” (total score 9).

In reported cases, the period of photosensitivity onset after mesalamine introduction ranged from 2 weeks to 6 months (Table 1). In our patient, erythema completely disappeared within 4 days after mesalamine was withdrawn similar to Al-Niaimi et al. reported resolution within 10 days.<sup>1</sup> However, Cozzani et al. reported complete resolution 6 months after discontinuation of mesalamine.<sup>2</sup> Interestingly Horiuchi et al. never withdrew mesalamine and reportedly symptoms were controlled by sun protection.

To conclude, we believe that dermatologists should be aware of photosensitivity as a possible mesalamine side effect, to avoid unnecessary clinical evaluations.

### Financial support

None declared.

### Author's contributions

Svetlana Popadic: The study concept and design; data collection, or analysis and interpretation of data; statistical analysis; writing of the manuscript or critical review of important intellectual content; data collection, analysis,

and interpretation; effective participation in the research guidance; intellectual participation in the propaedeutic and/or therapeutic conduct of the studied cases; critical review of the literature; final approval of the final version of the manuscript.

Igor Kapetanovic: Writing of the manuscript or critical review of important intellectual content; data collection, analysis and interpretation; final approval of the final version of the manuscript.

Aleksandra Sokic-Milutinovic: Intellectual participation in the propaedeutic and/or therapeutic conduct of the studied cases; critical review of the literature; final approval of the final version of the manuscript.

## Conflicts of interest

None declared.




## Acknowledgment

This study was partially supported by the Serbian Ministry of Education and Science (Grant n<sup>o</sup> 451-03-47/2023-01/200110).

## References

- Horiuchi Y, Shimakura S. Mesalazine and photosensitivity. *Am J Gastroenterol.* 1999;94:3386–7.
- Cozzani E, Pappalardo F, Gallo R, Parodi A. Photosensitivity induced by mesalazine: report of a case. *Am J Gastroenterol.* 2014;109:923–4.
- Al-Niaimi F, Lyon C. Mesalazine-induced photosensitivity. *Eur J Dermatol.* 2011;21:105–6.
- Klotz U. The pharmacological profile and clinical use of mesalazine (5-aminosalicylic acid). *Arzneimittelforschung.* 2012;62:53–8.

- Moum B. Which are the 5-ASA compound side effects and how is it possible to avoid them? *Inflamm Bowel Dis.* 2008;14:S212–13.
- Glatz M, Hofbauer GF. Phototoxic and photoallergic cutaneous drug reactions. *Chem Immunol Allergy.* 2012;97:167–79.
- Monteiro AF, Rato M, Martins C. Drug-induced photosensitivity: photoallergic and phototoxic reactions. *Clin Dermatol.* 2016;34:571–81.
- Shukla A, Mahapatra A, Gogtay N, Khopkar U. Esomeprazole-induced photoallergic dermatitis. *J Postgrad Med.* 2010;56:229–31.
- Naranjo CA, Busto U, Sellers EM, Sandor P, Ruiz I, Roberts EA, et al. A method for estimating the probability of adverse drug reactions. *Clin Pharmacol Ther.* 1981;30:239–45.

Svetlana Popadic  a,b,\* , Igor Kapetanovic  b , Aleksandra Sokic-Milutinovic  c,d

<sup>a</sup> Department of Dermatology and Venereology, Faculty of Medicine, University of Belgrade, Belgrade, Serbia

<sup>b</sup> Clinic of Dermatovenereology, University Clinical Center of Serbia, Belgrade, Serbia

<sup>c</sup> Department of Gastroenterology and Hepatology, Faculty of Medicine, University of Belgrade, Belgrade, Serbia

<sup>d</sup> Clinic for Gastroenterology and Hepatology, Clinical Center of Serbia, Belgrade, Serbia

\* Corresponding author.

E-mail: [scpopadic@gmail.com](mailto:scpopadic@gmail.com) (S. Popadic).

Received 24 April 2023; accepted 10 July 2023

<https://doi.org/10.1016/j.abd.2023.07.001>  
0365-0596/ © 2023 Published by Elsevier España, S.L.U. on behalf of Sociedade Brasileira de Dermatologia. This is an open access article under the CC BY license (<http://creativecommons.org/licenses/by/4.0/>).

## Oral isotretinoin for the treatment of chronic pityriasis versicolor: case report and literature review<sup>☆</sup>



Dear Editor,

Pityriasis versicolor (PV) is a superficial mycosis caused by yeast species of the *Malassezia* genus. It affects individuals worldwide, mostly in countries with tropical and subtropical climates, where the incidence can reach up to 50% of the population.<sup>1</sup> Propaedeutic and complementary methods such as the Zireli sign, dermoscopy, and Wood's light are useful both in the diagnosis of the infection and in evaluating the therapeutic response by helping to differentiate between active disease and post-inflammatory hypochromia.<sup>1–4</sup>

Treatment is especially challenging in cases of recurrent or chronic evolution, not due to the pathogen intrinsic

resistance to antifungals used topically and systemically, but due to individual host factors present in the human microbiome that favor an environment suitable for the persistence of the lipophilic fungus.<sup>3,5</sup> Scientific studies on the use of oral isotretinoin as an alternative to treat infection are scarce, the vast majority of which are case reports.<sup>6–8</sup> The authors report on a patient with chronic PV without improvement following classical treatments based on antifungals, he showed a good response after a few weeks of oral isotretinoin use.

A 40-year-old healthy male patient, undergoing dermatological follow-up for eight years due to chronic PV was evaluated. During the period, he had undergone several treatments with antiseborrheic soaps, topical antifungals in shampoo, cream and spray lotion formulations (ciclopirox olamine and azole derivatives), in addition to oral treatments with ketoconazole, itraconazole and fluconazole, with little improvement and always maintaining a positive Zireli sign, compatible with active infection.<sup>2,4</sup> Dermatological examination revealed diffusely oily skin and PV in a follicular pattern. The patient denied using creams and emollients, and the habit of taking two showers a day. Considering the chronic condition with resistance to classic therapies and oily skin characteristics, general laboratory

<sup>☆</sup> Study conducted at the Dermatology Clinic, Hospital da Santa Casa de São Paulo, São Paulo, SP, Brazil.