

LETTER - TROPICAL/INFECTIOUS AND PARASITIC DERMATOLOGY

Erythema nodosum triggered by kerion celsi in pediatrics: literature review and case report[☆]



Dear Editor,

Kerion celsi (KC) is a highly inflammatory tinea capitis (TC), occurring predominantly in children of rural areas, and increasingly in urban areas, as pets represent important infection reservoirs.¹ Causative agents of tinea capitis encompass a great variety of dermatophytes, whose prevalence is geographically influenced: *Microsporum canis* represents the most common agent in Europe, China and South America; *Trichophyton tonsurans* in North America and in the UK.^{2,3}

The occurrence of erythema nodosum (EN), a septal panniculitis uncommon in children, after KC, can be considered amongst dermatophyte id (dermatophytid) reactions.⁴⁻⁶ This association was rarely described in literature, especially in children, with only 17 cases reported in English literature in this age group, mainly after *Trichophyton mentagrophytes* scalp infections and mainly after antifungal treatment.^{7,8} Conversely, EN appearing before the administration of antifungal therapy for KC as in the presented case, is unusual, only 5 cases are reported in the literature (Table 1).

We report the case of a seven-year-old boy who presented an erythematous, tender plaque of the scalp one month prior to the visit, and bilateral painful erythematous nodules of the lower extremities for the past ten days. Topical and oral antibacterial antibiotics were not effective.

During clinical examination a painful occipital plaque was observed (3 × 4 cm), erythematous, with pustules and crust, and loose hair falling out from its exudative surface, combined with occipital lymphadenitis (Fig. 1). On the lower extremities, painful and warm erythematous-violaceous nodules were evidenced, clinically suggestive for EN (Fig. 2).

Microscopic examination of skin scrapings and hair confirmed the diagnosis of zoophilic dermatophytosis of the scalp caused by *M. canis* (Fig. 3), which was treated with Griseofulvin 250 mg BID (20 mg/kg/day) for 8 weeks, obtaining remission of both conditions, thus confirming the dermatophytid reactive nature of EN of the legs.

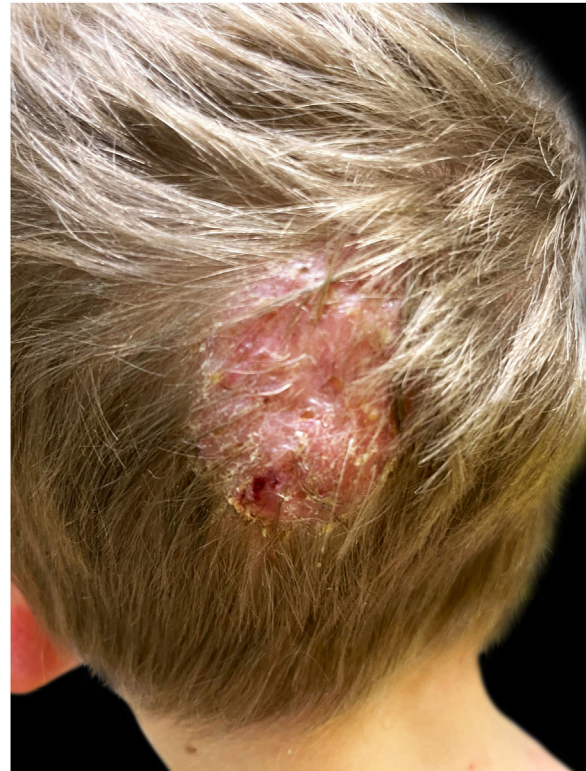

Figure 1 Erythematous purulent and crusted Kerion Celsi of the scalp, with loose hair falling out at the periphery of the lesion.

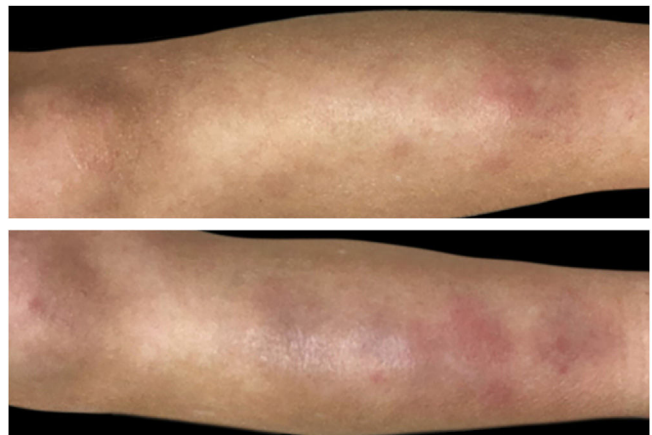


Figure 2 Bilateral erythematous tender nodules of the lower extremities clinically suggestive of erythema nodosum.

[☆] Study conducted at the Giannina Gaslini Institute, GE, Italy.

Table 1 Literature review of pediatric cases of erythema nodosum occurring after Kerion Celsi reported in the English Literature.

1 st author	Publication year	Sex	Age (in years)	Aetiologic agent	Time in days from treatment to en development	Therapy	EN healing time after tp (weeks)
Franks	1952	M	9	<i>T. sulphureum</i>	Before treatment	Griseofulvin	NR
Smith	1963	M	7	<i>T. mentagrophytes</i>	Before treatment	Griseofulvin + topical tioconazole	NR
Stocker	1977	F	12	<i>T. verrucosum</i>	Before treatment	Griseofulvin	NR
Martinez-Roig	1982	M	7	<i>T. mentagrophytes</i>	7	Griseofulvin + topical potassium permanganate solution	NR
Martinez-Roig	1982	M	6	<i>T. mentagrophytes</i>	7	Griseofulvin + topical potassium permanganate solution	NR
Martinez-Roig	1982	M	8	<i>T. mentagrophytes</i>	7	Griseofulvin + topical potassium permanganate solution	NR
De las Heras	1991	M	9	<i>T. mentagrophytes</i>	before treatment	Griseofulvin + topical tioconazole	6
Calista	2001	F	5	<i>T. mentagrophytes</i>	before treatment	Griseofulvin + topical crystal violet	6
Soria	2008	M	9	<i>T. mentagrophytes</i>	16	Griseofulvin	NR
Soria	2008	M	11	<i>T. mentagrophytes</i>	26	Griseofulvin + Ibuprofen	NR
Bassi	2009	F	8	<i>T. mentagrophytes</i>	1	Griseofulvin	6
Zaraa	2012	M	7	Large-spore parasitism	18	Griseofulvin + ciclopiroxolamine cream	12
Castriota	2013	F	9	<i>T. mentagrophytes</i>	14	Griseofulvin + topical mupirocin and tioconazole cream + prednisone 1 mg/kg/die	10
Romano	2014	F	4	<i>T. mentagrophytes</i>	2	Griseofulvin + topical imidazole	NR
Salah	2021	M	4	<i>T. mentagrophytes</i>	20	Griseofulvin	In following days
Salah	2021	M	9	<i>T. mentagrophytes</i>	7	Griseofulvin	In following days
Salah	2021	M	14	<i>T. mentagrophytes</i>	14	Griseofulvin	In following days

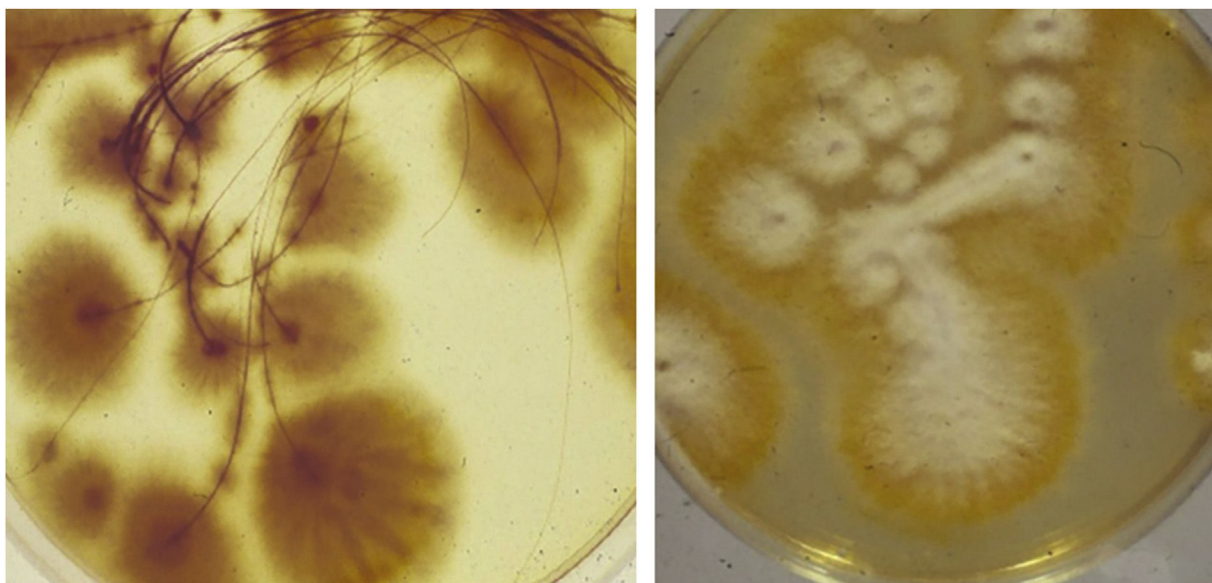


Figure 3 *Microsporium canis* colony growing from hair pulled out at the periphery of the Kerion lesion, forming flat, ivory to white dense cottony colonies.

Id reactions are secondary inflammatory reactions developing from a remote localized immunological insult, such as fungal infections.⁴⁻⁶ Id reactions possibly exhibit multiple clinical presentations, including localized or widespread vesicular lesions, maculopapular or scarlatiniform eruptions, erythema nodosum, erythema multiforme, erythema annulare centrifugum, Sweet's syndrome, guttate psoriasis, and autoimmune bullous disease.^{4,6}

Diagnostic criteria for dermatophytid reaction comprise: (I) A proven dermatophytosis, (II) An eruption in a distant location from fungal infection, and (III) The resolution after antifungal treatment.⁷ On the basis of the abovementioned clinical criteria, we diagnosed clinically an EN-type dermatophytid reaction.

Dermatophytid reactions occur in up to 17% of patients with dermatophyte infections, typically after tinea pedis and, in children, after tinea capitis, mainly presenting as papulo-vesicular eruptions of acral sites and trunk. Also, erythema multiforme, erythema annulare centrifugum, urticarial-manifestations and erythema nodosum, though rarely, have been described.⁶

In literature, EN-type reaction has been mainly described after *T. mentagrophytes* KC (82%) while in the remaining cases *Tricophyton sulphureum*, *Tricophyton verrucosum*, and general large-spore parasitism were reported; mean age at onset was 8 years (range 4–14 years).⁷⁻¹⁰

In literature, the onset of EN-type reactions after KC is variable, uncommonly (30%) before treatment and more frequently near infection climax (70%), after antifungal administration, occurring meanly 12 days (range 26–1 days) after antimycotics.^{7,8} Interestingly, the temporal correlation between inflammation-peak and EN, suggests that a phlogosis-induced massive release of auto-antigens may be in play, supporting an autoimmune hypothesis of reactive T-cells, activated by massive antigenic release, induced by the fungal infection.⁴⁻⁶

Possibly, reactive T-cells, that are activated by antigenic release from a primary stimulus, causing keratinocyte damage, may induce autoimmune-mediated cutaneous phenomena against autologous keratinocyte antigens at distant sites, after lymphocytic dissemination. Indeed, dermatophytid reactions are observed mostly after highly inflammatory forms of dermatophytosis, such as in the presented case, where a great amount of auto-antigens may have been released.⁴⁻⁶

Of note, the diagnosis of Id reactions is essential for the correct management of the patient, as these autoimmune reactions mainly (70%) occur after antimycotic initiation and can be misdiagnosed with allergic reactions to antifungals, leading to erroneous therapy discontinuation.

In our patient, EN occurred twenty days after the clinical manifestation of dermatophytosis, before oral administration of antifungals, avoiding misdiagnosis.

Griseofulvin was administered in all reported cases, comprising the present patient. Topical antimycotics were added in 53%, leading to regression of both EN and KC, highlighting the importance of recognizing the link between the two entities, to provide a correct combined diagnosis of both skin conditions and a sole efficacious therapeutic approach.

Financial support

None declared.

Authors' contributions

Astrid Herzum: Study concept and design; Interpretation of data; statistical analysis; writing of the manuscript; effective participation in the research guidance; critical review of the literature; final approval of the final version of the manuscript.

Ehab Garibeh: Study concept and design; interpretation of data; writing of the manuscript; effective participation in the research guidance; critical review of the literature; final approval of the final version of the manuscript.

Lodovica Gariazzo: Study concept and design; interpretation of data; writing of the manuscript; effective participation in the research guidance; final approval of the final version of the manuscript.

Corrado Occella: Study concept and design; interpretation of data; writing of the manuscript; effective participation in the research guidance; final approval of the final version of the manuscript.






Gianmaria Viglizzo: Study concept and design; interpretation of data; writing of the manuscript; effective participation in the research guidance; final approval of the final version of the manuscript.

Conflicts of interest

None declared.

References

1. John AM, Schwartz RA, Janniger CK. The kerion: an angry tinea capitis. *Int J Dermatol.* 2018;57:3–9.
2. Gupta AK, Mays RR, Versteeg SG, Piraccini BM, Shear NH, Piguet V, et al. Tinea capitis in children: a systematic review of management. *J Eur Acad Dermatol Venereol.* 2018;32:2264–74.
3. Zhan P, Li D, Wang C, Sun J, Geng C, Xiong Z. Epidemiological changes in tinea capitis over the sixty years of economic growth in China. *Med Mycol.* 2015;53:691–8.
4. Trapani S, Rubino C, Lodi L, Resti M, Indolfi G. Erythema nodosum in children: A narrative review and a practical approach. *Children (Basel).* 2022;9:511.
5. Ilkit M, Durdu M, Karakaş M. Cutaneous id reactions: a comprehensive review of clinical manifestations, epidemiology, etiology, and management. *Crit Rev Microbiol.* 2012;38:191–202.
6. Romano C, Gaviria EM, Feci L, Fimiani M. Erythema nodosum complicating kerion of the scalp caused by *Trichophyton mentagrophytes*. *J Eur Acad Dermatol Venereol.* 2016;30:357–9.
7. Calista D, Schianchi S, Morri M. Erythema nodosum induced by kerion celsi of the scalp. *Pediatr Dermatol.* 2001;18:114–6.
8. Bassi N, Kersey P. Erythema nodosum complicating a case of kerion celsi of the scalp due to *Trichophyton mentagrophytes*. *Clin Exp Dermatol.* 2009;34:621–2.
9. Ben Salah N, Korbi M, Soua Y, Youssef M, Belhadjali H, Zili J. Erythema nodosum in patients with kerion of scalp. *Clin Exp Dermatol.* 2021;46:1577–8.
10. Castriota M, Ricci F, Paradisi A, Fossati B, de Simone C, Capizzi R. Erythema nodosum induced by kerion celsi of the scalp in a child: a case report and mini-review of literature. *Mycoses.* 2013;56:200–3.

Astrid Herzum *, Ehab Garibeh ,
Lodovica Gariazzo , Corrado Occella ,
Gianmaria Viglizzo 

Dermatology Unit, IRCCS Giannina Gaslini, Genova, Italy

* Corresponding author.

E-mail: astridherzum@yahoo.it (A. Herzum).

Received 10 February 2023; accepted 25 February 2023

<https://doi.org/10.1016/j.abd.2023.02.009>

0365-0596/ © 2023 Sociedade Brasileira de Dermatologia.

Published by Elsevier España, S.L.U. This is an open access article under the CC BY license (<http://creativecommons.org/licenses/by/4.0/>).

Extensive micropustular *Tinea capitis* in an adult caused by *Trichophyton verrucosum* with evolution to Kerion Celsi*



Dear Editor,

Tinea capitis is a fungal infection that affects mainly school-age children and can present different degrees of inflammation, with the inflammatory type known as *Kerion Celsi* being the most severe of all. Among the etiological agents causing this infection, *Trichophyton verrucosum* is an ectothrix zoophilic dermatophyte, commonly found in cattle, especially in young cattle, but rarely associated with cases of *tinea capitis* in human beings - especially in adults.¹

Trichophyton verrucosum infection is almost invariably transmitted through contact with infected cattle. Despite

the large herd of cattle in the country and reports of infection in these animals caused by this dermatophyte, there have been few reports in Brazil of *tinea capitis* in humans caused by *Trichophyton verrucosum*. The majority of the reported cases in humans come from Europe and Asia.

A 64-year-old immunocompetent patient, working in the rural environment, presented follicular pustules in the temporo-occipital region, which extended through almost the entire scalp (Fig. 1A). No hyphae were found in two microbiological examinations, only cocci, with negative bacterial and fungal cultures. He was on antibiotics (clindamycin and ceftriaxone) with no response. After ten days, lesions suggestive of *kerion celsi* appeared in the initial area (Fig. 1B). A third direct mycological examination demonstrated hyphae (Fig. 2A) and the culture identified *Trichophyton verrucosum* (Fig. 2B), with ochre-colored colonies, which grew at 37 °C and microscopically showed the characteristic rounded chlamydoconidia in strings (Fig. 2C). Scanning electron microscopy of a colony was performed and chain chlamydoconidia were also identified through this technique (Fig. 3).

* Study conducted at the Universidade Federal de Pelotas, Pelotas, RS, Brazil.