

LETTER - DERMATOPATHOLOGY

Bullous dermatomyositis with anti-NPX2 antibodies, associated with breast cancer[☆]



Dear Editor,

Vesicle or bulla formation in Dermatomyositis (DM) is extremely rare, with approximately 68 bullous DM (BDM) cases published to date.¹⁻⁷ It was first reported by Christian in 1903.⁸ BDM mainly affects women in the 5th–7th decade. In classical DM, the male-to-female ratio is 1:2. BDM favors female presentation with a ratio of 3:1.⁴ Blisters in BDM predominantly develop on frequently irritated areas such as extensor areas of upper extremities, knees, and trunk.⁴ A recent case series addresses the importance of the correlation between BDM and neoplasia.¹

A 54-year-old woman with a previous diagnosis of breast cancer, treated three years ago with partial mastectomy, attended our dermatology department with a three-month history of symmetric pruriginous erythematous plaques on both thighs. She was previously treated in another hospital with a 20-day course of oral prednisolone 20 mg/day with partial response. No other treatment or vaccines were prescribed. The patient progressed with generalized skin lesions within a month. Physical examination revealed an erythematous rash with symmetrical vesicles and bullas on the neck, abdomen, arms, knees, and thighs (holster sign) (Fig. 1 A and B), and Gottron's sign (Fig. 1C). Oral mucosa was unaffected. Laboratory tests showed increased serum glutamic-oxaloacetic transaminase levels of 211 U/L, PCR 2.1 mg/dL, and total CK within normal limits. Extractable nuclear antigen, rheumatoid factor, rapid plasma reagin, anti-histone, anti-DNA, and antinuclear antibodies were negative. Complement C3 and C4 were normal. Histology demonstrated focal parakeratosis, hydropic changes in the basal layer with subepidermal edema and bulla formation. Mild lymphocytic infiltrate around superficial vessels with few neutrophils and dermal mucin deposition (Fig. 2). Direct Immunofluorescence (DIF) was only focally positive for C3 on superficial vessels. Magnetic Resonance Imaging of the extremities and neck showed mild myositis of the deltoid and trapezius muscles. The DM panel revealed positivity for anti-NPX2. A complete paraneoplastic screening was performed, which was normal.

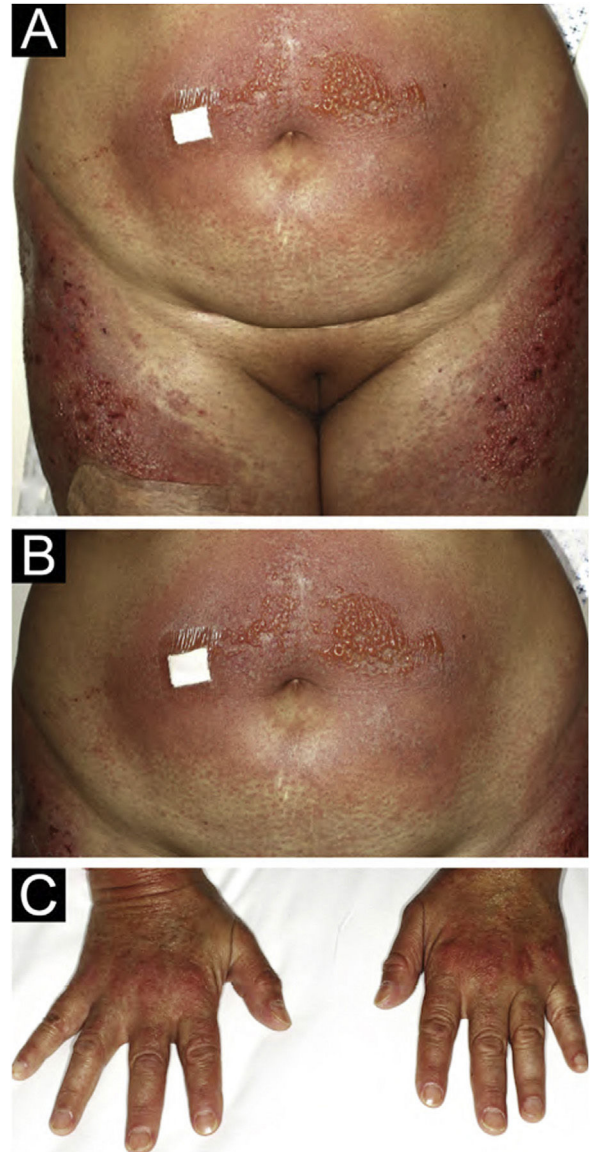


Figure 1 (A) Intense erythematous rash on the abdomen and thighs associated with the presence of vesicles and bullas. (B) Magnification of vesicles and bullas on the abdomen. (C) Gottron's sign.

[☆] Study conducted at the Clínica Alemana de Santiago de Chile, Santiago, Chile.

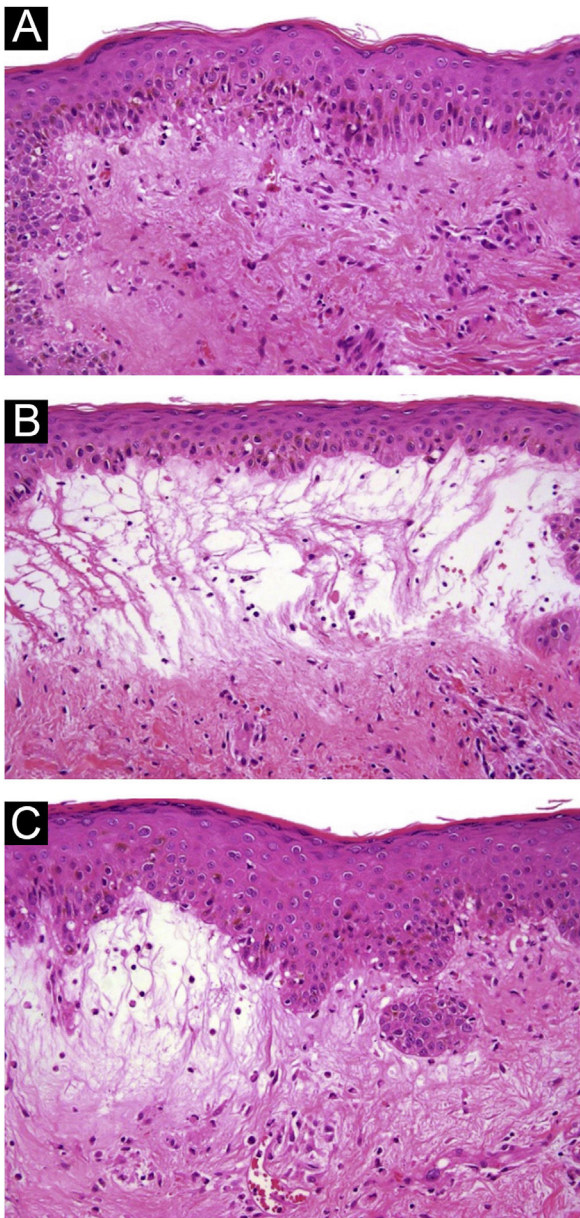


Figure 2 (A) 10× Hematoxylin-eosin staining; hydropic changes in the basal layer. (B and C) 10× Hematoxylin-eosin staining with marked dermal edema and bullae formation with mild lymphocytic infiltrate around superficial vessels.

Clinical and histopathological findings, in addition to anti-NPX2 positivity and the presence of vesicles lead us to the diagnosis of BDM. Treatment with oral tacrolimus 3 mg/day was administered with complete remission of blisters and subclinical myositis. Tacrolimus treatment was finished in March 2022 and, until this publication, there is no clinical recurrence. The patient has been followed for four years and no new neoplasia has been found.

Since clinical signs are usually non-specific in BDM, histopathology, and molecular markers become valuable diagnostic tools. The BDM histopathology commonly shows subepidermal blisters with dermal edema, mucin deposition, and superficial perivascular inflammation. Vesicles are generated by an intense inflammatory reaction and marked

dermal edema.⁴ In about 35% of cases, DIF reveals granular deposits of immunoglobulins and complement at the dermoepidermal junction.⁹ In addition, C3 and C5b-9 granular deposits can be found in vessels, probably as a nonspecific inflammatory reaction, supporting the diagnosis in our case.^{6,9} Differential diagnoses include: (1) Bullous erythematosus lupus – positive granular or linear DIF in the Basal Membrane Zone (BMZ) and anti-collagen VII antibodies, (2) Bullous pemphigoid – positive linear DIF in the BMZ with anti-BP180 or BP230 antibodies, (3) Dermatitis herpetiformis – DIF with granular deposits in dermal papillae, and (4) Pemphigus – positive intercellular DIF and anti-desmoglein 1 and 3 antibodies.¹⁰

DM can be associated with autoimmune blister diseases. Epitope spreading has been proposed as an explanation, but their association remains unknown.⁷

The link between DM and cancer has well known since 1960.^{1,6} The association with classical DM is approximately 15%–27%.⁸ The association between cancer and BDM is significantly higher, ranging from 52%–68% of patients.^{1,3,7} The intense inflammatory reaction found in BDM is associated with a higher paraneoplastic risk.^{3,6,7} There is a poorer prognosis of BDM when associated with malignancies, which can develop within the first three years after BDM diagnosis.³ This highlights the importance of an exhaustive search for neoplasms in patients diagnosed with DM, especially if BDM is present. The finding of anti-NXP2 in DM is highly related to cancer, as it was demonstrated in this report.^{2,7} BDM has also been associated with lung, ovarian, and esophagus tumors.^{1,3}

BDM can be easily misdiagnosed. Early recognition is key to achieve a better prognosis. Patients should be closely followed up for appropriate treatment and cancer screening. Clinical examination is mandatory every 4–6 months for at least three years and clinical images should be performed every 6–12 months.^{3,11}

Herein, we report a rare clinical presentation of hypomycopathic DM in which the combination of anamnesis, physical examination, laboratory and imaging exams, and histopathologic findings played a crucial role in reaching a correct diagnosis. We emphasize that BDM should always be in the differential diagnosis of bullous diseases.

Financial support

None declared.

Authors' contributions

Francisca Reculé: Approval of the final version of the manuscript; intellectual participation in propaedeutic and/or therapeutic management of studied cases; manuscript critical review; preparation and writing of the manuscript.

Juana Benedetto: approval of the final version of the manuscript; intellectual participation in propaedeutic and/or therapeutic management of studied cases; manuscript critical review; preparation and writing of the manuscript.

Catalina Silva-Hirschberg: Approval of the final version of the manuscript; critical literature review; manuscript critical review; preparation and writing of the manuscript.

Raúl Cabrera: Approval of the final version of the manuscript; intellectual participation in propaedeutic and/or therapeutic management of studied cases; manuscript critical review; preparation and writing of the manuscript.

Alex Castro: Approval of the final version of the manuscript; manuscript critical review; preparation and writing of the manuscript.


Conflicts of interest

None declared.

References

- Mori T, Hanami Y, Yamamoto T. Vesiculo-bullous dermatomyositis in association with internal malignancy. *Actas Dermosifiliogr*. 2022;113:1017–9.
- Muro Y, Sugiura K, Akiyama M. Cutaneous manifestations in dermatomyositis: key clinical and serological features—a comprehensive review. *Clin Rev Allergy Immunol*. 2016;51:293–302.
- Zangrilli A, Papoutsaki M, Bianchi L, Teoli M, Chimenti S. Bullous dermatomyositis: a marker of poor prognosis and aggressive internal malignancy? *Acta Derm Venereol*. 2008;88:393–4.
- Mitsuya J, Hara H, Hattori A, Matsunaga A, Terui T. Vesicle formation in dermatomyositis associated with colon carcinoma. *Clin Exp Dermatol*. 2009;34:e221–2.
- McCullough ML, Cockerell CJ. Vesiculo-bullous dermatomyositis. *Am J Dermatopathol*. 1998;20:170–4.

- Kubo M, Sato S, Kitahara H, Tsuchida T, Tamaki K. Vesicle formation in dermatomyositis associated with gynecologic malignancies. *J Am Acad Dermatol*. 1996;34:391–4.
- Wu H, Diao L, Xue K, Zhao Q, Zhao X, Xia Q, et al. Case report: concurrence of dermatomyositis and autoimmune blistering diseases: two case reports and a literature review. *Front Immunol*. 2022;13:855408.
- Khanna U, Galimberti F, Li Y, Fernandez AP. Dermatomyositis and malignancy: should all patients with dermatomyositis undergo malignancy screening? *Ann Transl Med*. 2021;9:432.
- Calonje E, Brenn T, Lazar A, McKee PH. McKee's pathology of the skin: with clinical correlations. Elsevier/Saunders; 2012, 1803.
- Montagnon CM, Tolkachjov SN, Murrell DF, Camilleri MJ, Lehman JS. Intraepithelial autoimmune blistering dermatoses: clinical features and diagnosis. *J Am Acad Dermatol*. 2021;84:1507–19.
- Bolognia JL, Schaffer JV, Cerroni L. *Dermatology*. Dermatomyositis. Philadelphia: Elsevier; 2018. p. 681–92.

Francisca Reculé ^a, Juana Benedetto ^a, Catalina Silva-Hirschberg ^{a,*}, Raúl Cabrera ^a, Alex Castro ^b

^a Department of Dermatology, Facultad de Medicina, Clínica Alemana, Universidad del Desarrollo, Santiago, Chile

^b Department of Pathology, Facultad de Medicina, Clínica Alemana, Universidad del Desarrollo, Santiago, Chile

* Corresponding author.

E-mail: casilvah@udd.cl (C. Silva-Hirschberg).

Received 16 October 2022; accepted 25 January 2023
Available online 21 December 2023

<https://doi.org/10.1016/j.abd.2023.01.007>

0365-0596/ © 2023 Published by Elsevier España, S.L.U. on behalf of Sociedade Brasileira de Dermatologia. This is an open access article under the CC BY license (<http://creativecommons.org/licenses/by/4.0/>).

Eruptive disseminated spitz nevus: a case report and review of the genetic aspect of the disease*



Dear Editor,

Spitz nevi are usually solitary, benign proliferations of epithelioid melanocytes. Various clinical and histopathological subtypes of Spitz nevi have been reported in the literature over time. The eruptive variant of Spitz nevus has been reported in 34 cases so far. Genetic analysis was performed in 7 of them. In this report, the authors present a patient with hundreds of Spitz nevi in her body in just 2 months and review the current literature together with the genetic studies.

A 17-year-old young woman presented with multiple nevi starting from the buttocks and spreading to the back and legs

for the last 2 months. She was otherwise healthy and had no history of any drug use. She had no complaints of itching or bleeding on the lesions. There was no freckling on her face and she did not describe photosensitivity. There was no finding of syndromes characterized by multiple lentiginos, no known genetic disease in the family, and no intermittent or continuous sunlight exposure for the respective sites. In the dermatological examination, hundreds of dome-shaped nevi with reddish brown colors, <0.5 cm in diameter were observed on the legs and upper body, especially on the buttocks (Fig. 1). A few lesions compatible with Spitz nevus were observed on the neck, which were reported to have newly formed.

On dermatoscopic examination, there is a reticular distribution, which is darker in the center and becomes lighter in the periphery, and globules are observed in the periphery of the lesions (Fig. 2).

In the hematoxylin-eosin stained sections from four lesions; symmetric, junctional, localized, pigmented discohesive melanocytic nest structures with spindle cells and pagetoid spreading areas are seen (Fig. 3). No mild atypia was observed in melanocytes. Diffuse and strong positive staining was observed with S100, MelanA, HMB45. In addi-

* Study conducted at the Department of Dermatology and Pathology, Sivas Numune Hospital, Sivas, Turkey.