

## CORRESPONDENCE

### Comment on “Elevation of transaminases after MMP<sup>®</sup> session with methotrexate for alopecia areata treatment - how much do we know about the risks of systemic absorption of the technique?”<sup>☆</sup>

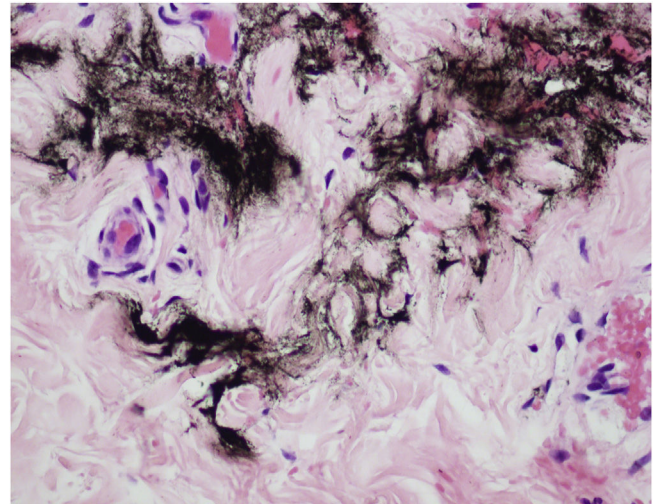


Dear Editor,

We read with interest Nogueira’s et al. recent case report.<sup>1</sup> This is an important contribution to the limited evidence about the safety of drug delivery techniques.

As an experienced and enthusiastic user of the MMP<sup>®</sup> technique, I have a few considerations:

- 1) Although evidence derived from case reports is considered low, nevertheless it is important to raise questions in different scenarios.
- 2) Changes in liver enzyme levels are common in clinical practice and can be caused by many factors including physical activity, use of drugs (e.g., acetaminophen) or alcohol, and viral infections.<sup>2</sup>
- 3) MMP<sup>®</sup> is a drug delivery technique that uses microneedles and dermo pigmentation equipment. Tattoos are unequivocal evidence of injection and absorption. The main advantages of this technique are the uniform drug distribution in the dermis, without bolus formation (Fig. 1), and increased substance dispersion due to shear stress and turbulent whirling<sup>3</sup> caused by Newton’s law of attrition.
- 4) Drug absorption delivered through MMP<sup>®</sup> occurs predominantly through the lymphatic channels of the skin<sup>4</sup> and not the subjacent blood vessels.
- 5) MMP<sup>®</sup> is the only drug delivery technique with published protocols that allow the quantification of the drug density injected in the dermis,<sup>5</sup> offering safety parameters to the dermatologist.
- 6) Since the procedure was done in an ophiasis region (423 cm<sup>2</sup>), using a saline solution (estimated density 1.000.000 µg/mL) and the medication contained 25 mg/mL of the active ingredient, based on published protocols we calculate that 390.907 µg (0.390907 mg) of



**Figure 1** Drug delivery with MMP<sup>®</sup> technique. This is a cross section of the reticular dermis demonstrating ink between the collagen fibers, without bolus formation

the methotrexate solution was injected in the dermis<sup>5</sup> (Video 1), which corresponds to 9.8 mg of methotrexate.

Considering the aforementioned facts, and the lack of other reports of possible drug toxicity related to methotrexate MMP<sup>®</sup> drug delivery, we must consider an alternative hypothesis for the findings described by Nogueira et al.<sup>1</sup> It is possible that this patient’s mild transient increase in transaminases may have occurred by chance or have been caused by other factors unrelated to methotrexate MMP<sup>®</sup> drug delivery?

### Financial support

TRADERM, a company that commercializes tattoo supplies.

### Authors’ contributions

Samir Arbache: Conceptualization; data curation; writing-original draft; and writing-review and editing.

Sergio Henrique Hirata: Conceptualization; data curation; writing-original draft; and writing-review and editing.

<sup>☆</sup> Study conducted at the DermoCentro Clinic, São José dos Campos, SP, Brazil.

## Conflicts of interest

MMP<sup>®</sup>, a registered trademark in Brazil, the United States, and Europe, grants free use exclusively to dermatologists who are members of the Brazilian Society of Dermatology and equivalent associations in the world. Dr. Arbache owns the company that commercializes the supplies used for MMP and is part of a team of professionals who train Brazilian dermatologists in to use of this technique.

## Acknowledgments

Dr. Nilceo Michalany for microphotography documentation. Dr. Sergio Hirata, advisor of my doctoral thesis.

## Appendix A. Supplementary data

Supplementary material related to this article can be found, in the online version, at doi:<https://doi.org/10.1016/j.abd.2023.05.002>.

## References

1. Nogueira BL, Bonamigo RR, Heck R. Elevation of transaminases after MMP<sup>®</sup> session with methotrexate for alopecia areata

2. treatment—how much do we know about the risks of systemic absorption of the technique? *An Bras Dermatol.* 2023;98:390–1.
3. Giannini EG, Testa R, Savarino V. Liver enzyme alteration: a guide for clinicians. *Cmaj.* 2005;172:367–79.
4. Arbache S, de Mendonca MT, Arbache ST, Hirata SH. Treatment of idiopathic guttate hypomelanosis with a tattoo device versus a handheld needle. *JAAD Int.* 2021;3:14–6.
5. Hellerich U. Tattoo pigment in regional lymph nodes—an identifying marker? *Arch Kriminol.* 1992;190:163–70.
6. Arbache S, da Costa Mattos E, Diniz MF, Paiva PYA, Roth D, Arbache ST, et al. How much medication is delivered in a novel drug delivery technique that uses a tattoo machine? *Int J Dermatol.* 2019;58:750–5.

Samir Arbache  <sup>a,\*</sup>, Sergio Henrique Hirata  <sup>b</sup>

<sup>a</sup> *DermaCentro Clinic, São José dos Campos, SP, Brazil*

<sup>b</sup> *Department of Dermatology, Universidade Federal de São Paulo, São Paulo, SP, Brazil*

\* Corresponding author.

E-mail: [samir@dermocentro.com.br](mailto:samir@dermocentro.com.br) (S. Arbache).

Received 5 May 2023

Available online 5 October 2023

<https://doi.org/10.1016/j.abd.2023.05.002>

0365-0596/ © 2023 Published by Elsevier España, S.L.U. on behalf of Sociedade Brasileira de Dermatologia. This is an open access article under the CC BY license (<http://creativecommons.org/licenses/by/4.0/>).

## Comment related to the publication “Elevation of transaminases after MMP<sup>®</sup> session with methotrexate for alopecia areata treatment – How much do we know about the risks of systemic absorption of the technique?” – Answer\*



Dear Editor,

We agree with the consideration that, regarding the cause of the increase in transaminase levels in the described patient, there are no means of affirming with certainty the association with the MMP<sup>®</sup> technique.<sup>1</sup> We reinforce, however, that she had already shown an elevation of transaminase levels with the previous use of the medication when administered orally. We attributed it to the technique used after excluding other possible causes such as infections, alcohol consumption, physical activity, or use of any other medication, in addition to the transitoriness of transaminitis in relation to the procedure.

The technique involves the penetration of needles into the dermis,<sup>2,3</sup> where vascularization is prominent in the scalp, with biological plausibility in affirming the possibility of absorption of the drug used. Additionally the patient is likely to be susceptible to methotrexate-related adverse effects, despite the small, absorbed dose.

We reaffirm the importance of reporting unexpected adverse effects related to the recent use of percutaneous treatment techniques, aiming at patient safety through adequate monitoring.

## Financial support

None declared.

## Authors' contributions

Renan Rangel Bonamigo: Drafting and editing of the manuscript and critical review of important intellectual content; effective participation in research orientation; intellectual participation in the propaedeutic and/or therapeutic conduct of the studied cases; critical review of the literature; approval of the final version of the manuscript.

Renata Heck: Design and planning of the study; drafting and editing of the manuscript and critical review of important intellectual content; effective participation in research orientation; intellectual participation in the propaedeutic and/or therapeutic conduct of the studied cases; critical

\* Study conducted at the Service of Dermatology, Hospital de Clínicas de Porto Alegre, Porto Alegre, RS, Brazil.