

## LETTER - TROPICAL/INFECTIOUS AND PARASITIC DERMATOLOGY

### Chromoblastomycosis in a renal transplant patient\*



Dear Editor,

Chromoblastomycosis is a subcutaneous mycosis caused by the traumatic implantation of dematiaceous fungi, primarily affecting the lower limbs of male rural workers in tropical and subtropical regions.<sup>1</sup> It is rarely reported in immunosuppressed hosts, particularly in solid-organ transplant recipients or in association with neoplastic diseases.<sup>2,3</sup> This report describes a 63-year-old male construction worker, living in an urban area, who reported an injury in the right forearm after local trauma caused by a tree branch three years ago. Growth was slow and progressive, with mild local pruritus. The patient was hypertensive and had received a renal transplant five years before due to chronic kidney disease, probably secondary to the use of non-steroidal anti-inflammatory drugs and taking, used tacrolimus 2 mg/day, sirolimus 2 mg/day and prednisone 5 mg/day.

On examination, an infiltrated erythematous-squamous plaque measuring 2.5 × 3.0 cm including the scarring area, was observed (Fig. 1A). Dermoscopy, using a Heine device, model Delta 30, under polarized light, showed reddish-pink background, scales, reddish-orange ovoid structures interspersed with brown dots and extravascular red lacunae in an area not covered by squamous crusts (Fig. 1B).

Histopathology showed the presence of a dermal granulomatous inflammatory infiltrate, associated with neutrophilic microabscess and frequent round, brownish fungal structures, characteristic of sclerotic or muriform cells, some of them inside the cytoplasm of multinucleated giant cells (Fig. 2) presenting equatorial septation. Culture on Mycosel agar showed a greenish-black velvety colony with central elevation (Fig. 3A) and the microculture revealed *Cladosporium*-type sporulation with erect conidiophores, short chains, and two to three conidia at or near the apex, compatible with *Fonsecaea* spp. (Fig. 3B). Due to the COVID-19 pandemic, the patient was reassessed nine months after the initial appointment, reporting that the lesion was stable. He informed the replacement of sirolimus by mycophenolate mofetil during the period and underwent surgical excision, with a 5-mm margin. The patient returned for reevaluation

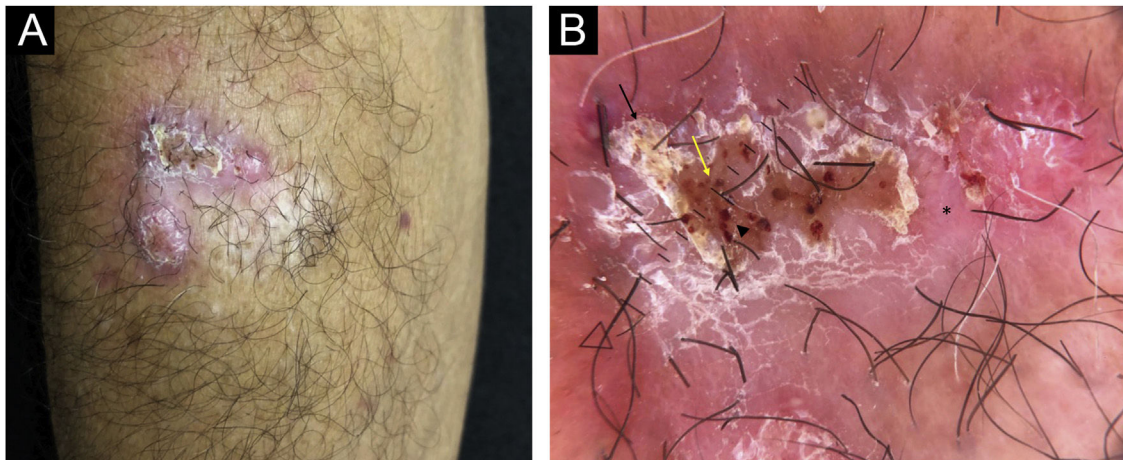
two months after surgery with good healing and no signs of recurrence (Fig. 4), maintaining the scarred aspect at the time of the last reassessment, corresponding to the 9<sup>th</sup> month after the surgical procedure.

The countries with the highest prevalence of chromoblastomycosis are Brazil, Mexico, Venezuela, India, Australia, and China<sup>2</sup> In Brazil, this mycosis occurs in most states, and the state of Pará presents the highest incidence.<sup>1</sup> The lower limbs are the most affected areas, followed by the upper limbs, and males aged between 20–60 years, with rural activity are the common denominator in 90% of cases.<sup>1–5</sup> The most prevalent etiological agent is *Fonsecaea pedrosoi* (66%–96% of cases), followed by *Cladophialophora carrionii*, and *Phialophora verrucosa*.<sup>2–5</sup> The clinical manifestation of chromoblastomycosis is polymorphic and may present as a verrucous, nodular, tumor-like, cicatricial, or infiltrated plaque.<sup>2</sup> The evolution of lesions associated with post-transplant immunosuppression does not differ, in most cases, from that observed in immunocompetent patients, i.e., slow, indolent growth.<sup>2–5</sup> It can be speculated that tacrolimus, due to its antifungal action, is also effective in delaying lesion progression.<sup>6</sup>

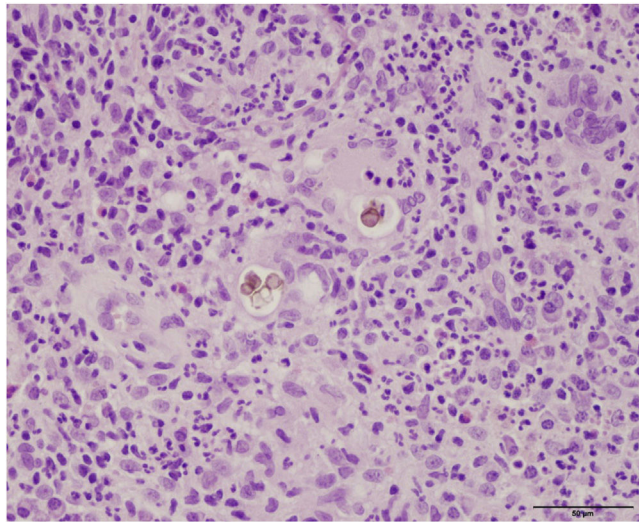
The presence of diseases or the use of associated immunosuppressive medications was described in only 0.2% of the reported cases, with solid-organ transplantation being the most common, followed by HIV infection, rheumatoid arthritis, systemic lupus erythematosus (SLE), bladder cancer, celiac disease, pernicious anemia and non-Hodgkin's lymphoma.<sup>3–5</sup>

Dermoscopy usually shows the presence of reddish-black dots that represent the transepidermal elimination of inflammatory cells, fungal elements, or hemorrhage. Yellow-orange ovoid structures on a pinkish-white background, polymorphic vessels, scales, and crusts may also be seen.<sup>7</sup> The treatment of choice for chromoblastomycosis, whenever possible, is surgical removal, with or without clinical treatment or adjuvant physical treatments that can reduce the lesion diameter and allow surgical excision. Long-term postoperative follow-up is recommended, as recurrence is possible. Itraconazole 200–400 mg/day for a variable time, or in combination with terbinafine 500 mg/day are the most used antifungals. Posaconazole is an alternative treatment after failure of or intolerance to classical clinical treatment.<sup>8</sup> Physical therapeutic methods such as thermotherapy, cryotherapy, laser therapy, and photodynamic therapy may be effective or useful as adjunct treatments.<sup>2</sup>

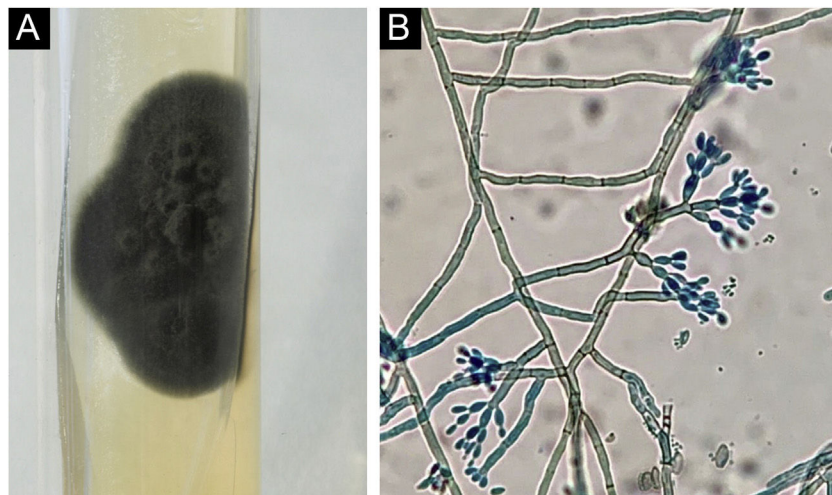
\* Study conducted at the Faculty of Medicine, Universidade Estadual Paulista, Botucatu, SP, Brazil.



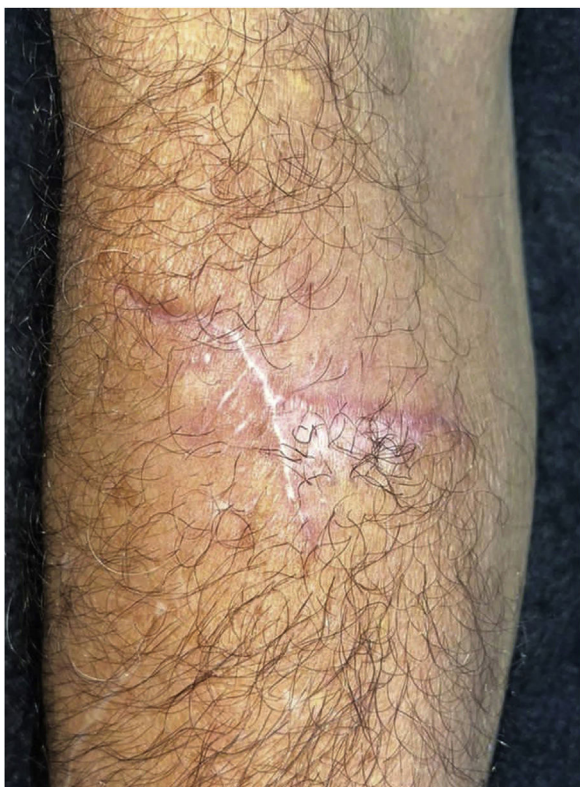**Figure 1** (A) Infiltrated plaque lesion, on the right forearm, showing surface covered by squamous crusts. (B) Dermoscopy under polarized light showed a reddish-pink background (asterisk), desquamation (black arrow), reddish-orange ovoid structures interspersed with brown dots (yellow arrow) and extravascular red lacunae in an area not covered by squamous crusts (arrowhead)



**Figure 2** Dermal granulomatous inflammatory infiltrate, associated with neutrophilic abscess and the presence of brownish-colored fungi, muriform bodies, some of them inside the cytoplasm of multinucleated giant cells (Hematoxylin & eosin 40X)



**Figure 3** (A) Velvety greenish-black culture, with a central elevation. Mycosel agar. (B) Microculture showing the presence of *Cladosporium*-type sporulation with erect conidiophores, and short chains with two to three conidia. (Staining: cotton blue). *Fonsecaea* spp



**Figure 4** Late postoperative period, two months after excisional surgery

Chromoblastomycosis constitutes a diagnostic challenge in immunosuppressed patients, as it is rarely observed or reported in the literature. It is important to be aware of drug interactions between systemic antifungals and the immunosuppressive therapy being used, which may constitute an important limiting factor for treatment.

### Financial support

None declared.

### Authors' contributions

Ingrid Rocha Meireles Holanda: Design and planning of the study; drafting and editing of the manuscript; collection, analysis, and interpretation of data; effective participation in research orientation; intellectual participation in the propaedeutic and/or therapeutic conduct of the studied cases; critical review of the literature; critical review of the manuscript; approval of the final version of the manuscript.

Priscila Neri Lacerda: Design and planning of the study; drafting and editing of the manuscript; collection, analysis, and interpretation of data; intellectual participation in the propaedeutic and/or therapeutic conduct of the studied cases; critical review of the literature; critical review of the manuscript.

Carolina Nunhez da Silva: Drafting and editing of the manuscript; collection, analysis, and interpretation of data; intellectual participation in the propaedeutic and/or ther-

apeutic conduct of the studied cases; critical review of the literature; critical review of the manuscript.

Rosangela Maria Pires de Camargo: Drafting and editing of the manuscript; collection, analysis, and interpretation of data; intellectual participation in the propaedeutic and/or therapeutic conduct of the studied cases; critical review of the literature; critical review of the manuscript.

Anna Carolina Miola: Drafting and editing of the manuscript; collection, analysis, and interpretation of data; intellectual participation in the propaedeutic and/or therapeutic conduct of the studied cases; critical review of the literature; critical review of the manuscript.



Silvio Alencar Marques: Design and planning of the study; drafting and editing of the manuscript; effective participation in research orientation; intellectual participation in the propaedeutic and/or therapeutic conduct of the studied cases; critical review of the literature; critical review of the manuscript; approval of the final version of the manuscript.

### Conflicts of interest

None declared.

### References

1. Brito AC, Bittencourt MJS. Chromoblastomycosis: an etiological, epidemiological, clinical, diagnostic and treatment up-date. *An Bras Dermatol*. 2018;93:495–506.
2. Queiroz-Telles F, De Hoog S, Santos DWCL, Salgado CG, Vicente VA, Bonifaz A, et al. Chromoblastomycosis. *Clin Microbiol Rev*. 2017;30:233–76.
3. Kumbhakar R, Miko BA. Chromoblastomycosis in solid organ transplant recipients. *Curr Fungal Infect Rep*. 2019;13:139–45.
4. Santos DWCL, Azevedo CMPS, Vicente VA, Queiroz-Telles F, Rodrigues AM, Hoog GS, et al. The global burden of chromoblastomycosis. *PLoS Negl Trop Dis*. 2021;15:0009611.
5. Lima ACC, Santos DWCL, Hirata SH, Nishikaku AS, Enokihara MMSES, Ogawa MM. Therapeutic management of subcutaneous phaeohyphomycosis and chromoblastomycosis in kidney transplant recipients: a retrospective study of 82 cases in a single center. *Int J Dermatol*. 2022;61:346–51.
6. Antypenko L, Meyer F, Sadykova Z, Garbe LA, Steffens KG. Tacrolimus as antifungal agent. *Acta Chim Slov*. 2019;66:784–91.
7. Chauhan P, Jindal R, Shirazi N. Dermoscopy of chromoblastomycosis. *Indian Dermatol Online J*. 2019;10:759–60.
8. Dupont C, Duong TA, Mallet S, Mamzer-Bruneel MF, Thervet E, Bougnoux ME, et al. Unusual presentation of chromoblastomycosis due to *Cladophialophora carrionii* in a renal and pancreas transplant recipient patient successfully treated with posaconazole and surgical excision. *Transpl Infect Dis*. 2010;12:180–3.

Ingrid Rocha Meireles Holanda \*,  
Priscila Neri Lacerda , Carolina Nunhez da Silva ,  
Rosangela Maria Pires de Camargo ,  
Anna Carolina Miola , Silvio Alencar Marques 

*Infectious Diseases, Dermatology, Imaging Diagnosis and Radiotherapy, Faculty of Medicine, Universidade Estadual Paulista, Botucatu, SP, Brazil*

\* Corresponding author.

E-mail: [ingmeireles@hotmail.com](mailto:ingmeireles@hotmail.com) (I.R. Holanda).

Received 25 October 2022; accepted 16 February 2023

Available online 23 September 2023

<https://doi.org/10.1016/j.abd.2023.02.008>

0365-0596/ © 2023 Sociedade Brasileira de Dermatologia.

Published by Elsevier España, S.L.U. This is an open access article under the CC BY license (<http://creativecommons.org/licenses/by/4.0/>).

## ***Mycobacterium abscessus* sporotrichoid infection after a dog bite\***



Dear Editor,

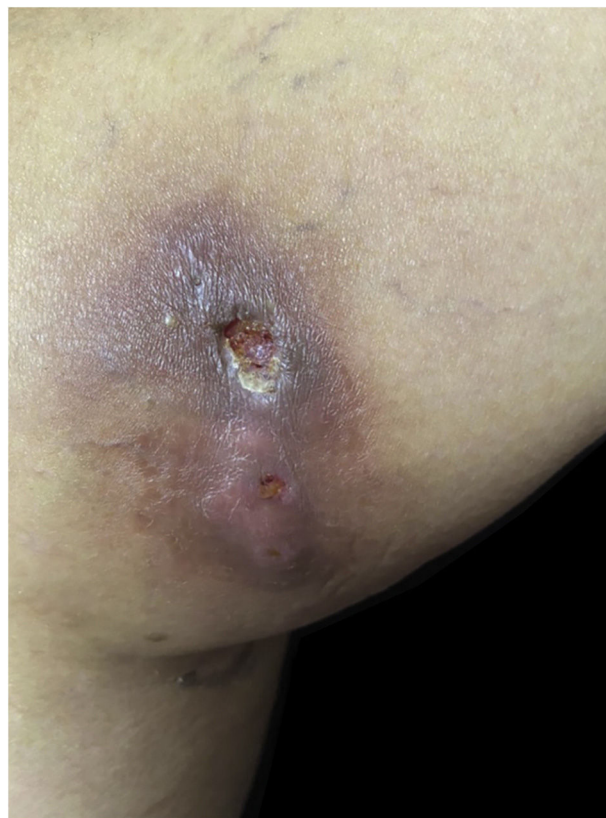The terms “atypical mycobacteria” or “non-tuberculous mycobacteria” (NTM) refer to a group of mycobacteria other than *Mycobacterium tuberculosis* and *Mycobacterium leprae*.<sup>1,2</sup> NTM are ubiquitous organisms that can resist extreme temperature conditions.<sup>1,2</sup> *M. abscessus* is a fast-growing atypical mycobacterium that can cause cutaneous lesions and disseminated infections, typically after skin trauma.<sup>2</sup> Dermatological manifestations include nodules, abscesses, and ulcers that may often resemble *Sporothrix* infections.<sup>1</sup> Zoonotic transmission is rarely reported.<sup>3</sup>

### Case report

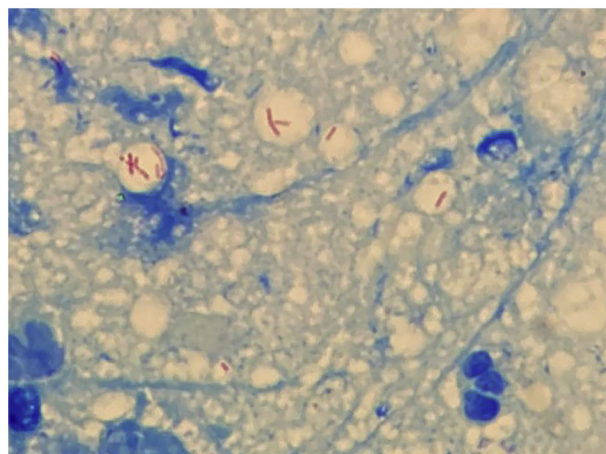
A 63-year-old female presented with a history of a 2-month enlarging nodule over the medial aspect of the thigh after suffering a street dog bite. She was previously treated with clindamycin 300 mg TID for 21 days without improvement. On examination, there were 3 ulcerated, purulent gummas over an erythematous, warm, tender, fluctuating area of the thigh (Fig. 1). No adenomegalies were found. Samples were taken from the secretion for microbiological and molecular biology studies. Gram stain, KOH smear, and Sabouraud culture were negative. Acid-fast bacilli were identified on the Ziehl-Nielsen stain (Fig. 2). Creamy, white, cerebriform colonies grew on Lowenstein Jensen culture (Fig. 3) and with the identification of 1) PCR-RFLP (polymerase chain reaction-restriction fragment length polymorphism) of the *gyrB* and *hsp65* genes with the digestion of the *RsaI*, *TaqI* or *Sac II* enzymes and *HhaI* enzyme respectively and 2) Multi-primer PCR to detect the absence or the presence of the RD9 and RD1 regions confirmed *M. abscessus*. The patient received amikacin 1 g IM daily for 2 weeks in two cycles plus clarithromycin 500 mg BID for 4 months, showing a favorable clinical response (Fig. 4).

NTM comprise a heterogenous group of acid-fast bacilli that are further classified according to their growth speed, morphology, and pigmentation.<sup>1</sup> They were first described in 1931 by Pinner, and there are now more than 200 reported species.<sup>3</sup> *M. abscessus* is associated with a wide spectrum of dermatological lesions that include cellulitis, abscesses,

papules, pustules, fistulae, ulcers, necrotic lesions, and subcutaneous nodules that can resemble *Sporothrix* lesions.<sup>2,3</sup>



**Figure 1** Three ulcerated, purulent, gummas affecting the thigh



**Figure 2** Abundant acid-fast bacilli can be observed with Ziehl-Neelsen stain

\* Study conducted at the Dermatological Institute of Jalisco “Dr. José Barba Rubio”, Secretariat of Salud Jalisco, Zapopan, Jalisco, México.