

6. Zwijnenburg EM, Lubeek SFK, Werner JEM, Amir AL, Weijs WLJ, Takes RP, et al. Merkel cell carcinoma: new trends. *Cancers (Basel)*. 2021;13:1614.
7. Lewis CW, Qazi J, Hippe DS, Lachance K, Thomas H, Cook MM, et al. Patterns of distant metastases in 215 Merkel cell carcinoma patients: Implications for prognosis and surveillance. *Cancer Med*. 2020;9:1374–82.
8. Xia YJ, Cao DS, Zhao J, Zhu BZ, Xie J. Frequency and prognosis of metastasis to liver, lung, bone and brain from Merkel cell carcinoma. *Future Oncol*. 2020;16:1101–13.

Yixin Liu <sup>a</sup>, Wenjing Liang <sup>a</sup>, Qiongrong Chen <sup>b</sup>, Yongchang Wei <sup>a,\*</sup>

<sup>a</sup> Department of Radiation and Medical Oncology, Zhongnan Hospital of Wuhan University, Wuhan, China

<sup>b</sup> Department of Pathology, Zhongnan Hospital of Wuhan University, Wuhan, China

\* Corresponding author.

E-mail: [weiyongchang@whu.edu.cn](mailto:weiyongchang@whu.edu.cn) (Y. Wei).

Received 15 February 2022; accepted 11 May 2022

Available online 29 June 2023

<https://doi.org/10.1016/j.abd.2022.05.009>

0365-0596/ © 2023 Published by Elsevier España, S.L.U. on behalf of Sociedade Brasileira de Dermatologia. This is an open access article under the CC BY license (<http://creativecommons.org/licenses/by/4.0/>).

## Ophthalmological complications related to the use of microfocused ultrasound in the periocular region and face<sup>☆</sup>



Dear Editor,

The authors describe a severe clinical case of ophthalmologic complications related to the use of microfocused ultrasound (MU) in the periocular region and face. It is extremely important to know about this possible complication of the use of MU.

A 50-year-old female patient sought dermatological care for facial rejuvenation. After evaluation, MU was employed on the face and periocular region, with carboxytherapy being performed on the eyelids. There were no complications during the procedures, which were followed by the application of Cicaplast<sup>®</sup> cream on the palpebral region. Immediately after the procedure, she complained of visual blurring, initially attributed to the use of Cicaplast<sup>®</sup>. On the first and second days after the procedure, she developed edema and erythema limited to the orbicularis region, while the visual blurring persisted and she started to have scotomas, lacrimation, and, finally, eye pain. On the third day, she experienced worsening of the ophthalmological condition, making it impossible to perform her daily activities, due to visual blurring and pain.

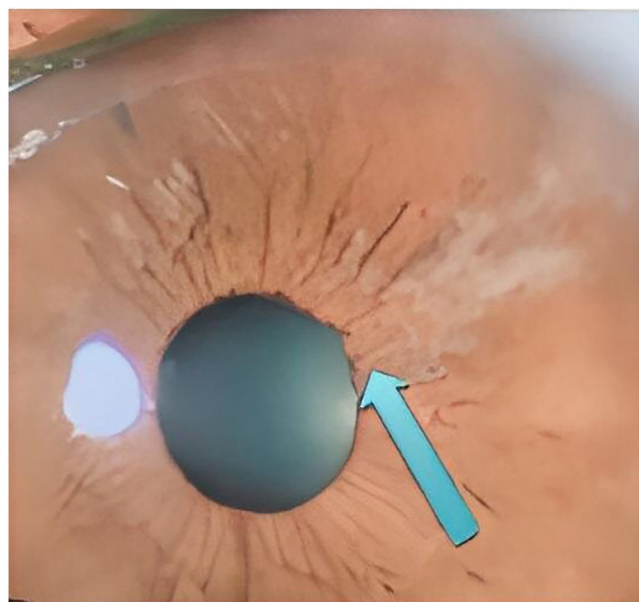
She was assessed by an ophthalmologist who found a significant increase in eye pressure, iris retraction, areas of fibrosis (Fig. 1), and crystalline lens atrophy in the shape of spicules, and she was diagnosed with acute angle-closure glaucoma and cataracts in the shape of spicules.

Treatment was implemented with maximum doses of timolol, brimonidine, bimatoprost, and acetazolamide eye drops; however, there was some difficulty in reducing ocular pressure and little improvement of symptoms. Surgical intervention was then considered to preserve the optic

nerve. After six months of treatment, she showed partial remission of symptoms, but still uses eye drops every other day.

MU is used for the treatment of body flaccidity, contouring, and muscle anchoring.<sup>1</sup> It acts by emitting vibrating waves, which generate molecular friction and heat, creating an area of coagulation. This leads to a tissue healing and retraction process (lifting).<sup>1,2</sup> According to the vibratory frequency, its energy is concentrated on a certain layer of the superficial musculo-aponeurotic system and promotes the aforementioned process.<sup>1,3</sup> Because of that, it is important to pay attention to the correct use of the technique, which consists in using the appropriate tip, respecting the pre-established number of discharges for each area and, above all, never pointing the transducer towards the eyes, when it is used on the periocular or facial regions.<sup>2,3</sup>

Similar cases have been previously observed, in which state-of-the-art devices were used and coursed with equiv-



**Figure 1** Patient's ophthalmoscopy, showing iris retraction and areas of fibrosis

<sup>☆</sup> Study conducted at the Instituto de Dermatologia Professor Rubem David Azuly, Santa Casa da Misericórdia do Rio de Janeiro, Rio de Janeiro, RJ, Brazil.

alent alterations, that is, symptoms immediately after the procedure, cataracts in the shape of spicules and difficult-to-control glaucoma. It is noteworthy that the patient had already undergone the same procedure before, with an older device, without complications.

Due to these significant adverse effects, the Brazilian Society of Glaucoma sent a letter in November 2019 to the Brazilian Society of Dermatology, issuing the necessary warning and highlighting the peculiar finding of a "spiky" cataract. It is important to emphasize that ophthalmological complaints after dermatological procedures should be evaluated by an ophthalmologist.<sup>4,5</sup>

The authors consider this communication to be opportune because it serves as a warning to colleagues, who must be very attentive to the use of new technologies. In the present case, specifically, the possible severe ophthalmological complications related to the use of MU.<sup>5</sup>

### Financial support

None declared.

### Authors' contributions

Mariana Marques Rechuan: Drafting and editing of the manuscript.

Jordana Cezar Vaz: Drafting and editing of the manuscript.

Fernanda de Azevedo Pereira Marques: Drafting and editing of the manuscript.

David Rubem Azulay: Drafting and editing of the manuscript; critical review of the manuscript.

### Conflicts of interest

None declared.

### References

1. Shome D, Vadera S, Ram S, Khare S, Kapoor R. Use of micro-focused ultrasound for skin tightening of mid and lower face. *Plas Reconstr Surg Glob Open*. 2019;7:2498.
2. Gutowski K. Microfocused ultrasound for skin tightening. *Clin Plastic Surg*. 2016;43:577–82.
3. Friedmann D, Bourgeois G, Chan HL, Zedlitz AC, Butterwick KJ. Complications from microfocused transcutaneous ultrasound: case series and review of the literature. *Lasers Surg Med*. 2018;50:13–9.
4. Delbarre M, Froussart-Maille F. Signs, symptoms, and clinical forms of cataract in adults. *J Fr Ophtalmol*. 2020;43:653–9.
5. Jonas J, Aung T, Bourne R, Bron A, Ritch R, Panda-Jonas S, et al. Glaucoma. *Lancet*. 2017;390:2183–93.

Mariana Marques Rechuan \*, Jordana Cezar Vaz ,  
Fernanda de Azevedo Pereira Marques ,  
David Rubem Azulay 

*Instituto de Dermatologia Professor Rubem David Azulay, Santa Casa da Misericórdia do Rio de Janeiro, Rio de Janeiro, RJ, Brazil*

\* Corresponding author.

E-mail: [mrechuan@gmail.com](mailto:mrechuan@gmail.com) (M.M. Rechuan).

Received 9 August 2021; accepted 13 December 2021

Available online 23 June 2023

<https://doi.org/10.1016/j.abd.2021.12.013>

0365-0596/ © 2023 Sociedade Brasileira de Dermatologia.

Published by Elsevier España, S.L.U. This is an open access article under the CC BY license (<http://creativecommons.org/licenses/by/4.0/>).

## Proliferating trichilemmal tumor<sup>☆</sup>



Dear Editor,

Proliferating trichilemmal tumor (PTT) is a rare adnexal neoplasm<sup>1,2</sup> derived from the outer sheath of the hair follicle and may originate from a pre-existing pilar/trichilemmal cyst as a result of trauma and/or inflammation in the latter.<sup>1,3</sup> It was first reported in 1966 by Wilson Jones<sup>2,4,5</sup> and it is benign in most cases<sup>3,4</sup> but eventually it can be malignant, recur locally, invade adjacent tissues and cause distant metastases.<sup>1,3–5</sup> It often presents as a solitary, soft nodular lesion, measuring 1 to 10 cm in diameter, on the scalp of elderly women.<sup>1,3</sup> and may be associated with an area of alopecia. More rarely, it can affect other topographies such

as the neck, trunk, groin, mons pubis, vulva, gluteal region, and skull base.<sup>1,3</sup>

This report describes the case of a 52-year-old male patient, with no comorbidities, who sought medical care complaining of a lesion on the scalp, with discomfort on palpation, that had been growing for about a year. He had a personal history of scalp cyst removal years before. On clinical examination, a tumor-like, erythematous lesion with a pedunculated structure in the center, measuring approximately 3 cm in its largest diameter, was observed in the parieto-occipital region (Fig. 1). The main hypothesis was trichilemmal cyst with atypical clinical presentation and, for this reason, an incisional spindle biopsy was performed, measuring about 2 cm in its largest diameter for anatomopathological analysis. Histopathology showed a dermal tumor, with no connection with the epidermis, consisting of an expansive lobular proliferation of squamous cells with ample eosinophilic cytoplasm and abrupt keratinization, without the formation of a granular layer - trichilemmal-type keratinization – in the central portion of the lobes (Fig. 2). Some of these cells had atypical nuclei, but no

<sup>☆</sup> Study conducted at the Private Practice, Porto Alegre, RS, Brazil.