

## Financial support

None declared.

## Authors' contributions

Anama Di Prinzio: The study concept and design; writing of the manuscript.

Marina Ruf: The study concept and design; intellectual participation in the propaedeutic and/or therapeutic conduct of the studied cases.

Ana C. Torre: Data collection, or analysis and interpretation of data.

Sofia V. Duran Daza: Writing of the manuscript or critical review of important intellectual content.

Victoria I. Volonteri: Data collection.

Viviana Flores: Data collection.

Luis D. Mazzuoccuolo: Final approval of the final version of the manuscript.

## Conflicts of interest








None declared.

## Acknowledgement

We thank Dr. Victoria Volonteri for her collaboration with the histological images of the patient.

## References

- Góes LDM, Monteiro VS, Souza ATO. Case for diagnosis. Ulcer and papular lesions in a patient with diabetes mellitus. *Protothecosis. An Bras Dermatol.* 2021;96:613–6.
- Kwong JC, Ward PB, Johnson PD. Cutaneous protothecosis in a patient with hypogammaglobulinemia. *Med Mycol Case Rep.* 2013;2:132–3.
- Zhang QQ, Li L, Zhu LP, Zhao Y, Wang YR, Zhu JH. Cutaneous protothecosis in patient with diabetes mellitus and review of published case reports. *Mycopathologia.* 2012;173:163–71.
- Fong K, Tee SI, Ho MSL, Pan JY. Cutaneous protothecosis in a patient with previously undiagnosed HIV infection. *Austral J Dermatol.* 2014;56:71–3.
- Tseng HC, Chen CB, Ho JC, Cheng YW, Huang HW, Sun PL. Clinicopathological features and course of cutaneous protothecosis. *J Eur Acad Dermatol Venereol.* 2018;32:1575–83.
- Teh JS, Wilke AE, Overstall SM, Teng JC, Chin R, Couper JM, et al. Prototheca wickerhamii breast implant infection after reconstructive surgery: a new level of complexity. *Med Mycol Case Rep.* 2021;34:22–6.
- Silva PCG, Silva SBC, Lima RB, D'Acri AM, Lupi O, Martins CJ. Cutaneous protothecosis - Case report. *An Bras Dermatol.* 2013;88:183–5.
- Rui K. Emergence of fungal-like organisms: prototheca. *Mycopathologia.* 2020;185:747–54.
- Todd JR, Matsumoto T, Ueno R, Murugaiyan J, Britten A, King JW, et al. Medical phycolgy 2017. *Med Mycol.* 2018;56:5188–204.
- Kano R. Emergence of fungal-like organisms: Prototheca. *Mycopathologia.* 2020;185:747–54.

Anama Di Prinzio \*, Marina Ruf , Ana C. Torre , Sofia V. Duran Daza , Victoria I. Volonteri , Viviana Flores , Luis D. Mazzuoccuolo 

Italian Hospital of Buenos Aires, CABA, Argentina

\* Corresponding author.

E-mail: [anama.diprinzio@hospitalitaliano.org.ar](mailto:anama.diprinzio@hospitalitaliano.org.ar) (A. Di Prinzio).

Received 8 September 2022; accepted 7 October 2022  
Available online 27 April 2023

<https://doi.org/10.1016/j.abd.2022.10.008>

0365-0596/ © 2023 Sociedade Brasileira de Dermatologia.

Published by Elsevier España, S.L.U. This is an open access article under the CC BY license (<http://creativecommons.org/licenses/by/4.0/>).

## Secondary syphilis concomitant with primary lesion and early neurosyphilis in a kidney transplant recipient<sup>☆</sup>



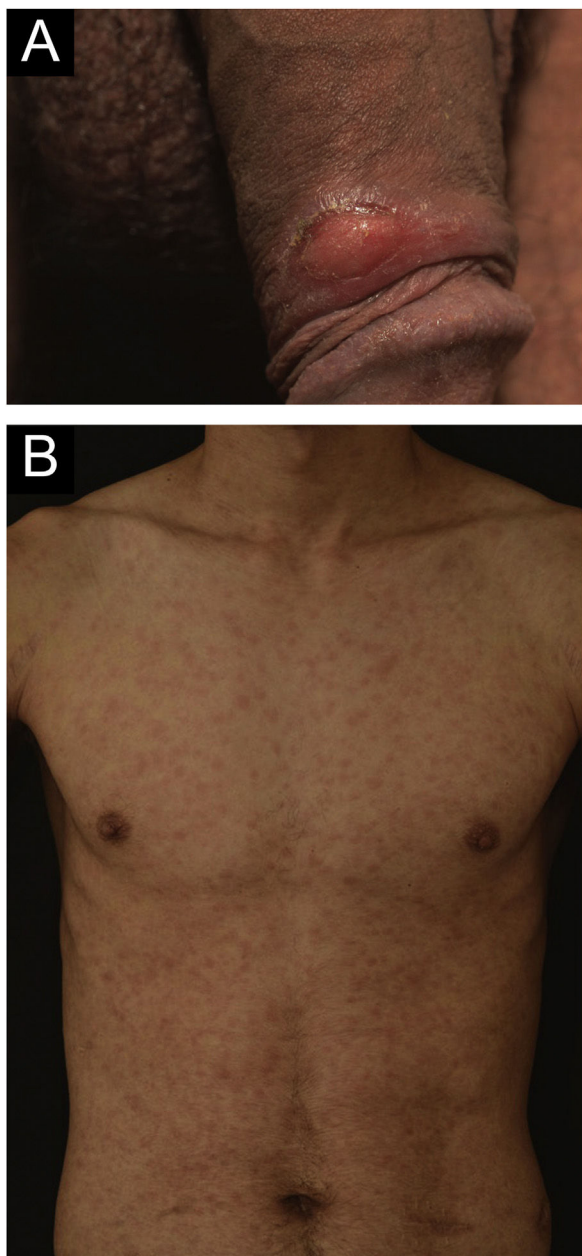
Dear Editor,

*Treponema pallidum*, subspecies *pallidum*, is the causative agent of syphilis. Syphilis can be transmitted through sexual contact, blood transfusion, solid organ transplantation, and from mother to child.<sup>1,2</sup> The rising incidence of syphilis is a global public health problem.<sup>3</sup> Despite the large number

of people undergoing kidney transplantations (KTx), data on syphilis in this population are scarce.<sup>4–9</sup>

A 24-year-old man presented to the emergency room in July 2020 with a painless genital ulcer for the preceding 20 days (Fig. 1A). Subsequently, multiple non-pruritic and painless erythematous papules with peripheral desquamation appeared. These papules had a symmetrical distribution, located on the trunk (Fig. 1B), upper limbs, and palmo-plantar region (Fig. 2A). He also had odynophagia and right peripheral facial palsy (Fig. 2B). He underwent kidney transplantation 18 months prior to the presentation. Immunosuppression included tacrolimus, sodium mycophenolate, and prednisone. He reported being heterosexual and denied sexual intercourse in the 3 months prior to presentation, or any previous episodes of syphilis. The serum treponemal Chemiluminescence Immunoassay (CLIA) test of the recipient before KTx was nonreactive (Table 1), as was

<sup>☆</sup> Study conducted at the Department of Infectious Diseases, Dermatology, Diagnostic Imaging and Radiotherapy, Faculty of Medicine, Universidade Estadual Paulista, Botucatu, SP, Brazil



**Figure 1** (A) Ulcer with well-defined edges, erythematous bed, located in the foreskin. (B) Multiple erythematous papules distributed on the trunk

the serum Venereal Disease Research Laboratory (VDRL) test of the deceased donor.

At presentation, the serological investigation showed VDRL (1:16) and CLIA reactivity (Table 1). Lymphopenia (880 lymphocytes/mm<sup>3</sup>) and mild liver enzyme changes (Alanine aminotransferase, 59 U/L; alkaline phosphatase, 136 U/L; gamma-glutamyl transferase, 174 U/L) were identified. The estimated glomerular filtration rate decreased by 12% from baseline (93 mL/min/1.73 m<sup>2</sup>). Serological tests for HIV 1/2, HTLV I/II, and hepatitis B and C, as well as HIV-1 plasma viral load and RT-PCR for COVID-19, were negative. Brain computed tomography revealed no abnormalities. Cerebrospinal Fluid (CSF) analysis showed slight

lymphocytic pleocytosis, elevated protein levels, and hypoglycorrhachia. CSF VDRL was non-reactive; however, the Fluorescent Treponemal Antibody Absorption Test (FTA-ABS) IgG was reactive (Table 1). The ophthalmologic evaluation revealed papilledema in the right eye. The skin biopsy from the trunk showed a pattern of interface dermatitis associated with perivascular and peri-annexal lymphocytic infiltrate, with rare plasma cells (Fig. 3A). Immunohistochemical analysis of *T. pallidum* was positive (Fig. 3B).

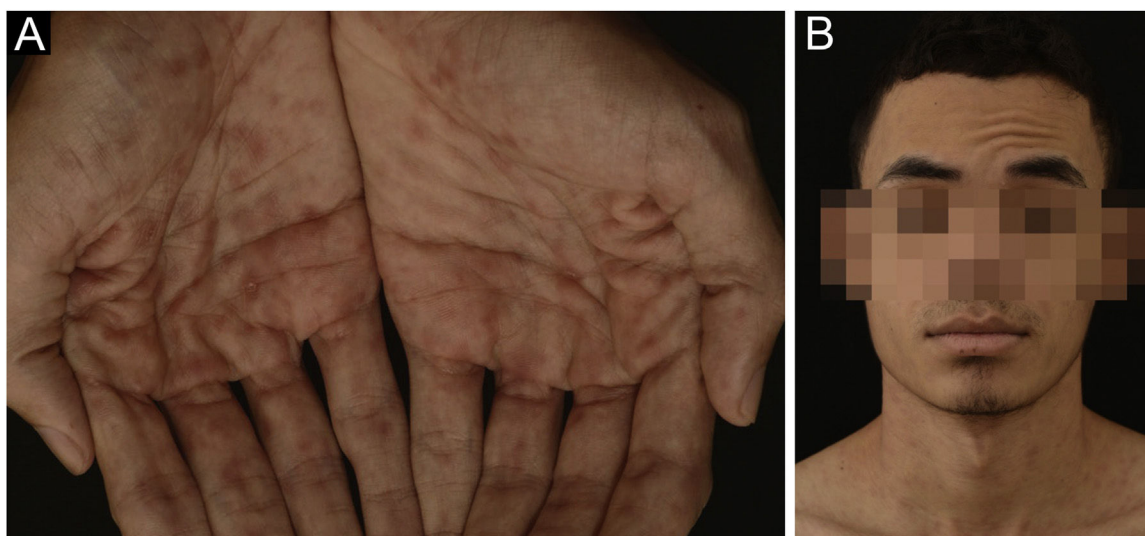
The patient was diagnosed with secondary syphilis concomitant with primary lesion and early neurosyphilis and received intravenous potassium penicillin G (4 million IU every 4 h for 14 days). After the 14-day treatment ended, the penile lesion was healed, and evident improvement was noted in other dermatological lesions and facial paralysis, with normalization of liver enzyme levels and renal function. Thereafter, the immunosuppressive regimen was not modified. One month after the 14-day treatment, the patient was completely asymptomatic. Three months after the treatment, the papilledema was still in regression. At the 15-month follow-up after the 14-day treatment, there was no recurrence of syphilis, and the ophthalmologic examination no longer showed papilledema. Table 1 presents serological responses to syphilis treatment.

The diagnosis was primary-secondary syphilis (early syphilis), even with the patient's report of absence of sexual activity in the last three months, as the patient may have omitted such information, and the clinical picture was typical of lesions in the primary and secondary phases. It could be questioned whether the penile lesion was a manifestation of primary syphilis or secondary syphilis. However, the penile lesion was the first to appear, clinically compatible with primary chancre, and the lesions on the body and palm of the soles, typical of secondary syphilis, seemed only a few days later.

The natural course of sexually acquired syphilis has well-defined phases characterized sequentially by the primary, secondary, latent syphilis, and tertiary stages (up to 40%).<sup>1</sup> However, the clinical presentation is often atypical in immunocompromised populations. In people living with HIV/AIDS, there is concurrence between the primary and secondary phases, rapid evolution to the tertiary stage (secondo-tertiarism), the occurrence of multiple primary lesions, secondary malignant syphilis, early neurological, and ophthalmological involvement, involvement of cranial nerves, in addition to gastric, hepatic, and pulmonary syphilis.<sup>10</sup>

We identified only six reports of acquired syphilis after kidney transplantation, with severe and disseminated cases prevailing.<sup>4-9</sup> This case corroborated the previously described hepatic, neurological, and ophthalmic involvement.<sup>4-9</sup> However, it presented with the following unusual symptoms: simultaneous primary and secondary involvement, peripheral facial palsy, and false-negative VDRL in CSF.

Attention should be paid to these atypical presentations in patients undergoing KTx, as syphilis has been shown to be an even better mimic in immunocompromised patients than in immunocompetent patients.<sup>1</sup>



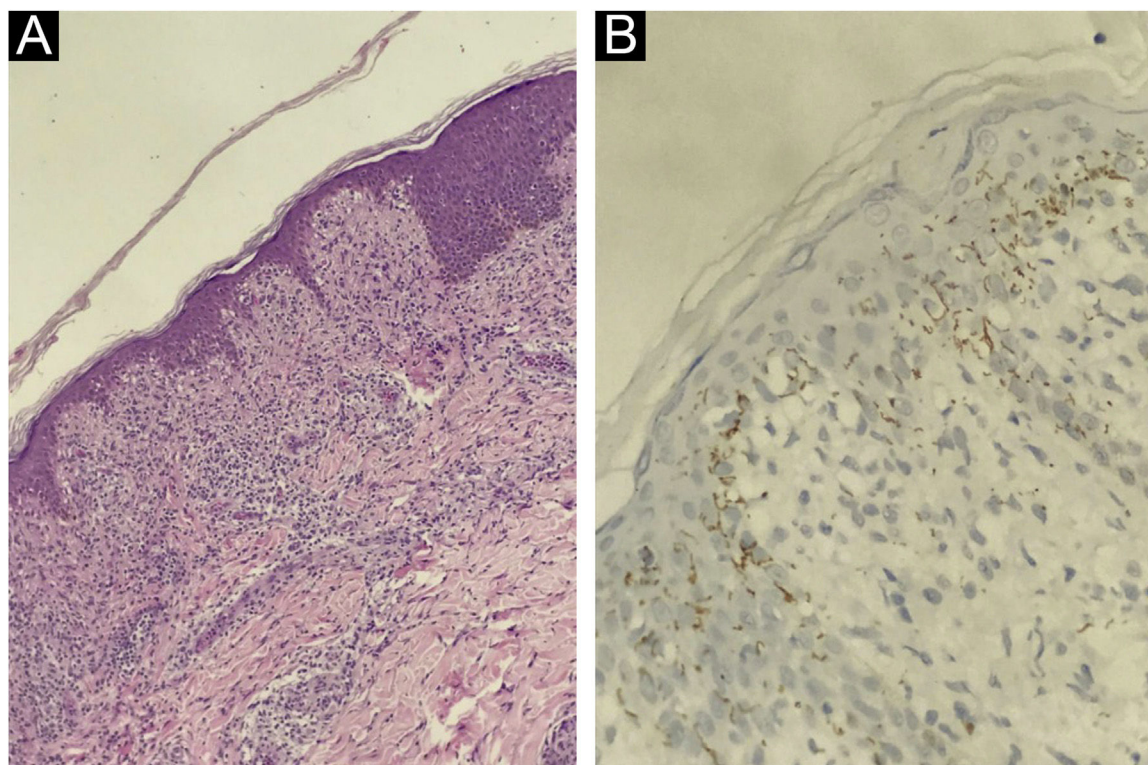
**Figure 2** (A) Multiple erythematous papules distributed on the palms. (B) Peripheral facial nerve palsy

**Table 1** Cerebrospinal fluid and serological data of the kidney transplant recipient

CSF	2-days pre-treatment		13-days of treatment		180-days post-treatment	
Fluid aspect	Clear and colorless		Clear and colorless		Clear and colorless	
WBC (/mm <sup>3</sup> )	8		5		2	
Lymphocytes (%)	60		NA		NA	
Monocytes (%)	1		NA		NA	
Neutrophils (%)	39		NA		NA	
RBC (/mm <sup>3</sup> )	5		15		2	
Protein (mg/dL)	75		66		37	
Glucose (mg/dL)	53		50		54	
CSF/serum glucose ratio	0.47		NA		0.62	
VDRL	Nonreactive		Nonreactive		Nonreactive	
FTA-ABS (IgM)	Nonreactive		NA		NA	
FTA-ABS (IgG)	Reactive		NA		NA	
Others (all negative)	Bacterial/fungal culture; India ink		NA		NA	
	stain; cryptococcal antigen latex agglutination test; adenosine deaminase; RT-PCR: CMV, VZV, HSV-1, HSV-2					
Serum	35 months pre-KTx	2 days pre-treatment	71 days post-treatment	156 days post-treatment	212 days post-treatment	338 days post-treatment
VDRL (Titer)	NA	1:16	1:8	1:2	1:2	1:2
Treponemal CLIA	Nonreactive	Reactive	Reactive	Reactive	Reactive	Reactive

CSF, Cerebrospinal Fluid; WBC, White Blood Cell; RBC, Red Blood Cell; VDRL, Venereal Disease Research Laboratory test; FTA-ABS, Fluorescent Treponemal Antibody Absorption test; IgM, Immunoglobulin M; IgG, Immunoglobulin G; RT-PCR, Real-Time Polymerase Chain Reaction; CMV, Cytomegalovirus; VZV, Varicella-Zoster Virus; HSV, Herpes Simplex Virus; KTx, Kidney Transplantation; CLIA, Chemiluminescent Immunoassay; NA, Not Available.





**Figure 3** (A) Skin biopsy: histological examination by Hematoxylin & eosin,  $\times 400$ , showing nonspecific lymphocytic and histiocytic infiltrate with some plasma cells. (B) Immunohistochemistry,  $\times 400$ , for *Treponema pallidum* in skin biopsy showing the presence of spirochetes

### Financial support

None declared.

### Authors' contributions

Ana Claudia Athanasio Shwetz: Elaboração do texto, participação efetiva na propedêutica, revisão de literatura, revisão crítica e aprovação do manuscrito.

Gabriel Berg de Almeida: Elaboração do texto, participação efetiva na orientação, participação efetiva na propedêutica, revisão de literatura, revisão crítica e aprovação do manuscrito.

Ricardo de Souza Cavalcante: Elaboração do texto, participação efetiva na orientação, participação efetiva na propedêutica, revisão de literatura, revisão crítica e aprovação do manuscrito.

Juliano Vilaverde Schmitt: Elaboração do texto, participação efetiva na orientação, participação efetiva na propedêutica, revisão de literatura, revisão crítica, e aprovação do manuscrito.

Luciana Patrícia Fernandes Abbade: Elaboração do texto, participação efetiva na orientação, participação efetiva na propedêutica, revisão de literatura, revisão crítica e aprovação do manuscrito.

Ricardo Augusto Monteiro de Barros Almeida: Elaboração do texto, participação efetiva na orientação, participação efetiva na propedêutica, revisão de literatura, revisão crítica e aprovação do manuscrito.

### Conflicts of interest

None declared.






### Acknowledgment

We thank photographer Eliete Correia Soares for taking patient photographs.

### References

1. Peeling RW, Mabey D, Kamb ML, Chen XS, Radolf JD, Benzaken AS. Syphilis. *Nat Rev Dis Primers*. 2017;3:17073.
2. Tariciotti L, Das I, Dori L, Perera MT, Bramhall SR. Asymptomatic transmission of *treponema pallidum* (syphilis) through deceased donor liver transplantation. *Transpl Infect Dis*. 2012;14:321–5.
3. who.int [Internet]. World Health Organization. Report on global sexually transmitted infection surveillance 2018. [cited 2022 Jan 25]. Available from: <https://www.who.int/publications/i/item/9789241565691>.
4. Ballout A, Yombi JC, Hassoun Z, Goffin E, Kanaan N. Secondary syphilis after renal transplantation. *NDT Plus*. 2008;1:442–4.
5. Camarero-Temiño V, Mercado-Valdivia V, Izquierdo-Ortiz MJ, Santos-Barajas JJ, Hijazi-Prieto B, Sáez-Calero I, et al. Neurosyphilis in a renal transplant patient. *Nefrologia*. 2013;33:277–9.
6. Johnson PC, Norris SJ, Miller GP, Scott LD, Sell S, Kahan BD, et al. Early syphilitic hepatitis after renal transplantation. *J Infect Dis*. 1988;158:236–8.

7. Romao EA, Bolella VR, Nardin ME, Habib-Simao ML, Furtado JM, Moyses-Neto M. Ocular syphilis in a kidney transplant recipient. *Rev Inst Med Trop Sao Paulo*. 2016;58:46.
8. Taniguchi S, Osato K, Hamada T. The prozone phenomenon in secondary syphilis. *Acta Derm Venereol*. 1995;75:153–4.
9. Marty CL, Snow JL. Secondary syphilis in an immunocompromised kidney transplant recipient. *Cutis*. 2011;88:284–9.
10. Pereira AL, Lozada A, Monteiro AF. Malignant syphilis in a patient with acquired human immunodeficiency virus (HIV) infection. *An Bras Dermatol*. 2022;97:641–3.

Ana Claudia Athanasio Shwetz ,  
Gabriel Berg de Almeida ,  
Ricardo de Souza Cavalcante ,  
Juliano Vilaverde Schmitt,  
Luciana Patricia Fernandes Abbade \*,  
Ricardo Augusto Monteiro de Barros Almeida 

*Department of Infectious Diseases, Dermatology, Diagnostic Imaging and Radiotherapy, Faculty of Medicine, Universidade Estadual Paulista, Botucatu, SP, Brazil*

\* Corresponding author.

E-mail: [fernandes.abbade@unesp.br](mailto:fernandes.abbade@unesp.br) (L.P. Abbade).

Received 14 October 2022; accepted 11 December 2022

Available online 22 May 2023

<https://doi.org/10.1016/j.abd.2022.12.002>

0365-0596/ © 2023 Published by Elsevier España, S.L.U. on behalf of Sociedade Brasileira de Dermatologia. This is an open access article under the CC BY license (<http://creativecommons.org/licenses/by/4.0/>).