



IMAGES IN DERMATOLOGY

Cutis verticis gyrata: a cutaneous finding in acromegaly[☆]

Giullia Menuci Chianca Landenberger ^a, Bárbara Roberta Ongaratti ^b,
Júlia Fernanda Semmelmann Pereira-Lima ^{a,b}, Miriam da Costa Oliveira ^{a,b,*}

^a Neuroendocrinology Center, Complexo Hospitalar Santa Casa de Porto Alegre, Universidade Federal de Ciências da Saúde de Porto Alegre, Porto Alegre, RS, Brazil

^b Postgraduate Program in Pathology, Universidade Federal de Ciências da Saúde de Porto Alegre, Porto Alegre, RS, Brazil

Received 17 February 2021; accepted 30 May 2021

Available online 11 March 2022

KEYWORDS

Acromegaly;
Growth hormone;
Scalp

Abstract Acromegaly is a rare disease characterized by changes in the bone and soft tissue systems, induced by excess growth hormone and insulin-like growth factor type 1. Among the skin lesions associated with acromegaly is cutis verticis gyrata, an hypertrophic, and coarse folding of the skin of the scalp, an association of uncommon incidence and unknown prevalence. This case report describes the case of a patient diagnosed with acromegaly at age 60 with previously unidentified cutis verticis gyrata. This report aims to review the literature on cutis verticis gyrata and its unusual association with acromegaly.

© 2022 Sociedade Brasileira de Dermatologia. Published by Elsevier España, S.L.U. This is an open access article under the CC BY license (<http://creativecommons.org/licenses/by/4.0/>).

Case report

A 60-year-old black male was referred to a tertiary outpatient neuroendocrinology center for suspected acromegaly. He had type 2 diabetes mellitus, diagnosed at age 40, with diabetic neuropathy and retinopathy, and was treated with insulin and metformin. He had systemic arterial hyperten-

sion and dyslipidemia. His shoe size had increased by age 40. He reported a femoral neck fracture at age 53 after a fall, and bone mineral densitometry showed osteoporosis of the lumbar spine. The family history included diabetes mellitus and obesity.

On physical examination, his height was 182 cm, BMI of 26.1 kg/m²; he had prognathism and enlargement of the extremities, increased skin folds and furrows, increased skin sweating, percussion of the median nerves resulted in bilaterally positive Tinel sign, and he had a deep voice. Convolutions of the scalp were observed in the parietal and occipital regions (Fig. 1). The alterations observed on the scalp were also identified in the magnetic resonance imaging of the skull (Figs. 2 and 3). When questioned, the patient

[☆] Study conducted at the Centro de Neuroendocrinologia, Complexo Hospitalar Santa Casa de Porto Alegre, Universidade Federal de Ciências da Saúde de Porto Alegre, Porto Alegre, RS, Brazil.

* Corresponding author:

E-mail: miriamoliveira1697@gmail.com (M.C. Oliveira).

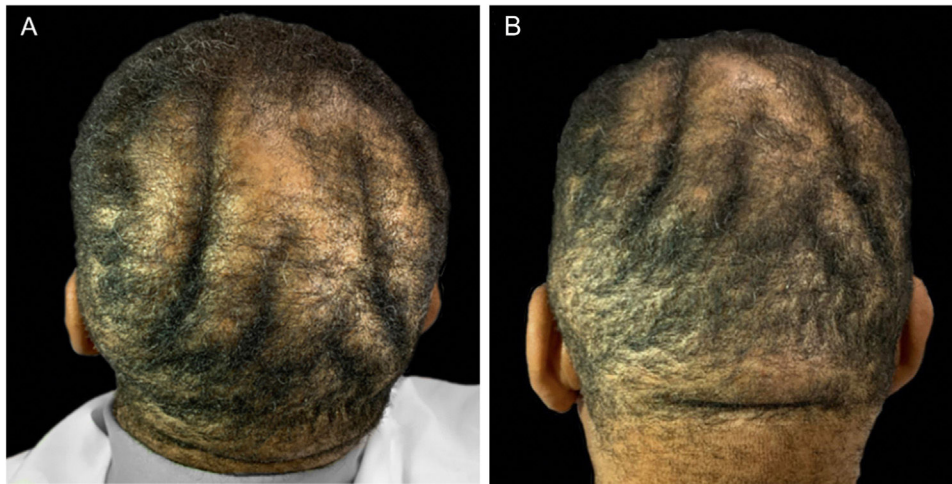


Figure 1 (A and B) Clinical aspect of the scalp.

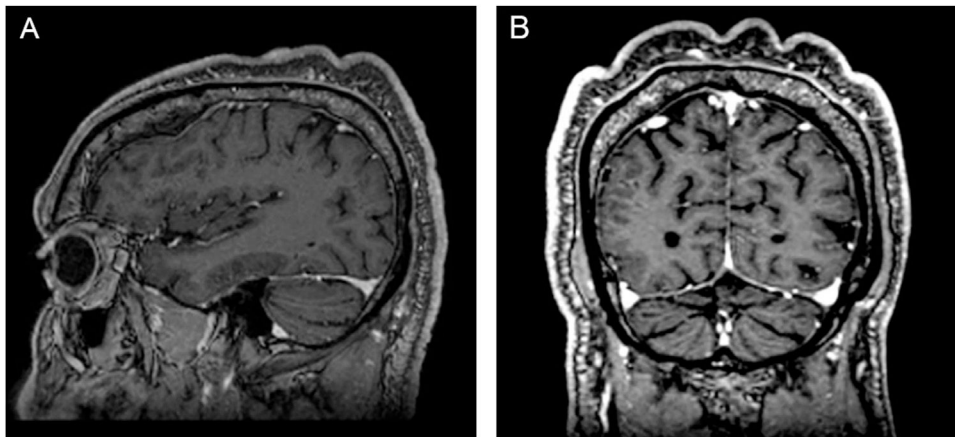


Figure 2 Magnetic resonance imaging of the skull. (A), Sagittal section. (B), Coronal section, showing skin undulations.

reported that his longtime barber reported having difficulty cutting his hair due to irregularities on the scalp.

The diagnosis of acromegaly was confirmed by the insulin-like growth factor 1 (IGF-1) level of 734 ng/mL (reference interval 81–225 ng/mL) and growth hormone (GH) of 21.5 ng/mL (reference range <3 ng/mL). There was no clinical or laboratory evidence of hypopituitarism. Magnetic resonance imaging of the sellar region showed a pituitary lesion to the right, measuring 1.3 × 0.7 cm in the longest axis and involving the right cavernous sinus. The patient underwent transsphenoidal pituitary resection, with pathological confirmation of a pituitary adenoma, reactive on immunohistochemistry for GH, prolactin, and thyroid stimulating hormone (TSH), and positive Ki-67 immunoreactivity in 2% of the neoplastic cells. Due to the residual lesion and persistence of GH/IGF-1 hypersecretion, he started using 30 mg of somatostatin analog (octreotide) per month after biochemical control of the excess hormone.

Discussion

Cutis verticis gyrata (CVG) is the term that describes hypertrophy and coarse folding of the scalp skin, alternating crests

and deep grooves, which mimic a cerebriform aspect, that is, the cerebral gyri. CVG is classified as primary when the etiology is unknown or has a neurological cause. Acromegaly is one of the secondary causes of CVG, as well as local scalp diseases, pachydermoperiostosis, genetic syndromes, systemic diseases, other endocrine diseases, and minoxidil or testosterone use.^{1–3} CVG is a rare condition, with a prevalence of 0.026 to 0.1 in 100,000 individuals, and reports of its association with acromegaly are even more rare.⁴

The number of folds, usually soft and spongy, can vary.¹ Skin folds in primary CVG are usually symmetrical, follow an anteroposterior direction, and usually involve the vertex and occiput, although the entire scalp can be affected. In secondary CVG, the folds are often asymmetrical, not following a longitudinal direction.⁵ The folds are not easily flattened by traction or pressure.^{3,6} The areas of the scalp affected in acromegaly are multiple, ranging from frontal, frontoparietal, and parieto-occipital regions, up to forehead to nape of the neck and, eventually, they affect the glabella and nasal bridge.^{1–3,5–8}

While males are vastly more affected in cases of primary CVG, at a ratio of 5-6:1, this predominance is not well established in secondary cases.⁹

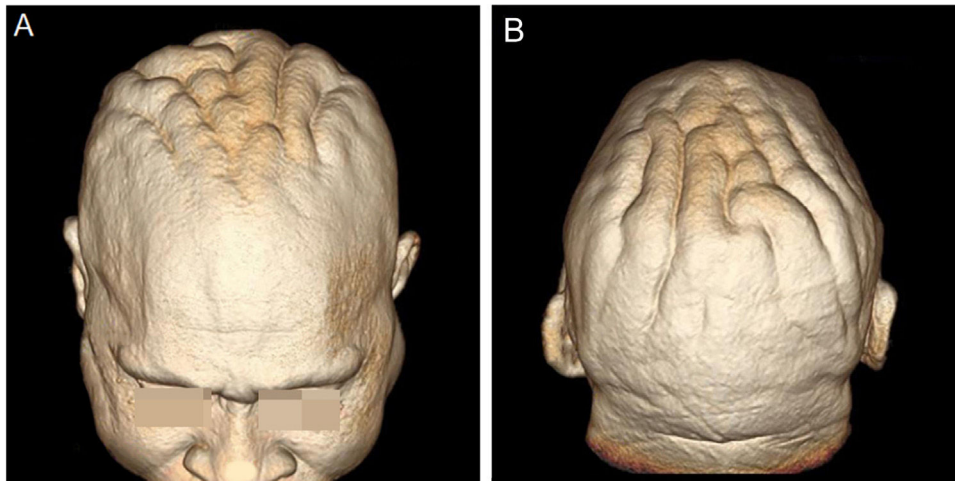


Figure 3 (A and B), Three-dimensional (3D) reconstruction of the cerebriform skin from the magnetic resonance imaging of the cephalic segment.

Schunter et al. proposed that excessive levels of GH and IGF-1 are crucially involved in the pathogenesis of CVG in acromegaly, acting on target skin cells, especially dermal fibroblasts.⁷

The collagen deposition that characterizes CVG is prolonged and progressive, but it is a benign condition, with repercussions limited to esthetics – consequently, with possible emotional damage and eventual skin infections, mainly fungal, due to the difficult hygiene of the furrows. The treatment consists of local hygiene and surgical resection of excess skin in cases of cosmetic discomfort.

The current case does not require specific management for CVG, but draws attention to the possibility of this complication in the context of a rare and chronic disease such as acromegaly.

Financial support

None declared.

Authors' contributions

Giullia Menuci Chianca Landenberger: Approval of the final version of the manuscript; design and planning of the study; drafting and editing of the manuscript; collection, analysis, and interpretation of data.

Bárbara Roberta Ongaratti: Approval of the final version of the manuscript; critical review of the literature; critical review of the manuscript.

Júlia Fernanda Semmelmann Pereira-Lima: Approval of the final version of the manuscript; effective participation in research orientation; intellectual participation in the propaedeutic and/or therapeutic conduct of the studied cases.

Miriam da Costa Oliveira: Approval of the final version of the manuscript; design and planning of the study; critical review of the manuscript.

Conflicts of interest

None declared.

References

1. Tripathi M, Mukherjee KK. Cutis verticis gyrata: an interesting cutaneous finding in acromegaly. *NJDVL*. 2015;13:73–4.
2. Al-Bedaia M, Al-Khenaizan S. Acromegaly presenting as cutis verticis gyrata. *Int J Dermatol*. 2008;47:164.
3. Sriphrapradang C, Chadpraorn N. Bulldog scalp. *Clev Clin J Med*. 2016;83:90–1.
4. Akesson HO. Cutis verticis gyrata and mental deficiency in Sweden. I. Epidemiologic and Clinical Aspects. *Acta Med Scand*. 1964;175:115–27.
5. Harish V, Clarke F. Isolated cutis verticis gyrata of the glabella and nasal bridge: a case report and review of the literature. *J Plast Reconstr Aesthet Surg*. 2013;66:1421–3.
6. Zangeneh F, Carpenter PC. Visual vignette. Cutis verticis gyrata (CVG) in acromegaly. *Endocr Pract*. 2002;8:475.
7. Schunter JA, Metze D, Böhm M. Is IGF-1 a key player in the pathogenesis of acromegaly-associated cutis verticis gyrate? *Exp Dermatol*. 2017;26:85–6.
8. Yerawar C, Bandgar T, Lila A, Shah NS. Acromegaly presenting as cutis verticis gyrata. *QJM*. 2016;109:423.
9. Larsen F, Birchall N. Cutis verticis gyrata: three cases with different aetiologies that demonstrate the classification system. *Australas J Dermatol*. 2007;48:91–4.