

CASE LETTER

A case of multiple perforating pilomatricomas[☆]



Dear Editor,

A 22-year-old man was referred to our department for evaluation of a slightly painful nodule on the arm that had increased in size over the previous four months. He had a history of surgical resection of several nodules on the nape, back, and arm at other dermatology clinics. He complained of myotonic symptoms with difficulty in relaxing his hands after contraction and was followed at the Neurology Department of our hospital under suspicion of myotonic dystrophy, but he refused to undergo genetic testing. Physical examination showed a 10 × 10 mm, slightly elevated, firm reddish nodule with central brownish crusts on the left upper arm (Fig. 1a). The tumor was surgically removed under local anesthesia. Histopathological examination showed a well-circumscribed tumor mass penetrating the dermis. The epidermis was ulcerated, and the lateral acanthotic epidermis extended downwards in a tongue-like projection (Fig. 1b). Tumor cells were composed of different types of cells, such as eosinophilic, basophilic, and transitional cells. Partial elimination of tumor cells through the epidermis was observed (Fig. 1b). There was an inflammatory reaction with mononuclear cells, and a number of foreign-body type giant cells were found around the mass. We retrospectively examined three specimens of previously resected tumors. One of the specimens also showed proliferation of eosinophilic and

basaloid tumor cells in the dermis with central ulceration of the epidermis (Fig. 1c), whereas the other two tumors were pilomatricoma without perforation.

Perforating pilomatricoma is a rare variant of pilomatricoma, which clinically presents with inflammatory papules, cutaneous horn-like nodules, craters, and ulcers resembling keratoacanthoma or solid masses.^{1–4} Most of the reported cases are solitary lesions, and one case has been reported in which perforating pilomatricoma was observed in one of the multiple pilomatricomas;² however, to our knowledge, only one case of multiple onset of perforating pilomatricomas has been reported.³ In that case, the patient presented Churg-Strauss syndrome and Rubinstein-Taybi syndrome and developed a total of 15 tumors. Although the exact number was not specified, multiple lesions were classified as perforating pilomatricomas.³ Our patient was suspected of myotonic dystrophy, which, however, was not genetically confirmed. Myotonic dystrophy is an autosomal dominant inherited disease caused by a mutation in the dystrophia myotonica protein kinase gene on chromosome 19. The occurrence of multiple pilomatricomas has been reported to be associated with myotonic dystrophy.⁵ Our patient developed multiple firm nodules on the nape, back, and upper arm. The total number of the nodules was five, four of which were subjected to histopathological examination. All of the four nodules were diagnosed as pilomatricomas. Of interest, two of the nodules were perforating pilomatricomas, showing perforation and partial elimination of the eosinophilic tumor cells. Recent studies have shown that

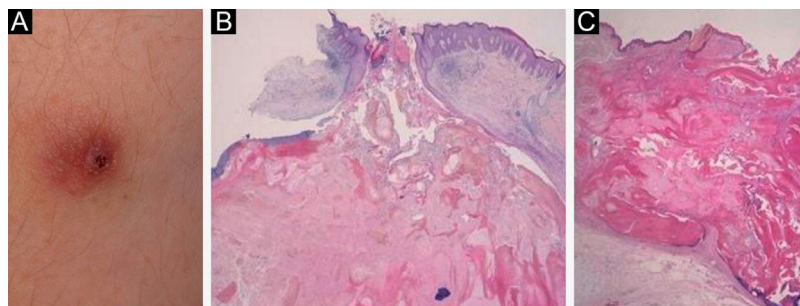


Figure 1 (A), A reddish firm nodule with central crusts on the upper arm. (B), A perforated pilomatricoma lesion with elimination of pilomatricoma cells (Hematoxylin & eosin stain; ×40). (C), Histopathology of another nodule, showing central ulceration and an eosinophilic tumor mass with peripheral basaloid tumor cells (Hematoxylin & eosin stain; ×40).

[☆] Study conducted at the Department of Dermatology, School of Medicine, Fukushima Medical University, Fukushima, Japan.

matrix metalloproteinase-9 and -12 derived from tumor cells, fibroblasts, and macrophages may be relevant to the partial elimination of the tumor, by degradation of collagen and elastic fibers.⁴ When superficially located, the elimination of pilomatricoma is accelerated by virtue of epidermal catharsis mechanisms.

Financial support

None declared.

Authors' contributions

Mai Endo: Designed the study; performed the research and contributed to analysis and interpretation of data; wrote the initial draft of the manuscript; read and approved the final version of the manuscript.



Toshiyuki Yamamoto: Designed the study; performed the research and contributed to analysis and interpretation of data; assisted in the preparation of the manuscript; read and approved the final version of the manuscript.

Conflicts of interest

None declared.

References

1. Miura T, Yamamoto T. Perforating pilomatricoma with anetodermic epidermis in an adolescent with lymphoma. *Pediatr Dermatol.* 2013;30:68–9.
2. Alli N, Güngör E, Artüz F. Perforating pilomatricoma. *J Am Acad Dermatol.* 1996;35:116–8.
3. Bayle P, Bazex J, Lamant L, Lauque D, Durieu C, Albes B. Multiple perforating and non-perforating pilomatricomas in a patient with Churg-Strauss syndrome and Rubinstein-Taybi syndrome. *J Eur Acad Dermatol Venereol.* 2004;18:607–10.
4. Richet C, Maza A, Dreyfus I, Bourrat E, Mazereeuw-Hautier J. Childhood pilomatricomas: Associated anomalies. *Pediatr Dermatol.* 2018;35:548–51.
5. Watabe D, Mori S, Akasaka T, Motegi SI, Ishiwaka O, Amano. Six cases of perforating pilomatricoma: Anetodermic changes with expression of matrix metalloproteinases. *J Dermatol.* 2020;47:82–5.

Mai Endo *, Toshiyuki Yamamoto 

Department of Dermatology, Fukushima Medical University, Fukushima, Japan

*Corresponding author.

E-mail: enmai04@fmu.ac.jp (M. Endo).

Received 7 July 2020; accepted 21 September 2020
available online 10 February 2022

<https://doi.org/10.1016/j.abd.2020.09.015>

0365-0596/ © 2021 Sociedade Brasileira de Dermatologia.

Published by Elsevier España, S.L.U. This is an open access article under the CC BY license (<http://creativecommons.org/licenses/by/4.0/>).

Acyclovir-resistant chronic mucocutaneous herpes with good response to the association with imiquimod in an AIDS patient: case report*



Dear Editor,

Genital ulcers are often caused by herpes simplex virus (HSV), with type 2 being most frequently implicated.¹ When immunodeficiency is present, the herpetic infection can progress with atypical presentations and greater refractoriness to antiviral treatment.²

In patients who are co-infected with human immunodeficiency virus (HIV), deeper ulcerations, hypertrophic lesions, and, in some cases, lesions with pseudotumor characteristics may be seen.¹

This case report describes a patient with acquired immunodeficiency with anogenital lesions, initially resistant to treatment with systemic acyclovir, who showed significant improvement after its association with the topical use of 5% imiquimod cream.

A case of a 38-year-old female patient with acquired human immunodeficiency syndrome (AIDS) diagnosed approximately five years ago, but who showed loss of adherence to antiretroviral treatment (ART) for a few months during 2017, restarting treatment in December of that same year is presented. Among the laboratory alterations, she had a CD4 T-cell count of 4 cells/ μ L. She reported the presence of ulcerated anogenital lesions for approximately one year. She had been medicated at another service with oral acyclovir for four months, without any improvement.

At the time of the examination, she had extensive, intensely painful, ulcerated lesions with crusts in the vulva and perianal region (Fig. 1a). Intravenous acyclovir was the drug of choice, at a dose of 10 mg/kg/dose 3 times a day, associated with 5% imiquimod cream (3 times/week), with excellent tolerability. She showed a good therapeutic response three weeks after beginning the proposed treatment (Fig. 1b), but it could not be concluded as the patient died due to complications from the underlying disease. The histopathological examination was carried out at the beginning of the clinical picture in order to document the case, showing the typical findings of HSV infection (Fig. 2).

It is believed that unusual clinical presentations due to HSV infections in AIDS patients could be explained as a reflection of the slow evolution of the disease and not nec-

* Study conducted at the Hospital Federal Bonsucesso, Rio de Janeiro, RJ, Brazil.