

Case for diagnosis. Primary cutaneous CD4+ small/medium T-cell lymphoproliferative disorder*

Flávia de Oliveira Valentim¹, Cristiano Claudino Oliveira^{2,3}, Hélio Amante Miot¹

DOI: <http://dx.doi.org/10.1590/abd1806-4841.20198513>

CASE REPORT

The patient was a 36-year-old female, Caucasian, school-teacher, who reported a single purplish erythematous nodule with a firm consistency and shiny surface, with telangiectasias, clear contour, non-pruritic, located on the left nasal ala, approximately 1.5 cm in diameter, which had grown progressively for 45 days (Figure 1). No lymphadenopathy, visceromegaly, or other associated signs were identified. Histopathological examination showed atypical and diffuse lymphocytic infiltrate in the dermis, reaching the subcutaneous layer and involving the perivascular tissue. Lymphocytes

were small to intermediate in size (Figure 2). Immunohistochemistry revealed a predominance of CD3+ T lymphocytes, with CD4+ immunopositivity (Figure 3). The cell proliferation index (Ki-67) was estimated at 10-15%, and there were rare CD30+ cells. Populations of plasma cells, histiocytes, and CD8+ T lymphocytes were observed in the background. Further tests such as CT scan, biochemical tests, blood count, lactate dehydrogenase, and β 2-microglobulin levels were normal.

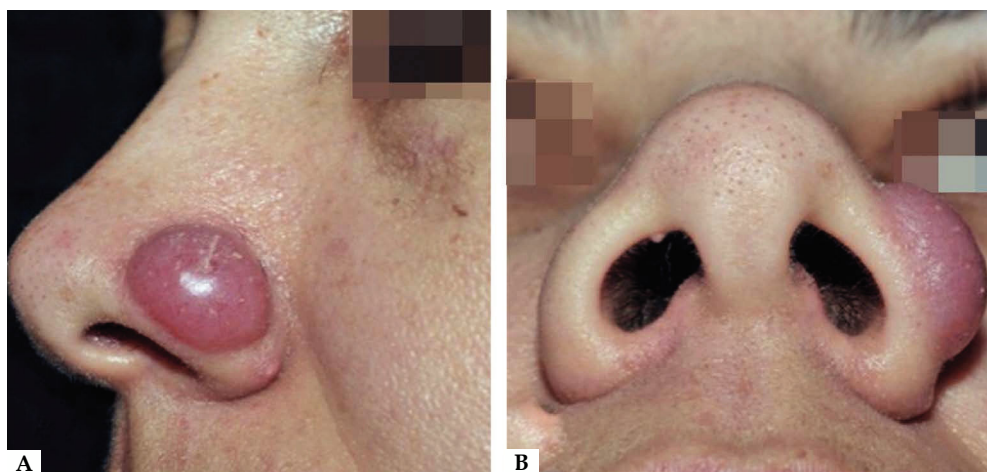


FIGURE 1: Purplish erythematous nodule with firm shiny surface on the left nasal ala. **A** - lateral view. **B** - Lower view

Received 05 June 2018.

Accepted 19 August 2018.

* Work conducted at the Departments of Dermatology and Pathology, Faculdade de Medicina de Botucatu, Universidade Estadual Paulista, Botucatu (SP), Brazil.

Financial support: None.

Conflict of interest: None.

¹ Department of Dermatology, Faculdade de Medicina de Botucatu, Universidade Estadual Paulista, Botucatu (SP), Brazil.

² Department of Pathology, Faculdade de Medicina de Botucatu, Universidade Estadual Paulista, Botucatu (SP), Brazil.

³ Department of Pathological Anatomy, Hospital São Luiz/D'Or, São Paulo (SP), Brazil.

MAILING ADDRESS:

Flavia de Oliveira Valentim

E-mail: fdeoliveiravalentim@gmail.com

©2019 by Anais Brasileiros de Dermatologia



DISCUSSION

Primary cutaneous CD4+ small/medium T-cell lymphoproliferative disorder, previously called CD4+ small/medium pleomorphic T cell lymphoma, is a rare disease with indolent and insidious evolution, classically presenting as a solitary nodule on the face, neck, or trunk.¹ Cases have been described in patients with some degree of immune compromise such as transplanted patients and those in use of immunobiologicals.^{2,3}

Despite the benign and favorable course of this disease, both the diagnosis and therapeutic approach remain challenging for dermatologists and pathologists.⁴ In 2017, the World Health Organization reviewed the classification of lymphomas and reclassified this primary cutaneous lymphoma (2005) as a lymphoproliferative disease (2017) (Chart 1).^{5,6}

The distinction between cutaneous T-cell lymphoproliferative disorder and its differential diagnoses is extremely important, modifying the prognosis and treatment approach, particularly in relation to primary cutaneous CD8+ epidermotropic cytotoxic T-cell lymphoma, which has an aggressive clinical course and presents with morphological necrosis and ulceration. Other differential diagnoses include: mycosis fungoides and subtypes, which can be

CHART 1: Classification of primary cutaneous T and NK cell lymphoproliferative disorders	
Mycosis fungoides	
Sézary syndrome	
Primary cutaneous CD30+ T-cell lymphoproliferative disorders	
Lymphomatoid papulosis	
Primary cutaneous anaplastic large cell lymphoma	
Peripheral primary cutaneous T-cell lymphoma and lymphoproliferative disorders, rare cases	
Primary cutaneous gamma/delta T-cell lymphoma	
Primary cutaneous CD+ aggressive epidermotropic cytotoxic T-cell lymphoma	
Primary cutaneous acral CD8+ T-cell lymphoma*	
Primary cutaneous CD+ small/medium sized T-cell lymphoproliferative disorder*	
Subcutaneous panniculitis-like T-cell lymphoma	
Extranodal NK/T-cell lymphoma, nasal type	

* Changes from 2008 classification
Source: Swerdlow SH, et al, 2017.⁵

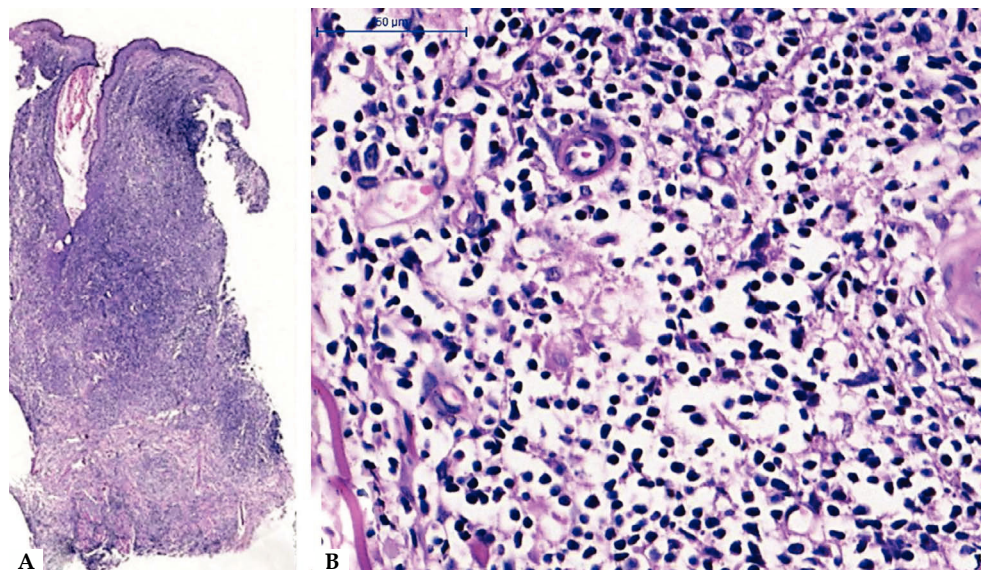


FIGURE 2: A - Histological skin section of dense lymphocytic infiltrate in the dermis (Hematoxylin & eosin, x50). B - Histological skin section demonstrating the nuclear pattern of the lymphocytes in the lesion: small to medium-sized nuclei, predominantly regular karyotheca, hyperchromasia and perivascular and periadnexal arrangement, with no foci of epidermotropism (Hematoxylin & eosin, x400)

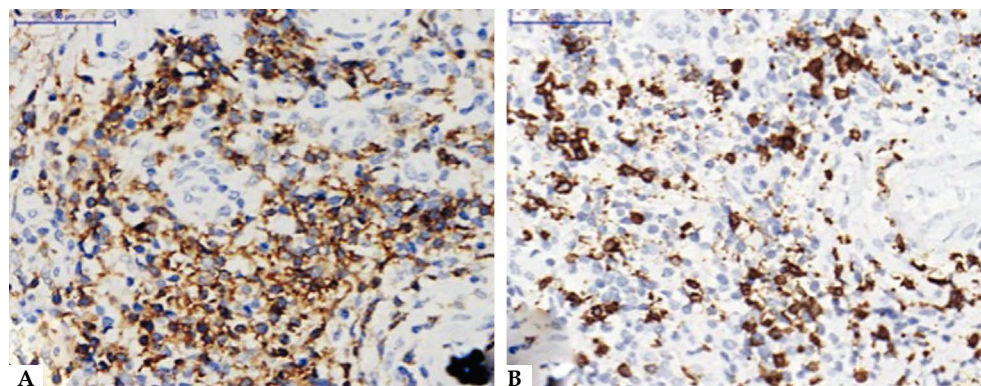


FIGURE 3: A - Area with perivascular dermal lymphocytic infiltrate (Immunohistochemistry, CD4, x400). Prevalence of CD4 T lymphocytes. B - Area with perivascular dermal lymphocytic infiltrate. CD4 T lymphocytes predominate over CD8 T lymphocytes (Immunohistochemistry, CD8, x400)

distinguished from each other based on clinical history and rapid evolution; primary cutaneous acral CD8+ T-cell lymphoma, which may overlap in its topography and clinical presentation but with a different immunophenotype and better prognosis; and primary cutaneous gamma/delta T-cell lymphoma, with highly aggressive clinical and morphological features.^{1,4,7}

Markers of poor evolution and worse prognosis in cutaneous T-cell lymphoproliferative disorders include: disseminated lesions, rapid growth, and presence of more than 30% of large pleomorphic CD30+ T lymphocytes and/or high rates of cell proliferation, similar to that observed in high-grade lymphomas.^{1,7}

The medical literature includes case reports showing efficient treatments, such as oral doxycycline, corticosteroids (topical, intralesional, and/or oral), surgical excision, and radiotherapy. However, there is no consensus on the best therapeutic approach for these cases.^{1,5,7-10}

The proposed treatment for this patient was occlusive fluocinolone (in patches), leading to the complete remission of the lesion within 60 days and no relapse in 90 days of follow-up. Potent corticosteroids have a lympholytic effect, promoting rapid involution of the infiltrate in localized forms, with low cost and high tolerability. □

Abstract: Primary cutaneous CD4+ small/medium T-cell lymphoproliferative disorder is a rare disease, with an indolent evolution and benign course. The classic presentation is a solitary nodule on the face or trunk. The disorder's rarity and clinical and histopathological characteristics, can make the diagnosis difficult. We present the case of a 36-year-old Caucasian woman with a purplish erythematous nodule, hardened, shiny, asymptomatic, on the left nasal ala, which had grown progressively for 45 days. Histopathological examination and immunohistochemistry panel demonstrated alterations consistent with primary cutaneous CD4+ small/medium T-cell lymphoproliferative disorder. There was complete remission of the condition within 60 days of treatment with potent occlusive corticosteroids.

Keywords: Lymphoma; Lymphoproliferative disorders; Pseudolymphoma


REFERENCES

- James E, Sokhn JG, Gibson JF, Carlson K, Subtil A, Girardi M, et al. CD4 + primary cutaneous small/medium-sized pleomorphic T-cell lymphoma: a retrospective case series and review of literature. *Leuk Lymphoma*. 2015;56:951-7.
- Shakerian B, Razavi N, Mandegar MH. Primary Cutaneous CD4-Positive Small/Medium-Sized Pleomorphic T-Cell Lymphoma Following Heart Transplantation. *Int J Organ Transplant Med*. 2017;8:168-9.
- Ma H, Qiu S, Lu R, Feng P, Lu C. Methotrexate and etanercept-induced primary cutaneous CD4 positive small/medium-sized pleomorphic T-cell lymphoma. *An Bras Dermatol*. 2016;91:368-71.
- Alberti-Violetti S, Torres-Cabala CA, Talpur R, Corti L, Fanoni D, Venegoni L, et al. Clinicopathological and molecular study of primary cutaneous CD4+ small/medium-sized pleomorphic T-cell lymphoma. *J Cutan Pathol*. 2016;43:1121-30.
- Swerdlow SH, Campo E, Harris NL, Jaffe ES, Pileri SA, Stein H, et al. WHO Classification of tumors of Haematopoietic and Lymphoid Tissues. 4th Ed. Vol 2. IARC: Lyon; 2017.
- Swerdlow SH, Campo E, Pileri SA, Harris NL, Stein H, Siebert R, et al. The 2016 revision of the World Health Organization classification of lymphoid neoplasms. *Blood*. 2016;127:2375-90.
- Baum CL, Link BK, Neppalli VT, Swick BL, Liu V. Reappraisal of the provisional entity primary cutaneous CD4+ small/medium pleomorphic T-cell lymphoma: a series of 10 adult and pediatric patients and review of the literature. *J Am Acad Dermatol*. 2011;65:739-48.
- Toberer F, Hartschuh W, Hadaschik E. Primary cutaneous CD4+ small- to medium-sized pleomorphic T-cell lymphoma: temporary remission by oral doxycycline. *JAMA Dermatol*. 2013;149:956-9.
- Keeling BH, Gavino ACP, Admirand J, Soldano AC. Primary cutaneous CD4-positive small/medium-sized pleomorphic T-cell lymphoproliferative disorder: Report of a case and review of the literature. *J Cutan Pathol*. 2017;44:944-7.
- Maurelli M, Colato C, Gisondi P, Girolomoni G. Primary Cutaneous CD4(+) Small/Medium Pleomorphic T-Cell Lymphoproliferative Disorder: A Case Series. *J Cutan Med Surg*. 2017;21:502-6.


AUTHORS' CONTRIBUTIONS

Flávia de Oliveira Valentim  ORCID 0000-0002-1600-3519

Elaboration and writing of the manuscript

Cristiano Claudino Oliveira  ORCID 0000-0001-6682-5230

Conception and planning of the study; Elaboration and writing of the manuscript; Obtaining, analyzing and interpreting the data; Critical review of the literature; Critical review of the manuscript

Hélio Amante Miot  ORCID 0000-0002-2596-9294

Approval of the final version for publication; Conception and planning of the study; Elaboration and writing of the manuscript; Obtaining, analyzing and interpreting the data; Effective participation in research orientation; Intellectual participation in propaedeutic and/or therapeutic management of cases

How to cite this article: Valentim FO, Oliveira CC, Miot HA. Case for diagnosis. Primary cutaneous CD4+ small/medium T-cell lymphoproliferative disorder. *An Bras Dermatol*. 2019;94(1):99-101.