

## Authors' contributions

Li-wen Zhang: Conception and planning of the study; obtaining, analysis, and interpretation of the data; critical review of the literature.

Wen-Ju Wang: Concepção e planejamento do estudo.

Cong-Hui Li: Critical review of the literature.

Tao Chen: Critical review of the manuscript.





## Conflicts of interest

None declared.

## References

1. Degos R, Delort J, Civatte J, Poiars Baptista A. Epidermal tumor with an unusual appearance: clear cell acanthoma. *Ann Dermatol Syphiligr (Paris)*. 1962;89:361–71.
2. Zedek DC, Langel DJ, White WL. Clear-cell acanthoma versus acanthosis: a psoriasiform reaction pattern lacking tricholemmal differentiation. *Am J Dermatopathol*. 2007;29:378–84.
3. Lyons G, Chamberlain AJ, Kelly JW. Dermoscopic features of clear cell acanthoma: five new cases and a review of existing published cases. *Australas J Dermatol*. 2015;56:206–11.

4. Miyake T, Minagawa A, Koga H, Fukuzawa M, Okuyama R. Histopathological correlation to the dermoscopic feature of "string of pearls" in clear cell acanthoma. *Eur J Dermatol*. 2014;24:498–9.
5. Espinosa AED, Akay BN, Gonzalez-Ramirez RA. String of pearls pattern": report of three cases of non clear-cell acanthoma. *An Bras Dermatol*. 2017;92 Suppl. 1:142–4.

Li-Wen Zhang \*,<sup>1</sup>, Wen-Ju Wang <sup>1</sup>, Cong-Hui Li , Tao Chen 

Department of Dermatovenereology, Chengdu Second People's Hospital, Chengdu, Sichuan, China

\*Corresponding author.

E-mail: zhleven@126.com (L. Zhang).

<sup>1</sup> Contributed equally to this work.

Received 30 March 2019; accepted 14 June 2019

Available online 20 March 2020

<https://doi.org/10.1016/j.abd.2019.06.015>

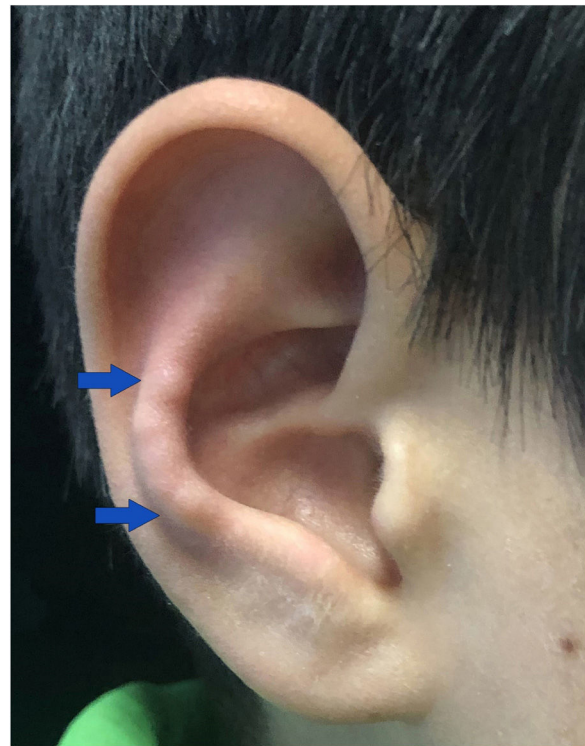0365-0596/ © 2020 Published by Elsevier España, S.L.U. on behalf of Sociedade Brasileira de Dermatologia. This is an open access article under the CC BY-NC-ND license (<http://creativecommons.org/licenses/by-nc-nd/4.0/>).

## Pediatric chondrodermatitis nodularis chronica heliis

Dear Editor,

A 9-year-old Chinese boy presented with a 2-month-history of multiple nodules affecting the right antihelix. The nodules gradually increased and were mildly painful. He was otherwise healthy. No local factors and prior skin lesions, including the history of injury to the site, were found. There was no significant medical or family history. Physical examination found four skin-colored nodules 4–5 mm on the right antihelix with a pearl necklace arrangement (Fig. 1). One of the nodules was excised and histopathologic features are shown in fig. 2. It showed irregular epidermal hyperplasia, dermal vascular endothelial cell swelling and vascular stenosis with moderate perivascular lymphocytic infiltration, and laminated fibrosis with granulomatous infiltration of epithelioid cells and lymphocytes. Blood tests including complete blood count, blood clotting index, liver and renal function, and anti-nuclear antibodies were all normal. We diagnosed this patient as having Chondrodermatitis Nodularis Chronica Heliis (CNCH) and started treatment with protective padding placed around the external ear and topical 0.5% halometasone cream. Two months later, the nodules were smaller and the pain disappeared.

CNCH is characterized by a benign painful erythematous nodule with a central crust, fixed to the cartilage of the helix or antihelix of the external ear. The right-sided lesions are more common than left-sided ones. CNCH most commonly



**Figure 1** Four skin-colored nodules on the right antihelix with a pearl necklace arrangement.

☆ How to cite this article: Zhang L-W, Li L, Li C-H, Wang W-J. Pediatric chondrodermatitis nodularis chronica heliis. *An Bras Dermatol*. 2020;95:391–3.

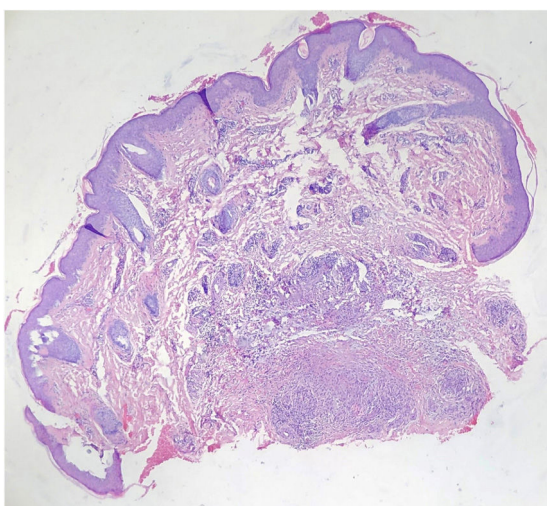
☆☆ Study conducted at the Department of Dermatovenereology, Chengdu Second People's Hospital, Chengdu, Sichuan, China.

**Table 1** Reported cases of pediatric CNCH in the literature.

| N° | Report                | Age/Sex | Associated conditions    | Treatment    |
|----|-----------------------|---------|--------------------------|--------------|
| 1  | Sasaki T 1999[2]      | 8/F     | Dermatomyositis          | Excision     |
| 2  | Rogers NE 2003[3]     | 16/F    | None                     | Excision     |
| 3  | Magro CM 2005[4]      | 15/M    | Lupus erythematosus      | Not reported |
| 4  | Magro CM 2005[4]      | 15/M    | Rheumatoid finger nodule | Not reported |
| 5  | Grigoryants V 2007[5] | 10/M    | None                     | Excision     |

occurs on the helix of the external ear in men and on the antihelix in women.<sup>1</sup> It is an uncommon disorder of middle-aged and elderly individuals between 40 and 80 years, with male to female ratio of 10 to 1. Typically, CNCH presents unilaterally; however, bilateral lesions have been reported with an incidence of 3–7%.<sup>1</sup> Although CNCH can occur in any age group, it has rarely been reported in children. As far as we know, our patient is the sixth pediatric case of CNCH reported by literatures (Table 1).<sup>2–5</sup> Three of these pediatric cases with CNCH reported in literature had associated connective tissue disorders. Then, some authors recommend that patients with CNCH in their fourth decade or younger should be routinely evaluated for underlying autoimmune conditions.<sup>4</sup>

The etiology of CNCH is unclear. The most likely cause of CNCH is ischemia or microtrauma related to sleeping on one side. Some possible contributory factors, including cartilage degeneration, ear anatomy, genetics, glomus-like vascular changes, perforating dermatoses and transepidermal elimination, pressure, autoimmune or connective tissue disorders, and trauma, may induce the onset and development of CNCH.<sup>1</sup> The characteristic histopathologic features of CNCH are epidermal ulceration or a wedge-shaped epidermal defect, epithelial hyperplasia, collagen degeneration, focal fibrinoid necrosis, and inflammatory components. Cartilage may be altered, but it may frequently be normal.



**Figure 2** Histology showing irregular epidermal hyperplasia, dermal vascular endothelial cell swelling and vascular stenosis with moderate perivascular lymphocytic infiltration, and laminated fibrosis with granulomatous infiltration of epithelioid cells and lymphocytes (Hematoxylin & eosin, ×40).

The differential diagnosis of CNCH includes elastic nodule of the ear, rheumatoid nodule, calcinosis cutis, gout tophi, and glomus tumor. Elastic nodule of ear, which occurs on the anterior crus of the antihelix and produces pain simulating CNCH, occurs in a setting of chronic actinic damage. Rheumatoid nodule occurs almost exclusively in association with rheumatoid arthritis. Calcinosis cutis, the deposition of calcium in the skin and subcutaneous tissues, is classified into calciphylaxis and dystrophic, metastatic, idiopathic, and iatrogenic groups. Although the classic location of gouty tophi is the great toe, gouty tophi of the ear also is common. Glomus tumor, a rare painful vascular tumor, usually presents a solitary nodule in the distal portion of a finger, but can also occur everywhere. Generally, a biopsy is necessary to confirm the diagnosis and the histopathologic features of CNCH are characteristic.

Many treatments of CNCH are emerging; however, recurrence is common. Treatments can be classified into two categories. Firstly, nonsurgical procedures include carbon dioxide laser, injectable collagen implants, intralesional steroid injections, nitroglycerin gel, photodynamic therapy, removal of causative factor and relieving pressure, and topical steroids. In addition, some surgical procedures, including cartilage excision, curettage, and wedge excision, have been applied to CNCH. The first-line therapy is to relieve pressure from the site while sleeping through donut pillow or a homemade pressure-relieving device. The gold standard of therapy is surgical excision via wedge resection, despite recurrence if the defective cartilage is not removed.<sup>1</sup> Our patient was in the early stages of CNCH without the characterized central crust in the nodule. His symptoms quickly resolved due to the early accurate diagnosis and treatment.

### Financial support

None declared.

### Authors' contributions

Li-Wen Zhang: Approval of the final version of the manuscript; elaboration and writing of the manuscript; obtaining, analysis, and interpretation of the data; intellectual participation in the propaedeutic and/or therapeutic conduct of the studied cases; critical review of the literature.

Lin Li: Critical review of the literature.

Cong-Hui Li: Effective participation in research orientation; critical review of the manuscript.





Wen-Ju Wang: Approval of the final version of the manuscript; conception and planning of the study; effective participation in research orientation.

## Conflicts of interest

None declared.

## References

1. Salah H, Urso B, Khachemoune A. Review of the etiopathogenesis and management options of chondrodermatitis nodularis chronica helioides. *Cureus*. 2018;10:e2367.
2. Sasaki T, Nishizawa H, Sugita Y. Chondrodermatitis nodularis helioides in childhood dermatomyositis. *Br J Dermatol*. 1999;141:363–5.
3. Rogers NE, Farris PK, Wang AR. Juvenile chondrodermatitis nodularis helioides: a case report and literature review. *Pediatr Dermatol*. 2003;20:488–90.
4. Magro CM, Frambach GE, Crowson AN. Chondrodermatitis nodularis helioides as a marker of internal disease [corrected] associated with microvascular injury. *J Cutan Pathol*. 2005;32:329–33.
5. Grigoryants V, Qureshi H, Patterson JW, Lin KY. Pediatric chondrodermatitis nodularis helioides. *J Craniofac Surg*. 2007;18:228–31.

Li-Wen Zhang \*,<sup>1</sup>, Lin Li <sup>1</sup>, Cong-Hui Li ,  
Wen-Ju Wang 

Department of Dermatovenereology, Chengdu Second People's Hospital, Chengdu, Sichuan, China

\* Corresponding author.

E-mail: zhleven@126.com (L. Zhang).

<sup>1</sup> Contributed equally to this work.

Received 27 March 2019; accepted 20 June 2019

Available online 19 March 2020

<https://doi.org/10.1016/j.abd.2019.06.014>

0365-0596/ © 2020 Sociedade Brasileira de Dermatologia.

Published by Elsevier España, S.L.U. This is an open access article under the CC BY license (<http://creativecommons.org/licenses/by/4.0/>).

## Cutaneous and pulmonary cryptococcosis<sup>☆,☆☆</sup>



Dear Editor,

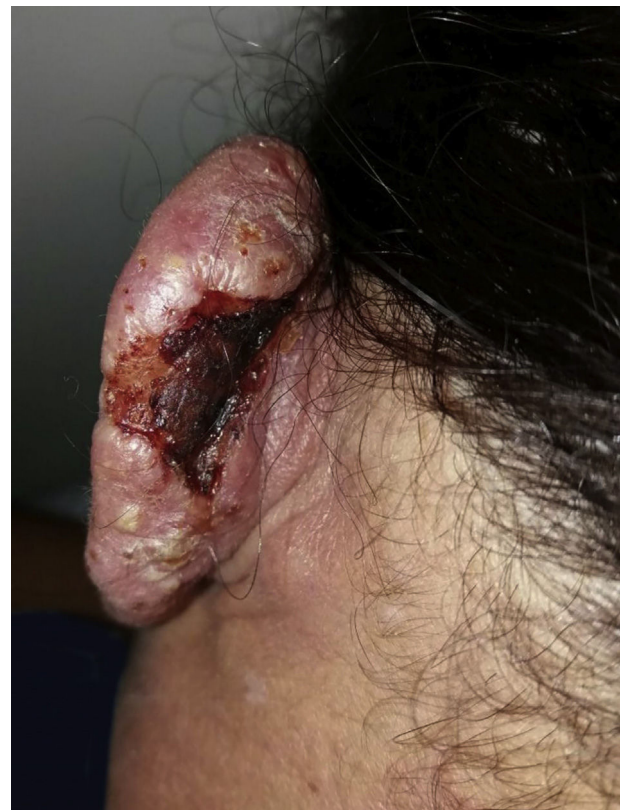*Cryptococcus neoformans* is the etiological agent of cryptococcosis, an infectious disease that affects humans, domestic and wild animals. This pathogen is often found in pigeon excreta, possessing innumerable environmental sources.<sup>1</sup>

The diagnosis can be performed by analysis of cerebrospinal fluid (CSF), urine sediment, bronchoalveolar lavage fluid, wound exudates, floating node aspirate and suspected lesions biopsies.<sup>2</sup>

Treatment of cryptococcosis in immunocompetent and immunocompromised humans, consists of amphotericin B in combination with 5-flucytosin in disseminated infections; or with fluconazole or itraconazole, as an alternative for the treatment of cutaneous infections.<sup>3</sup>

A 36-year-old female patient presented an ulcerated plaque with hematic crust and erythematous infiltrated edges topped with pustules, measuring approximately 3 cm length in the posterior region of the left ear (Fig. 1). The patient related the lesion appeared 4 months before the appointment, accompanied by systemic symptoms such as intermittent fever, productive cough, and weight loss of approximately 5 kg in 15 days. Chest X-ray showed evidence of hypotransparency in the middle segment of the right lung lobe. Patient was insulin-dependent diabetic and had

a history of kidney transplant performed three years ago and in use of azathioprine and prednisone. After dermatological evaluation, it was decided to perform lesional skin scrapings and mycological culture of the lesion's secretion



**Figure 1** Cutaneous lesion in the posterior region of the left ear.

<sup>☆</sup> How to cite this article: Markman DL, Oliveira PPB, Takano DM, Cambuiim IIFM. Cutaneous and pulmonary cryptococcosis. *An Bras Dermatol*. 2020;95:394–6.

<sup>☆☆</sup> Study conducted at the Department of Dermatology of Hospital Otávio de Freitas, Recife, PE, Brazil.