

CORRESPONDENCE

Beware of reflectance confocal microscopy artifacts when searching hyphae in acral skin^{☆,☆☆}



Dear Editor,

We read with interest the article from Veasey et al.¹ that reported a case of tinea nigra of the palm where reflectance confocal microscopy (RCM) was used to confirm the clinical diagnosis. Tinea nigra is a pigmented cutaneous superficial mycosis mainly caused by *Hortaea werneckii*. The typical clinical manifestation of this fungus is a single, brown to black asymptomatic macule with an irregular border mainly localized on palms or soles because infection is believed to occur as a result of inoculation from a contamination source such as soil, sewage, wood, or compost subsequent to trauma in the affected areas. Albeit being usually larger and lighter in color, these lesions tend to resemble acral nevi or melanoma, thus leading many clinicians to perform unnecessary biopsies.

RCM is an emerging non-invasive imaging technique that can show hyphae as thin linear and hyper-reflective structures in the stratum corneum in cutaneous superficial mycosis,^{2,3} including tinea nigra^{1,4} and allows to confirm the clinical diagnosis and to avoid conventional mycological examinations and skin biopsies¹ (Fig. 1). However, hyphae should be differentiated from the contours of normal keratinocytes that can form thin lines and from artifacts. Curiously, stellate hyper-reflective bodies are often visible in acral skin on RCM, possibly corresponding to keratinocytes membranes in a plane not parallel to the microscope tip.⁵ Fig. 2 shows normal acral skin of a healthy person where these artifacts are well visible and are identical to the images presented by Veasey et al.¹ as hyphae of tinea nigra. The authors stated that hyphae identified by RCM in tinea nigra were tortuous, irregular, and short, different from the morphology of the thin and elongated hyphae of the dermatophytes. However, in our experience and in the other case of tinea nigra reported in the literature,

hyphae of *H. werneckii* are elongated and thin on RCM. Moreover, it is also possible to observe that they are septate. The case of Veasey et al.¹ highlights the difficulty of identifying and describing for the first time what is not known with the new imaging techniques and suggests caution when making the first descriptions in the medical field.

In conclusion, RCM can help to identify hyphae of tinea nigra as for other superficial cutaneous mycosis, but the presence of possible artifacts that may mimic fungal structures in acral skin should be considered for this mycosis that mainly affects palms and soles.

Financial support

None declared.

Authors' contribution

Elisa Cinotti: Approval of the final version of the manuscript; study design and planning; data collection; preparation

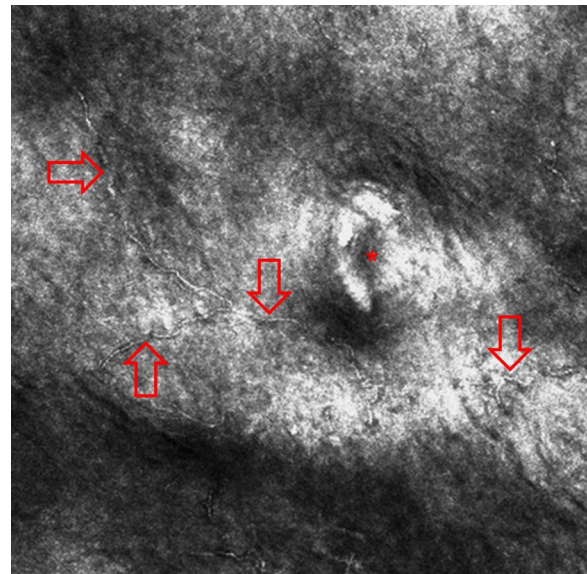


Figure 1 Reflectance confocal microscopy image of a case of tinea nigra reveals thin linear and hyper-reflective structures in upper part of the epidermis (red arrows; the asterisk indicates an acrosyringium).

[☆] How to cite this article: Cinotti E, Perrot JL, Rubegni P. Beware of reflectance confocal microscopy artifacts when searching hyphae in acral skin. An Bras Dermatol. 2020;95:129–30.

^{☆☆} Study conducted at the Department of Medical, Surgical and Neurological Science, Dermatology Section, University of Siena, S. Maria alle Scotte Hospital, Siena, Italy.

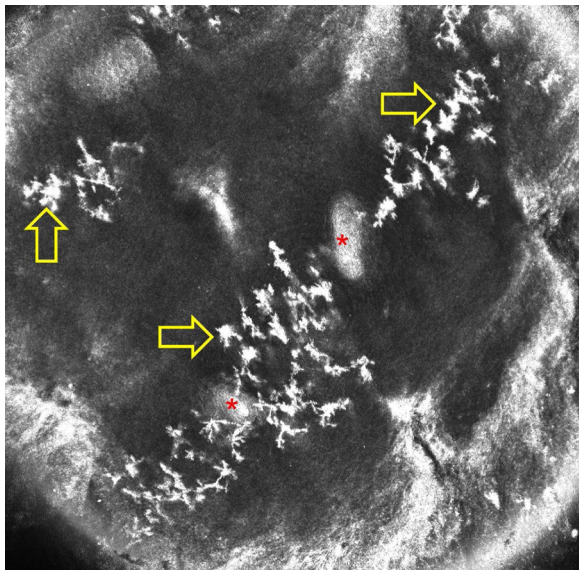


Figure 2 Reflectance confocal microscopy image of normal acral skin of a healthy person shows artifacts presenting as stellate hyper-reflective bodies in the epidermis (yellow arrows; asterisks indicate acrosyringia).

and writing of the manuscript; critical revision of the manuscript.

Jean Luc Perrot: Approval of the final version of the manuscript; study design and planning; data collection, analysis and interpretation; effective participation in research orientation; intellectual participation in propaedeutic and/or therapeutic conduct of studied cases; critical literature review; critical revision of the manuscript.

Pietro Rubegni: Approval of the final version of the manuscript; effective participation in research orientation; intellectual participation in propaedeutic and/or therapeutic conduct of studied cases; critical revision of the manuscript.

Conflicts of interest

None declared.

References

1. Veasey JV, Avila RBde, Ferreira MAMdeO, Lazzarini R. Reflectance confocal microscopy of tinea nigra: comparing images with dermoscopy and mycological examination results. *An Bras Dermatol*. 2017;92:568–9.
2. Cinotti E, Perrot JL, Labeille B, Cambazard F. Reflectance confocal microscopy for cutaneous infections and infestations. *J Eur Acad Dermatol Venereol*. 2016;30:754–63.
3. Cinotti E, Labeille B, Cambazard F, Perrot JL. Reflectance confocal microscopy in infectious diseases. *G Ital Dermatol E Venereol*. 2015;150:575–83.
4. Uva L, Leal-Filipe P, Soares-de-Almeida L, Ferreira J, Oliveira A. Reflectance confocal microscopy for the diagnosis of tinea nigra. *Clin Exp Dermatol*. 2018;43:332–4.
5. Cinotti E, Perrot JL. Topographic and skin phototype variations of skin with special emphasis on facial and acral skin. In: Gonzalez S, editor. *Reflectance confocal microscopy of cutaneous tumors*. India: CRC Press; 2017. p. 120.

Elisa Cinotti ^{a,*}, Jean Luc Perrot ^b, Pietro Rubegni ^a

^a Department of Medical, Surgical and Neurological Science, Dermatology Section, University of Siena, S. Maria alle Scotte Hospital, Siena, Italy

^b Department of Dermatology, University Hospital of Saint-Etienne, Saint-Etienne, France

* Corresponding author.

E-mail: elisacinotti@gmail.com (E. Cinotti).

Received 28 January 2019; accepted 24 April 2019

<https://doi.org/10.1016/j.abd.2019.04.013>

0365-0596/ © 2019 Sociedade Brasileira de Dermatologia.

Published by Elsevier España, S.L.U. This is an open access article under the CC BY license (<http://creativecommons.org/licenses/by/4.0/>).

Beware of reflectance confocal microscopy artifacts when searching hyphae in acral skin – Reply^{☆☆}

Dear Editor,

I would like to thank Cinotti et al. for their interest in our paper about tinea nigra's findings at confocal microscopy, as well as the opportunity offered by the editors of this journal



to answer the points raised by the authors in the article “Beware of reflectance confocal microscopy artifacts when searching hyphae in acral skin”.

The etiological agent of tinea nigra, *Hortaea werneckii*, is a dematiaceous geophilic fungus. The dermoscopic features of this disease consist of a fibrillar hyperchromic pattern, and the direct mycological examination (DME) presents short and thick dematiaceous hyphae, corresponding to the described dermoscopic findings.^{1,2} Other cases seen in our service with fungal culture isolating *H. werneckii* are compatible with these findings (Fig. 1).

Such facts had led us to believe that the images identified by reflectance confocal microscopy (RCM) in our article would be compatible with the hyphae of *H. werneckii* parasitizing the epidermis. It is noteworthy that the morphology of short thick structures presented at dermoscopic examination and DME were compatible with those evidenced by the RCM.³

[☆] How to cite this article: Veasey JV. Beware of reflectance confocal microscopy artifacts when searching hyphae in acral skin – Reply. *An Bras Dermatol*. 2020;95:130–2.

^{☆☆} Study conducted at the Dermatology Clinic, Hospital da Santa Casa de Misericórdia de São Paulo, São Paulo, SP, Brazil.